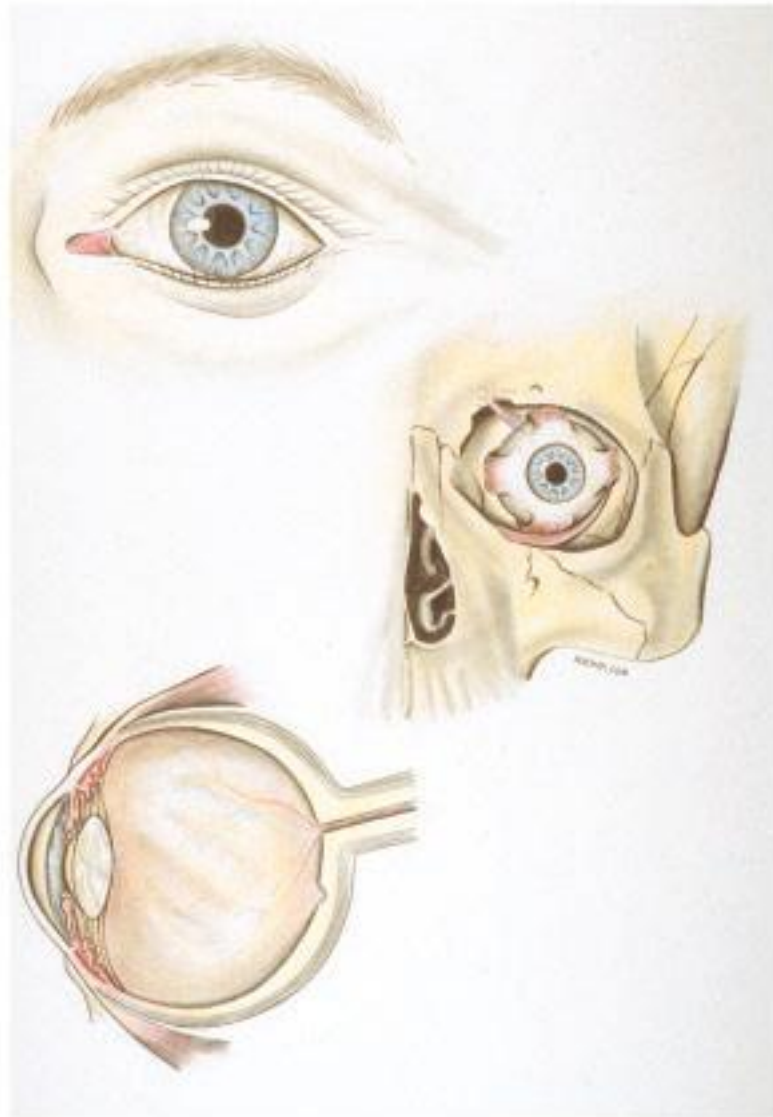


Introduction to Eye Banking: A Handbook and Atlas

A Guide to Eye Bank Techniques,
Corneal Evaluation and Grading



George O.D. Rosenwasser, MD, CEBT &
William J. Nicholson, MD

Introduction to Eye Banking: A Handbook and Atlas

A Guide to Eye Bank Techniques,
Corneal Evaluation and Grading

Copyright 2003, George O.D. Rosenwasser, MD, CEBT, and William J. Nicholson, MD

Foreword

Dean Vavra, M.S., C.E.B.T.

Medical literature tells that as far back as the ancient Greeks, physicians noted that much blindness was attributed to corneas having turned opaque. No longer the clear window of the eye, light could not pass through and subsequently fall onto the nervous tissue of the retina. Replacement of the cornea was recommended but technically not possible for Old World physicians treating their blind patients. In the mid-nineteenth century, Von Hippel speculated that a cornea could be successfully sewn into a person's eye. In England a pig's "donated" cornea was selected for a small girl with a scarred cornea. The operation was not a success, but a quantum leap in ophthalmic surgical philosophy was established. Zirm performed the first human to human cornea transplant in 1906. Other surgeons followed. Filatov, from Odessa, Russia, introduced the world to cadaveric cornea transplants, using eyes that had been removed from the recently deceased in 1935.

The donation through transplantation process was simple in those early days and involved only one staff member. A likely scenario would unfold as follows:

A patient with corneal disease presented to the ophthalmologist for evaluation. The surgeon determines that a full thickness penetrating graft would be efficacious. The patient is counseled that their availability around the clock is needed in order to have this transplant surgery, which, may occur at any hour of the day or night.

Meanwhile, a patient in the same hospital dies from a non-contagious disease at about ten o'clock AM. The ophthalmologist is notified of the death and discusses the benefits of eye donation with family members. The next-of-kin gives consent for donation. The ophthalmic surgeon takes special instruments into the hospital morgue and removes the decedent's eyes placing them in sterile jars with a small amount of normal saline solution. Transplant surgery must occur within twenty-four hours. Sooner is better.

The intended recipient receives a phone call at two A.M. "Eat or drink nothing more tonight, pack a bag sufficient for a two week hospital stay. Your cornea transplant will occur at noon today," the tired ophthalmologist tells the patient. At mid-day the patient is anesthetized and prepped for surgery. The surgeon enters the operating theater carrying a jar that had been stored in the lab refrigerator since midnight. The recently donated whole eye is wrapped in gauze and a special knife is used to cut off the cornea from the globe placing it in a petri dish. With a fresh knife, the patient's cornea is removed and the fresh "button" is sewn onto the patient's eye.

The procedure is performed with the assistance of magnifying loupes placed over the surgeon's eyes. The cornea is anchored in place with somewhat large, "ropey" appearing silk sutures. After surgery the patient is kept in a supine position, flat on his back, for days. Heavy sandbags assure that the corneal recipient does not move the head from side to side, potentially opening up the wound. Due to the evolving techniques employed, the patient does not obtain useful vision in that eye for weeks.

Currently, forty-four thousand cornea transplants occur each year in the United States. Fine nylon sutures are used instead of the heavy silk ties used in the early days. Precision surgical microscopes replace loupes. Corneas are preserved in nutrient media relaxing the time constraints that previously existed. Corneal transplant surgery is an out-patient procedure yielding good visual acuity in a few days.

Specialized organizations called eye banks have been formed and support the transplanting surgeon by recovering and processing corneas because few corneal surgeon have the time or energy to harvest cadaveric eyes at midnight and still see patients during the day.

The first Eye bank was founded in 1944 by Dr. R. Townley Paton in New York City. Others followed and the Eye Bank Association of America was established in 1961 as a progression of the American Academy of Ophthalmology's Committee on Eye Banking. In the 1970's Medical Standards for practice were established by the EBAA leading to the safest group of transplants being performed in medicine.

While the Eye Bank Association of America has striven to create medical standards to ensure safe practice, great latitude for development of policies and procedures are given to individual eye banks.

Slit lamp evaluations of both patients and corneal tissue is a subjective art rooted in scientific principles of optics, refraction and visual perspective. Many veteran eye bankers would agree that teaching new staff the art and science of slit lamp evaluations is one of the more difficult task associated with developing staff. Concepts are challenging to learn and rating systems are subjective. Some eye banks rate tissue quality with a 1, 2 3 or 4 rating. Others use nomenclature; mild or few, moderate or heavy. Agreeing on terms for rating is difficult throughout this discipline.

Eye banking, like any other field has slang, too. We call psuedo guttatae "snail tracks" and fluid retention in Descemet's membrane "folds." Eye bankers in training frequently have difficulty identifying unique pathology, mastering descriptive terms and applying a rating for that pathology that is identified.

Senior author George O.D. Rosenwasser, M.D. had the vision of creating Introduction to Eye Banking; A Handbook and Atlas for eye bank staff to use by taking the donation process from recovery through slit lamp evaluation. Dr Rosenwasser shares his system for evaluation and grading tissue in the appendices.

The illustrations contained in this book depict anatomy relevant to eye bank practice and are purposefully not drawn to the detail found in many ophthalmology text books. William J. Nicholson, M.D. studied many slit lamp photo-micrographs of typical conditions found in banked

corneas. Dr. Nicholson used his experience as a medical illustrator to create drawings of corneal pathology relevant to eye banking. The areas of concern presented in the accompanying micrographs are exemplified through pen and ink interpretations by Dr. Nicholson.

Of course, there is no substitute for peering into the slit lamp and seeking feedback on what is seen. Students will find the evaluation system suggested by Dr. Rosenwasser and the drawings created by Dr. Nicholson to be a valuable tool in learning eye bank tissue evaluation. Eye Bank Association of America Procedures Manual sections are reproduced in the text for reference as how to recover tissue and perform slit lamp evaluations, as well.

Additionally, Introduction to Eye Banking; A Handbook and Atlas contains a glossary of terms common to eye banking. Definitions may not always agree with those found in standard medical dictionaries. The glossary is by no means comprehensive but does help to provide working definitions to terms unique to our discipline.

Introduction to Eye Banking; A Handbook and Atlas is by no means a stand alone work intended to answer all of the questions one may have about eye banking. The Eye Bank Association Medical Standards, Procedures Manual, Food and Drug Administration Rules and local eye bank policies and procedures contain much more specific information on eye bank practice. Technicians still need many long hours working with a preceptor, guidance from Medical Directors and other supervised training in order to master their craft. Introduction to Eye Banking; A Handbook and Atlas is a marvelous tool to aid in that process.

Ron Blanchett, CEBT

Wing Chu, MD

Edmund Jacobs, CEBT

Marian Macsai, MD

Patricia Aiken-O'Neil, Esq

Dean Vavra, MS, CEBT

*Support provided by an unrestricted
educational grant from Allergan, Inc.*

Acknowledgements

The authors wish to thank the following individuals and organizations for their contributions to this publication:

Eduardo Alfonso	University of Miami, Bascom Palmer Eye Institute
Antonio V Cubillas	University of Miami, Bascom Palmer Eye Institute
Denise Cunningham	George Washington University, Center for Sight
Timothy J Bennett	Penn State University, Department of Ophthalmology
William M Bourne	Mayo Clinic, Department of Ophthalmology
Mark Larson	Lions Eye Bank of Wisconsin
Mark J Mannis	University of California, Davis, Department of Ophthalmology
Leif Nelson	Mayo Clinic, Department of Ophthalmology
Robin Schock	The Lions Eye Bank of Central Pennsylvania
Maryanne Taylor	The Florida Lions Eye Bank
Dean Vavra	Rocky Mountain Lions Eye Bank
Jason K Woody	The Central Florida Lions Eye and Tissue Bank, Inc.
JP Wayenborgh	JP Wayenborgh Publications, Ostende, Belgium

The Central Florida Lions Eye and Tissue Bank, Inc.
The Eye Bank Association of America
The Florida Lions Eye Bank
The Lions Eye Bank of Central Pennsylvania
Rocky Mountain Lions Eye Bank

Introduction

Dean Vavra, M.S., C.E.B.T.

The sciences of eye banking and corneal transplantation have made tremendous advances over the past several decades. Changes in preservation methods, surgical techniques and serological testing have necessitated frequent review and reeducation. Throughout these changes, standardization of terminology and techniques has been difficult. This atlas will help those involved with eye banking and corneal transplantation understand and utilize a standardized nomenclature for describing changes in preserved ocular tissue. The atlas also provides information on instruments and techniques used in eye banking.

Dedication

*To my parents who helped me to be what I am,
To Miriam, Lara, Eli and David who are the light of my life,
To my students, who continue to teach me and show me the fruits of my efforts.*

*George O.D. Rosenwasser, MD, CEBT
Hershey, PA*

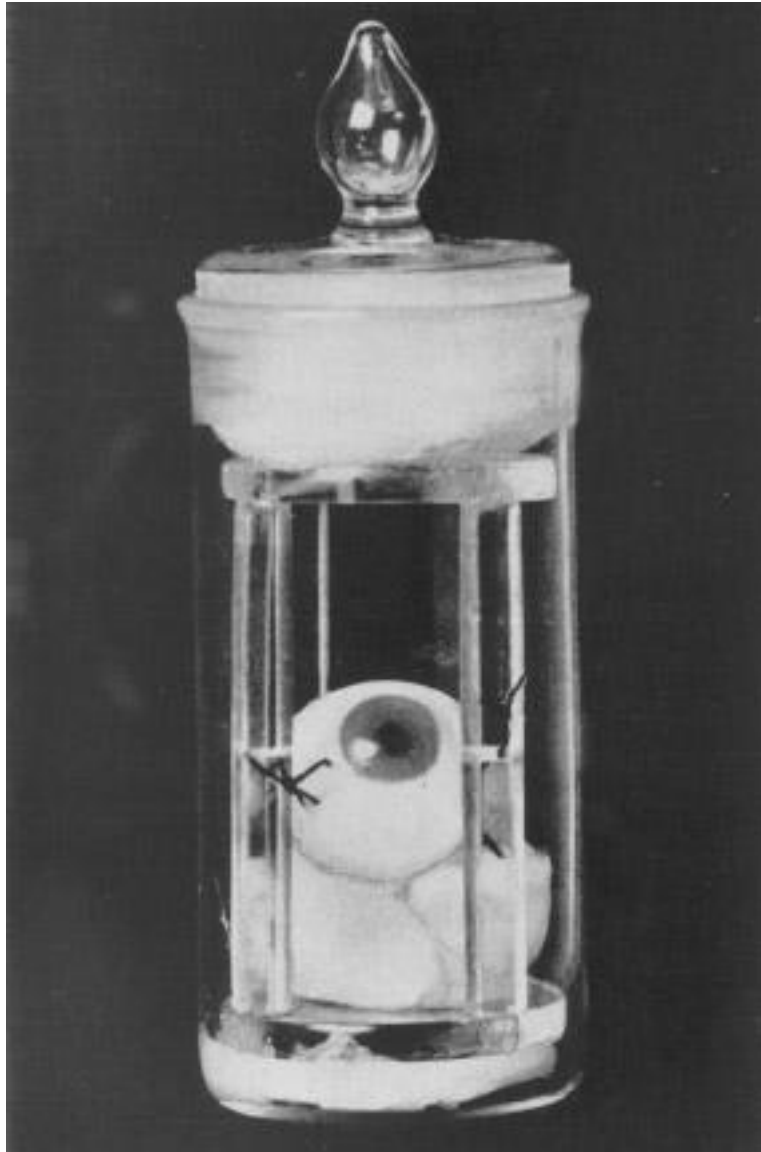
To Jay and Carol, for inspiring by example with endless support and motivation.

William J Nicholson, MD

Table of Contents

<i>Anatomy</i>	11
<i>Surgical Processing Techniques In Eye Banking</i>	17
Instrumentation	19
<i>Donor Maintenance</i>	25
<i>Enucleation</i>	31
<i>Laboratory Whole Exam</i>	41
<i>Corneal Excision</i>	47
<i>In-Situ Excision</i>	57
<i>Introduction to Slit Lamp Technique</i>	65
<i>How To Grade Donor Corneas</i>	69
Evaluation of the Donor Cornea	71
Conjunctiva	72
Sclera and Surgical Incisions.....	72
Epithelium	72
Stroma	72
Descemetis Membrane and Endothelium	77
<i>Media</i>	79
Media Evaluation.....	81
<i>Specular Microscopy</i>	83
Specular Microscopy Basics	85
Specular Microscopy of Fuch’s Endothelial Dystrophy	90
Specular Microscopy by Slit Lamp	91
Specular Microscopy with Eye Bank Specular Microscopes	91
Fixed Frame Analysis.....	92
Variable Frame Analysis.....	93
Normal Cell Morphology.....	93
Polymegathism	94
Pleomorphism	94

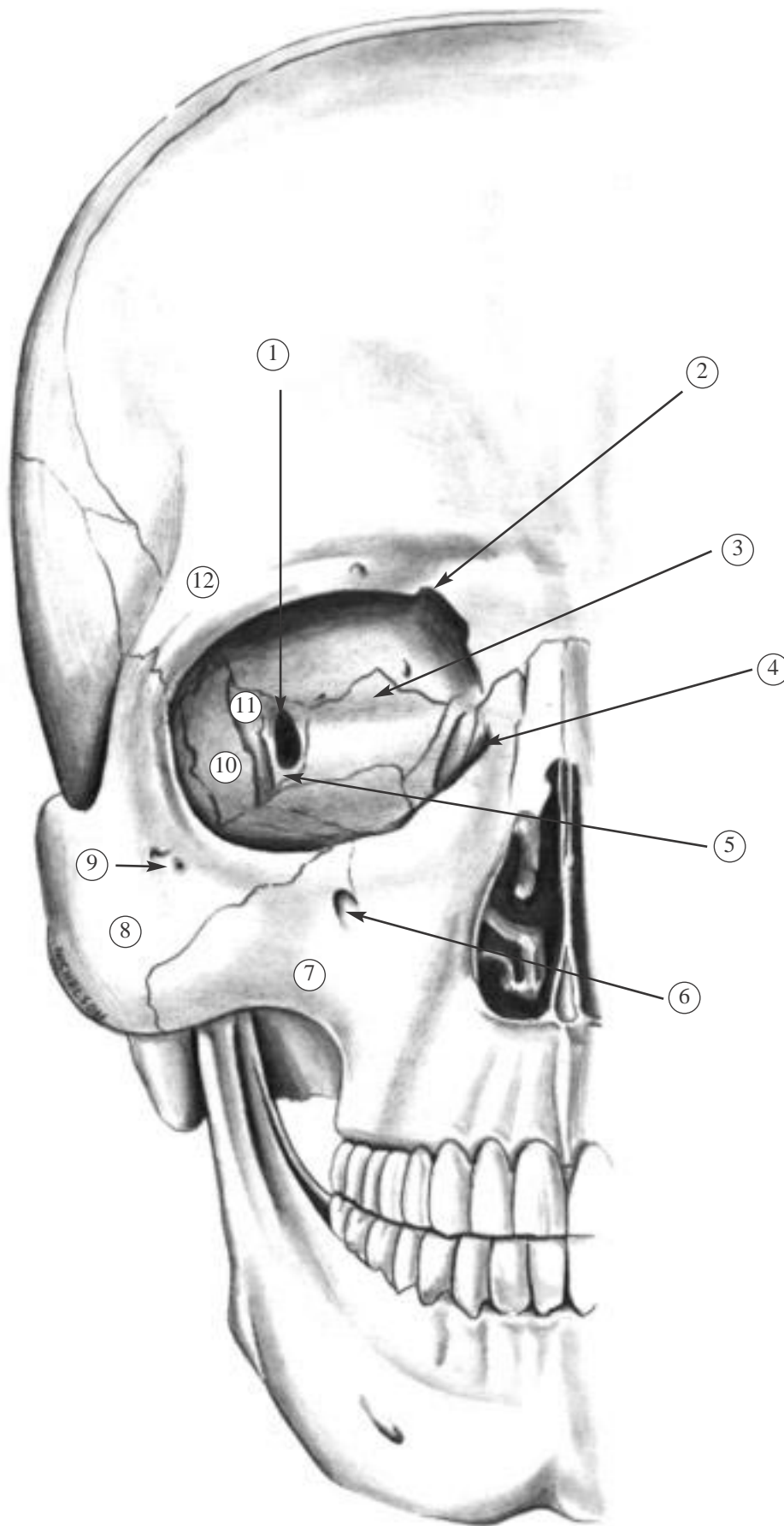
<i>Appendix 1: Corneal Folds Grading Atlas</i>	97
<i>Appendix 2: Specular Microscopy</i>	105
Legend 1-5	106
Legend 6-11	108
Legend 12-17	110
<i>Appendix 3: Eye Donor Slit Lamp Pathology</i>	113
Epithelial Defect	114
Exposure Keratopathy	115
Epithelial Defect and Exposure	116
Snail Tracks, Stress Striae	117
Electron Microscopy of Snail Tracks	118
Pterygium and Snail Tracks	119
Infant Corneas	120
Donor Rim with Iris.....	121
Donor with Lens Implant and Iris	122
Radial Keratotomy	123
Pterygium.....	124
Puncture Wound in Donor Cornea	125
Epithelial Sloughing	126
Legend 1-5	127
<i>Appendix 4: Penetrating Keratoplasty</i>	129
<i>Appendix 5: Glossary</i>	133
<i>Medical Standards-The Eye Bank Association of America Medical Standards-November 2003 Revision</i>	143
<i>Index to EBAA Medical Standards</i>	167
<i>Commercially Available Storage Available</i>	173
<i>Index</i>	184



Eye storage jar attributed to the "Eye Bank of the USA". The eye was sutured to vertical posts within the the jar. Moist cotton balls are used for cushioning and humidification at the bottom of the jar. (From H. Arruga, Ocular Surgery, 1962. in Mannis, M.J. and Mannis, A.A., eds. Corneal Transplantation: A History in Profiles, J.P. Wayenborgh, Belgium, 1999)

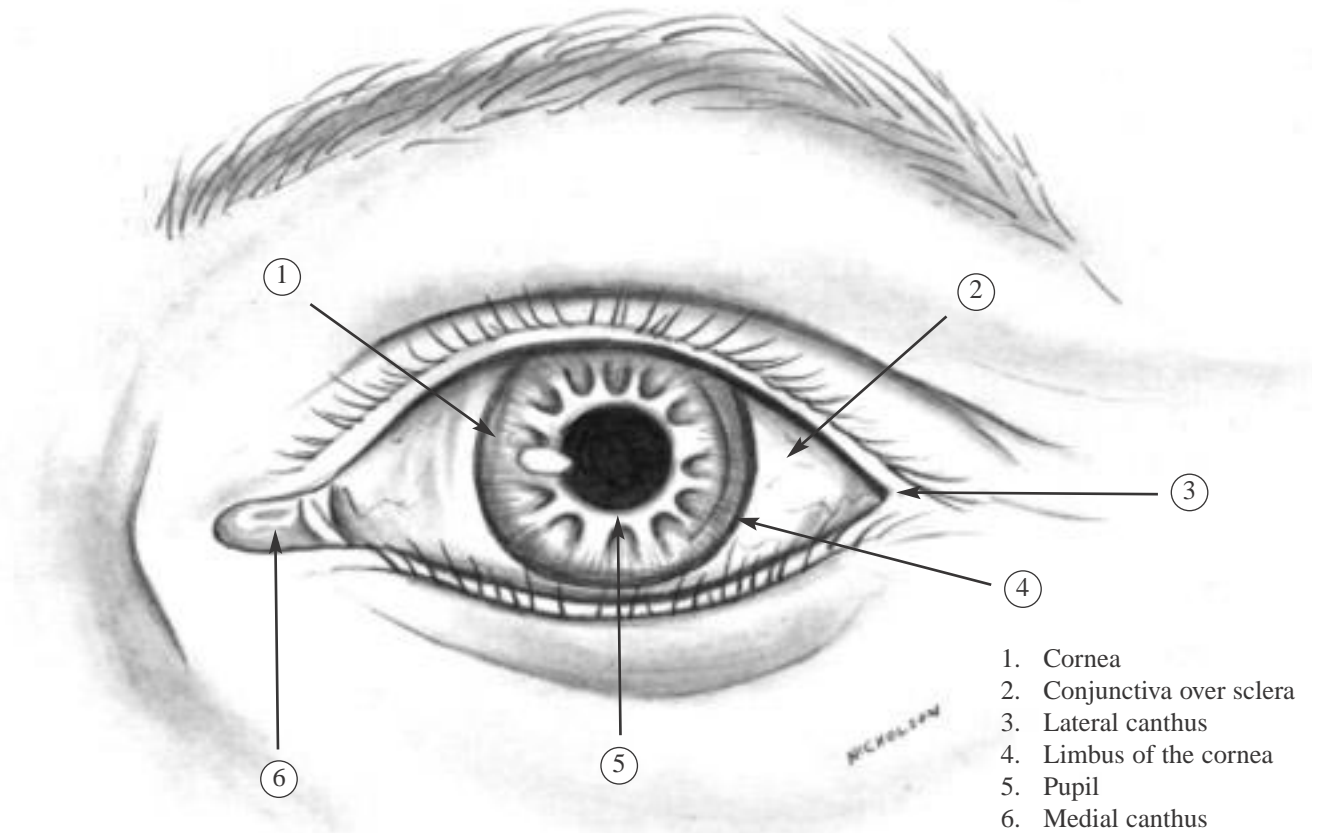
Anatomy

A collage of anatomical images, including a human eye and a cross-section of a biological structure, overlaid with a thick black horizontal line. The collage consists of several vertical strips of images. The central strip shows a close-up of a human eye with a blue iris. To the right, there is a cross-section of a biological structure, possibly a flower or a fruit, showing internal layers. The word "Anatomy" is written in a bold, black, serif font across the collage. A thick black horizontal line runs across the middle of the collage, partially obscuring the images.



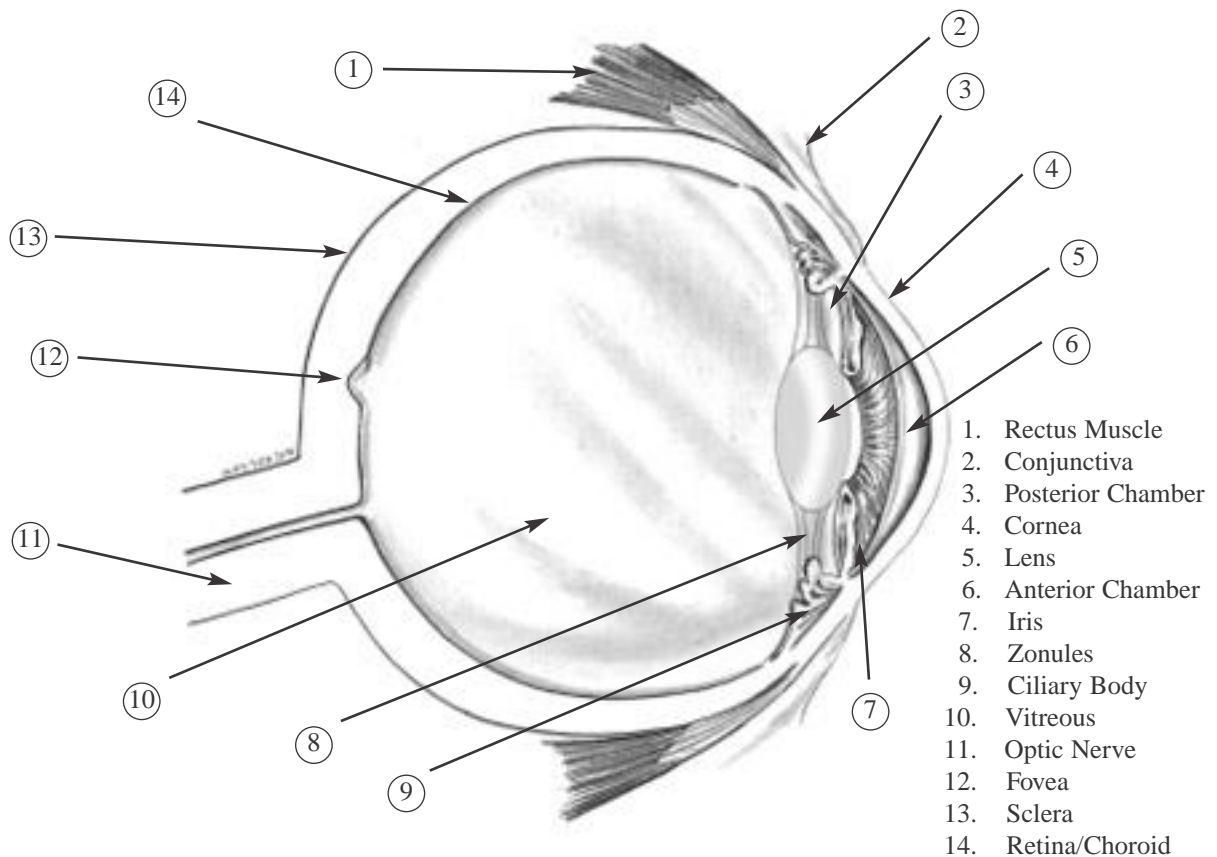
1. Optic foramen
2. Supraorbital notch
3. Ethmoid bone
4. Anterior lacrimal crest
5. Palatine bone
6. Infraorbital foramen
7. Maxillary bone
8. Zygomatic bone
9. Zygomaticofacial foramen
10. Greater wing of sphenoid
11. Lesser wing of sphenoid
12. Frontal bone

*Gross Anatomy of the Eye and Orbit
(Figure 1)*



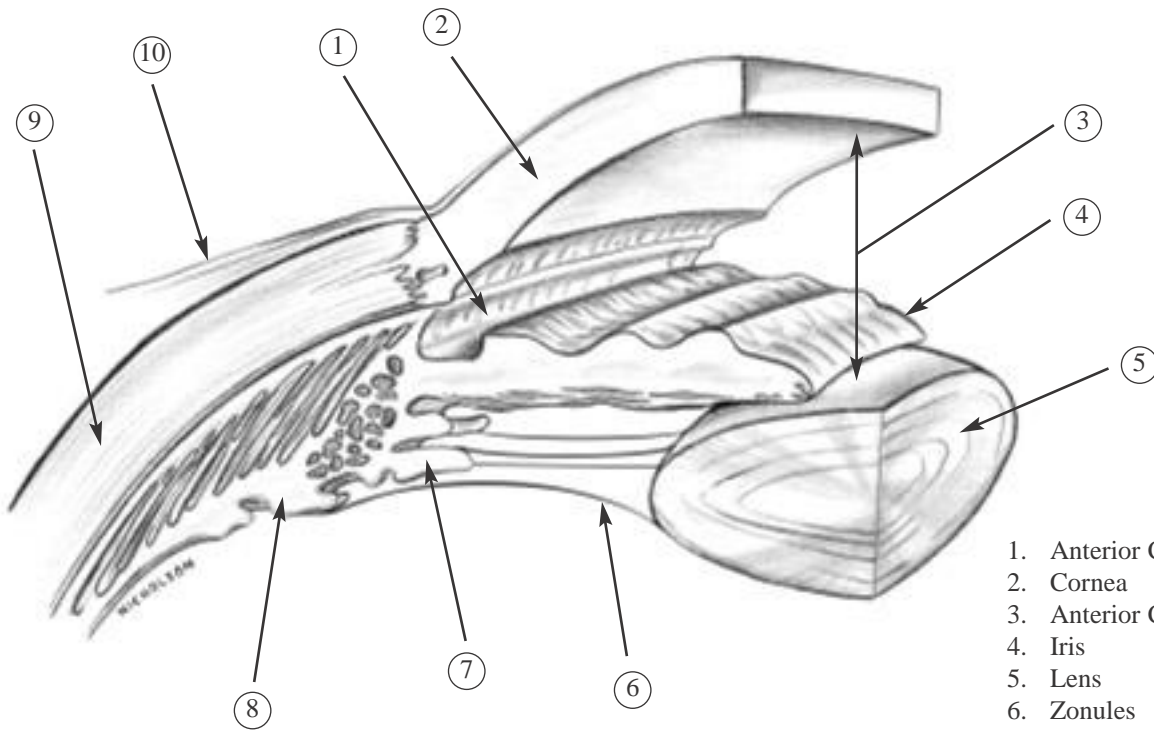
1. Cornea
2. Conjunctiva over sclera
3. Lateral canthus
4. Limbus of the cornea
5. Pupil
6. Medial canthus

*External Ocular Anatomy
(Figure 2)*



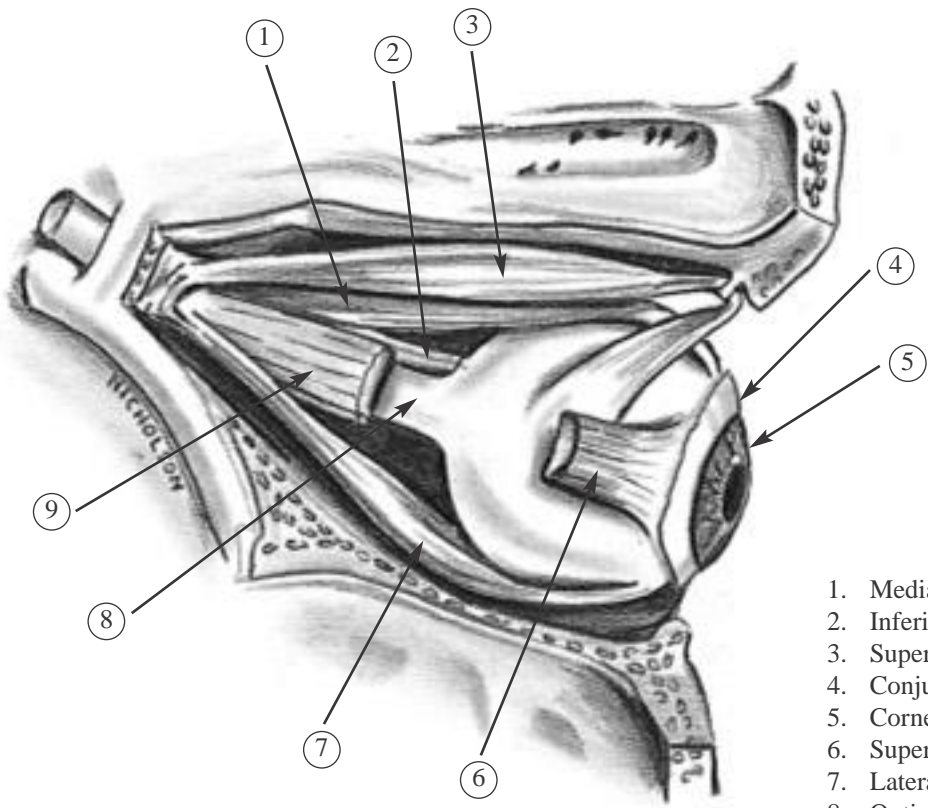
1. Rectus Muscle
2. Conjunctiva
3. Posterior Chamber
4. Cornea
5. Lens
6. Anterior Chamber
7. Iris
8. Zonules
9. Ciliary Body
10. Vitreous
11. Optic Nerve
12. Fovea
13. Sclera
14. Retina/Choroid

*Cross Sectional Anatomy of the Globe
(Figure 3)*



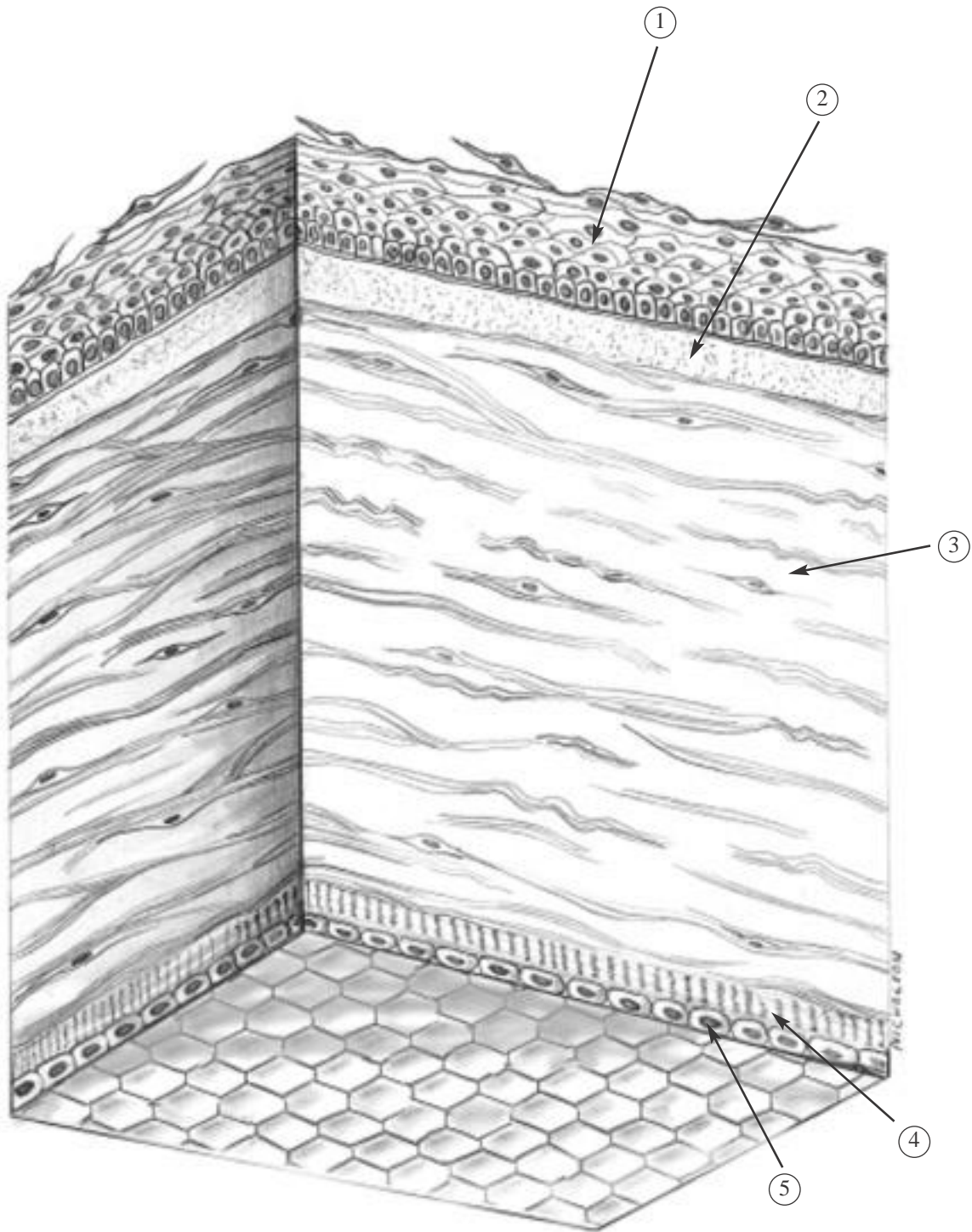
1. Anterior Chamber Angle
2. Cornea
3. Anterior Chamber
4. Iris
5. Lens
6. Zonules
7. Ciliary Processes
8. Ciliary Body
9. Sclera
10. Conjunctiva

*Anterior Chamber
(Figure 4)*



1. Medial rectus
2. Inferior rectus
3. Superior oblique
4. Conjunctiva
5. Cornea
6. Superior rectus
7. Lateral rectus
8. Optic nerve
9. Superior rectus

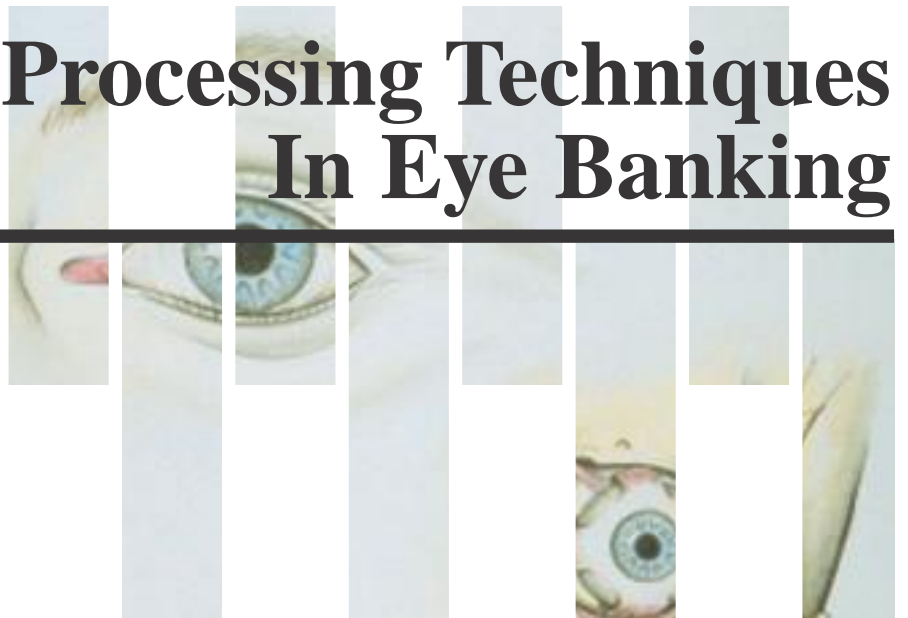*Anatomy of the orbit and extrinsic muscles of the eye. (view of dissection from above)
(Figure 5)*




- 1. Epithelium
- 2. Bowman's Membrane
- 3. Stroma
- 4. Descemet's Membrane
- 5. Endothelium

*Histological cross section of the cornea.
(Figure 6)*

Surgical Processing Techniques In Eye Banking





The von Hippel trephine demonstrating the key, the headpiece containing the clockwork spring, and attachable trephine blades.

(From Arthur von Hippel, 1841-1916, in Mannis, M.J. and Mannis, A.A., eds. Corneal Transplantation: A History in Profiles, J.P. Wayenborgh, Belgium, 1999)

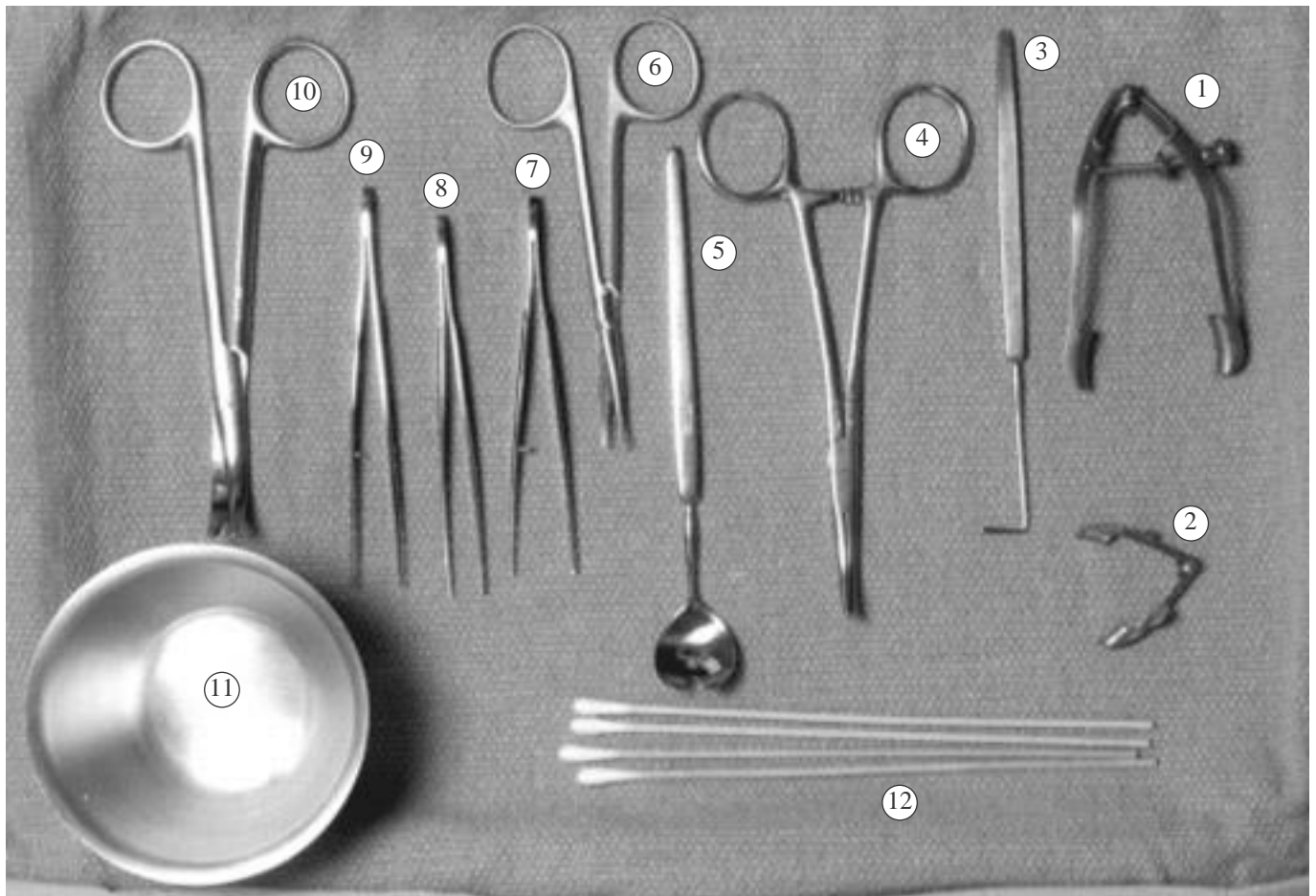
Instrumentation

Instruments for enucleation and excision come in a variety of styles and sizes (Figures 7 and 8). **Speculums** may be simple spring wire devices, or more complicated ones with lever expanding mechanisms, locks, and solid or open blades. All accomplish the same basic function. Most are standard size which fit individuals from small children (2-3 years old) to adults. For younger children and infants a special smaller “pediatric” lid speculum may be required.

Forceps come in three basic types. **Smooth forceps** are used for handling thin delicate membranes. **Serrated forceps** are used when fixation or a strong, high-friction grasp is required to apply tension to, or tear a flexible membrane (such as conjunctiva or Tenon’s). **Toothed forceps** are meant to fixate, move, or place tension on less delicate, more dense tissue such as sclera or cornea.

Scissors are used to shear various types of tissue. They are chosen by their size, durability, curvature, and blunt or sharp-pointed tip styles. Delicate tissue can be cut with small, relatively lightweight scissors. **Blunt tip scissors** are usually chosen for conjunctiva to allow them to push layers of tissue apart without perforation or laceration. A moderate curve allows the circumference of the globe to be followed. **Enucleation scissors** require heavy-weight, strongly curved blunt tips to push through the layers of tissue without catching, fit deep in the orbit behind the globe, and cut the optic nerve. The **corneal section scissors** are medium in weight with strong, blunt, curved tips to cut the sclera near the limbus without catching on the underlying tissue, or perforating into the vitreous. **Ring end handles** are used on larger scissors (ring handle scissors). Smaller or more delicate varieties have spring ends which help to open the blades (**spring handle scissors**). This is especially useful when the scissors are so small that they can only be handled by a person’s fingertips.

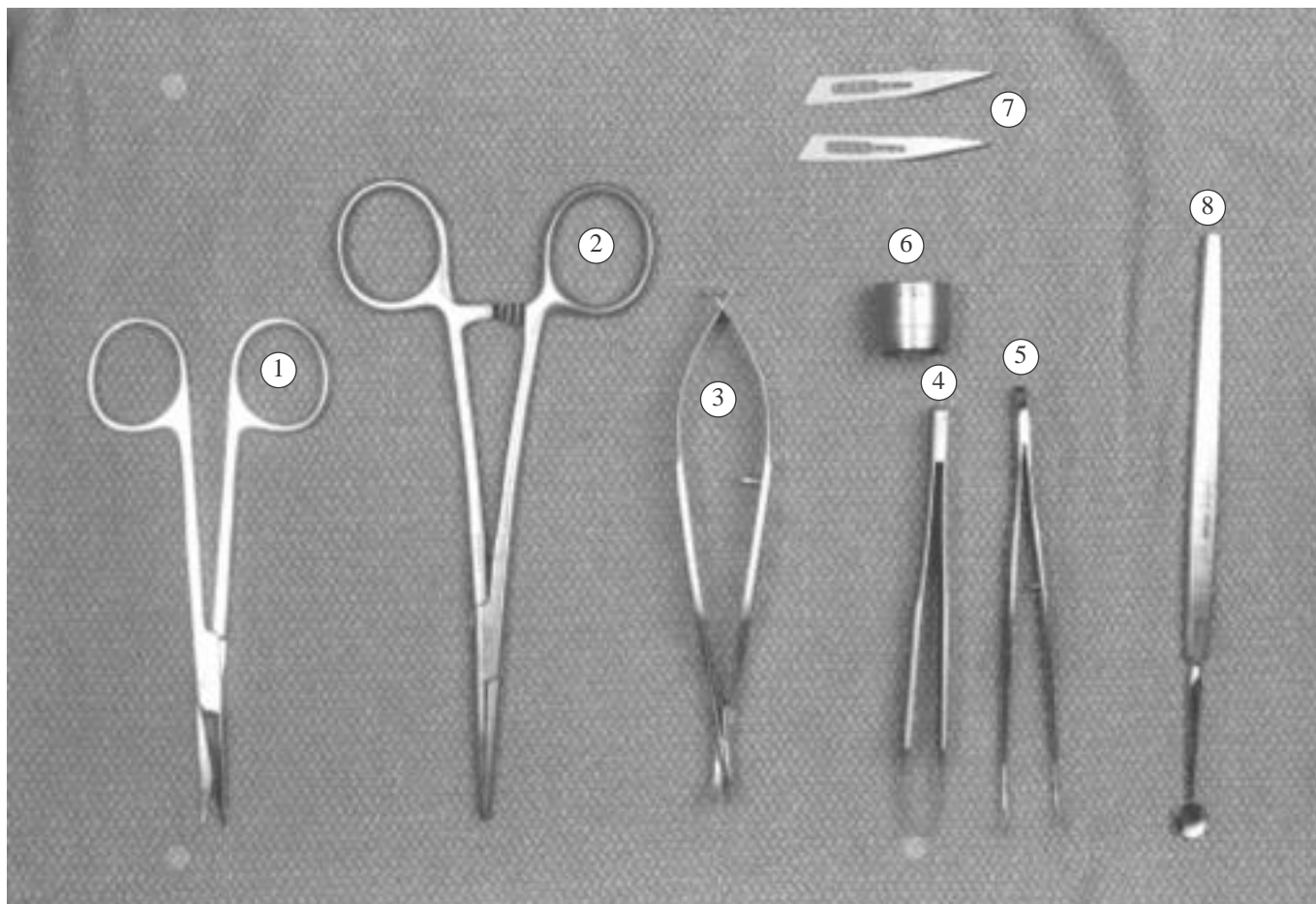
The **enucleation spoon** is a cup on a handle with a groove cut in it for the optic nerve. Its used to lift the globe out of the orbit and also to protect the posterior globe when cutting the nerve. A similar looking device, the **evisceration spoon** is smaller, with sharp edges, and is used exclusively to scrape or curette the inside surface of the posterior globe after removal of the corneo-scleral rim.



*Instruments for enucleation.
(Figure 7)*

- | | |
|-----------------------------|--|
| 1. Adult speculum | 7. Toothed tissue forceps (with stop) |
| 2. Pediatric speculum | 8. Toothed tissue forceps |
| 3. Muscle hook | 9. Serrated tissue forceps |
| 4. Hemostat | 10. Heavy-duty curved enucleation scissors |
| 5. Enucleation spoon | 11. Metal bowl |
| 6. Light duty ring scissors | 12. Cotton tipped applicators |

Muscle hooks are “L” shaped instruments used to hook under the rectus muscles. **Hemostats** or **clamps** are usually serrated-tipped to hold thicker tissue, such as the rectus muscles, when they are used as a handle for the globe. They lock by closing the ring handles together and open by squeezing and separating the ratcheting portion of the handle lock, placing the ring handles in different planes, in a sideways motion.



*Instruments for cornea excision.
(Figure 8)*

- | | |
|-------------------------------------|-------------------------------|
| 1. Ring handle scissors | 5. Serrated tissue forceps |
| 2. Hemostat | 6. Trepine |
| 3. Blunt-tip spring handle scissors | 7. Pointed tip scalpel blades |
| 4. Fine-toothed tissue forceps | 8. Evisceration spoon |


Scalpel blades used in eye banking techniques are usually straight, sharp-point tipped, similar to a standard Bard Parker® # 11 blade. Some prefer to use a curved tip blade similar to a Bard Parker® #15 blade, especially for scraping the conjunctiva from the globe. They dull quickly and are disposable. **Trephines** are tubular blades sharpened at one end. They can be used to mark or partially cut the corneo-scleral rim. Because of their heftier construction and expense they are frequently re-used and may be re-sharpened.



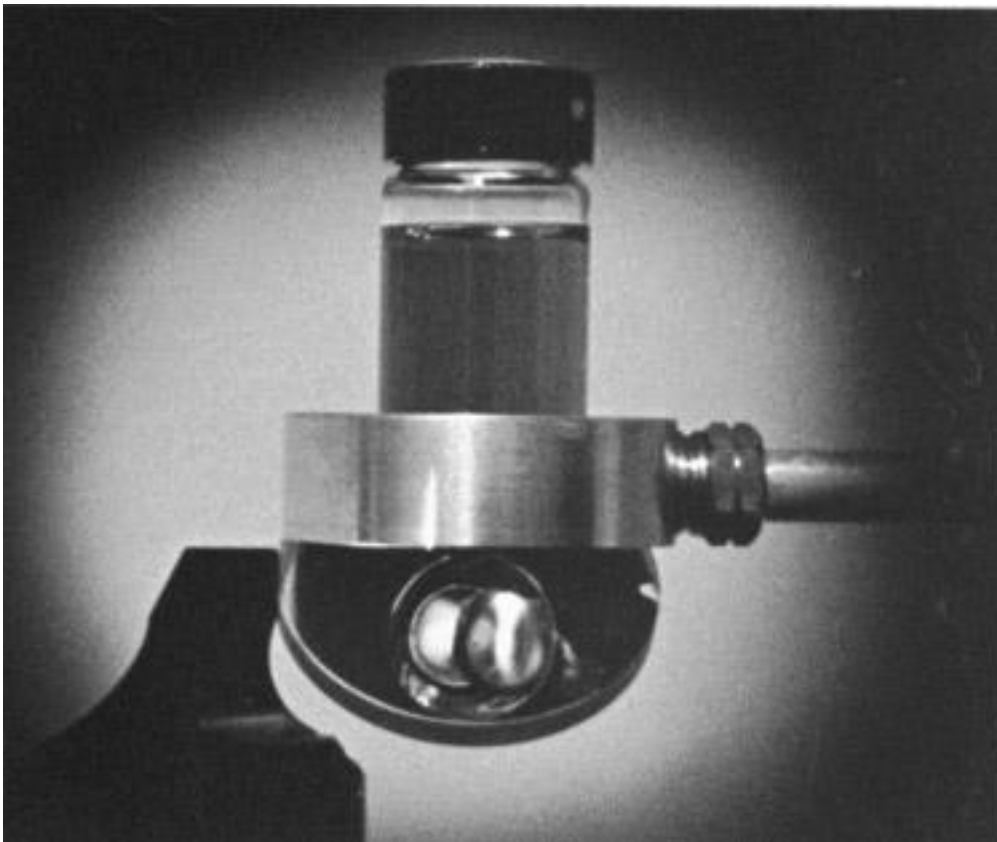
*Sterile cage and jar for whole globe transport. An alligator clip is used to secure the nerve and fixate the globe to the cage structure. The gauze at the bottom is moistened with sterile eye wash, saline, or balanced salt solution to provide high humidity in the chamber, hence the name "moist chamber storage".
(Figure 9a)*

Enucleated globes are stored and shipped in moist chambers using a cage device and alligator clip to fixate the globe (Figure 9a). Corneal storage and viewing chambers (CSVC's) come in two sizes to fit existing specular microscopes (Figure 9b). As an alternative corneo-scleral rim tissue can be placed in glass vials used for media shipping and storage and viewed in vertical fixation devices with mirrors attached to allow horizontal viewing at the slit lamp (9c).

Terminology of eye banking instruments includes the terms **contaminated**, **external**, **clean** and **internal**. **External** instruments describe those which are used on the conjunctiva and sclera which are kept separate from those used to handle the cornea and perform the excision. **External** instruments are considered **contaminated** due to their contact with the non-sterile external tissue. **Clean** and **internal** instruments are used to handle internal structures of the eye which are considered sterile and non-contaminated. The major objective of importance is to avoid having the external instruments mix with the internal instruments, thereby avoiding contamination of the donor tissue.

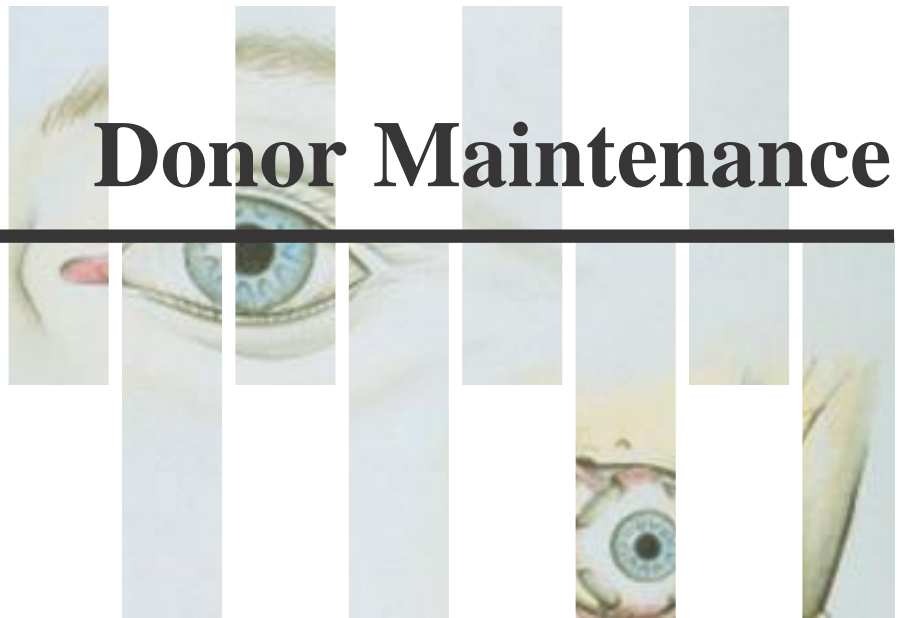

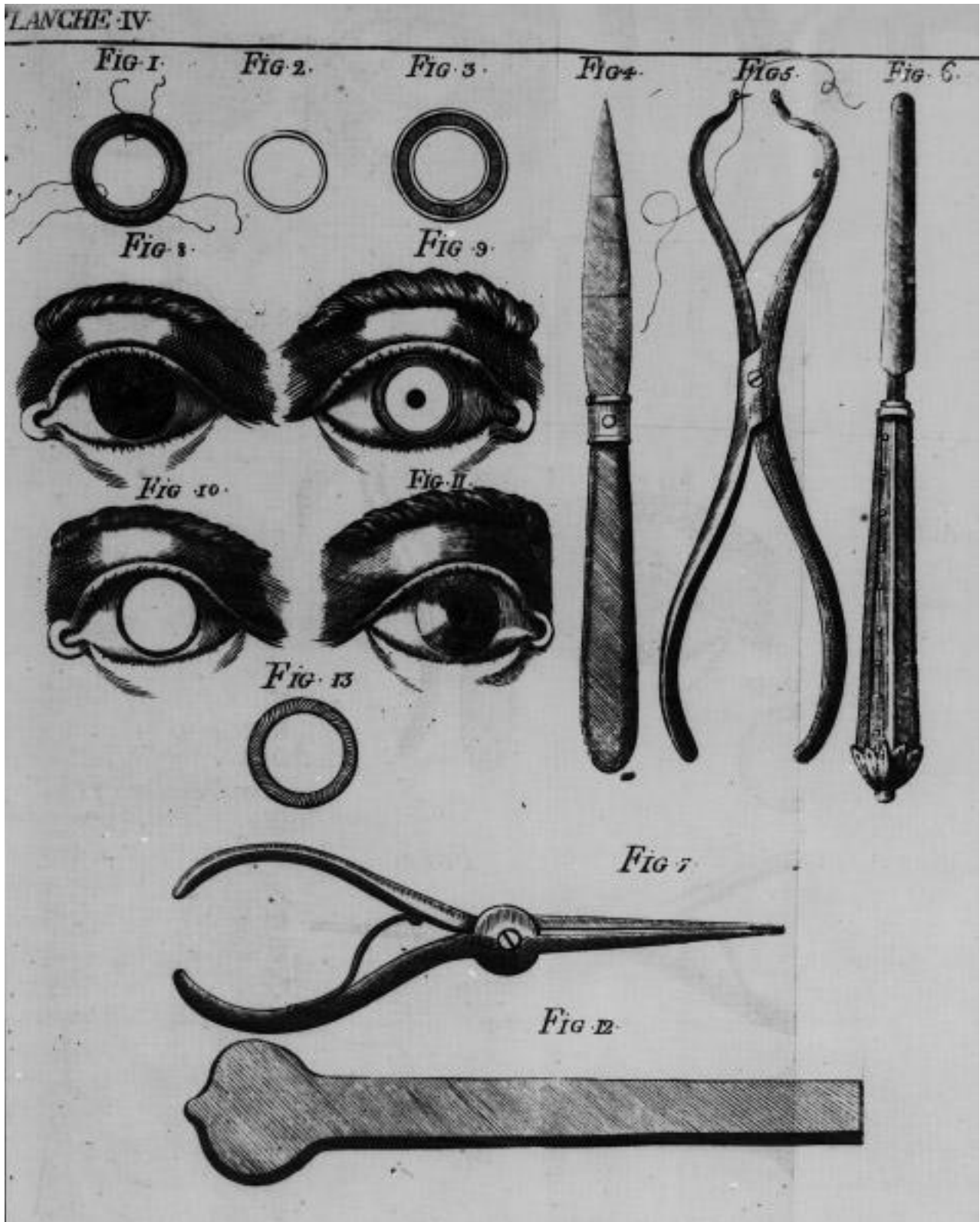
Corneal storage and viewing chambers (CSVC's). The upper photo shows the overall view. The lower photograph illustrates the diameter of the chambers as well as the internal structure that supports the corneal-scleral button. The two sizes are to accommodate different specular microscopes. (Figure 9b)



*A glass vial (see Figure 12), typically used to supply media in, may also be used as a container for the donor tissue. Specular microscopy is not able to be performed in this type of container. Slit lamp evaluation and specular reflection of the endothelium may be performed with the slit lamp viewing mirror as shown.
(Figure 9c)*

Donor Maintenance





A sketch of the proposed keratoprosthesis from Precis. It was to be made of a thin piece of glass, fitted into a silver ring. He also designed several surgical instruments to be used for this operation.
 (From Guillaume Pellier 1751-1835, Pohlman C.A., in Mannis, M.J. and Mannis, A.A., eds. *Corneal Transplantation: A History in Profiles*, J.P. Wayenborgh, Belgium, 1999)

Maintaining the Donor

After the declaration of death of a donor the, the body must be maintained to avoid degradation of the eye tissue. Exposure, trauma, bacterial replication, and inappropriate storage temperature can all take their toll on the donor tissue. By using antibiotic drops, lubricant, taping the lids shut, and placing ice packs over the eyes, most of the pitfalls of donor maintenance can be avoided. Elevation of the head prevents swelling (dependent edema) of the periocular and facial tissue, allowing better restoration of the body if a viewing is planned. It is important to be aware that ice made from water, or commercial ice packs cooled to zero degrees centigrade, thirty two degrees Fahrenheit, is the type used in virtually all eye banking protocols. This type of ice is called “wet ice” and cooling packs that are substituted for wet ice are cooled only to the temperature of wet ice. Dry ice, which is solid carbon dioxide, is much colder (-78.5°C, -109°F) and will freeze tissue, causing irreversible damage. Throughout this text “ice” refers to “wet ice”.

The Eye Bank Association of America (EBAA) protocol for donor maintenance follows.

EBAA Donor Maintenance Protocol

D1.600 Ocular Tissue Donor Maintenance

Purpose:

To retard the deterioration of eye/corneal tissue following cardiac asystole, prior to recovery of ocular tissue.

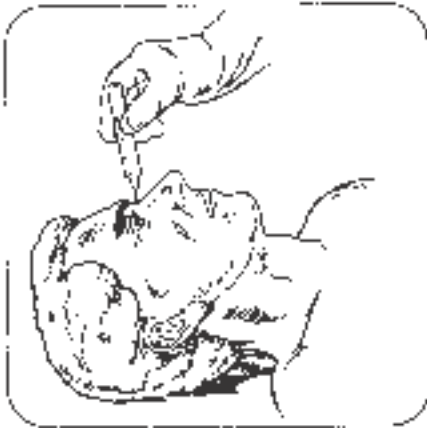Materials needed:

Wet ice packs (such as rubber gloves filled with crushed ice) Note: Ice should be wet ice
Sterile ophthalmic broad-spectrum antibiotic solution, sterile normal saline or balanced salt solution (BSS)
Lubricating ointment for ventilator maintained donors
Paper tape
Pillow or head block

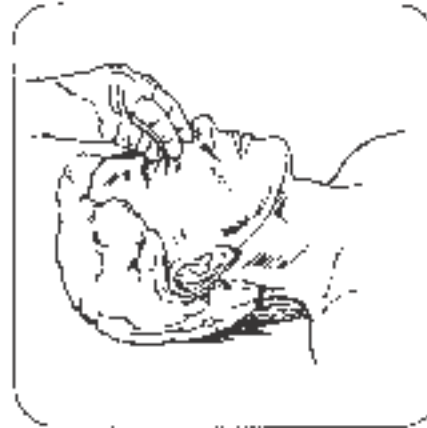Procedure with Rationale in Italics

1. Instill sterile ophthalmic antibiotic solution two gtts (drops) o.u., or sterile saline or balanced salt solution prior to recovery of ocular tissue.
Provides lubrication and moistening of corneal tissue. Antibiotic solution retards microbial growth prior to enucleation or in situ corneal removal.
2. Lubricating ointment may be beneficial in ventilator maintained donors prior to organ, eye, and tissue recovery.
Ointment helps to prevent corneal dryness in the absence of the blink reflex on brain-dead ventilated donors.
3. Lightly tape eye lids closed with paper tape.
Prevents natural opening of lids due to decreased muscle tone and post mortem relaxation of eye lids, which exposes corneal epithelium to air, resulting in damage to eye tissue. Paper tape will prevent tape burns to lids and reduce chances of pulling out eye lashes.
4. Lightly apply wet ice packs over eyes, securing gently in place.
Wet ice provides a cool environment around the eyes in an attempt to decrease the effects of metabolic byproducts (toxins) on eye tissue, which occur naturally within the body after death. This deterioration can be slowed by application of ice over eyes and refrigeration of the body as soon as possible after death.
5. Elevate the donor's head.
Prevents pooling of blood in head to decrease incidence of bleeding and swelling in eye region following enucleation.
6. Record whether these procedures were carried out on your eye bank's donor screening form or donor information form.
This information should be used to evaluate the suitability of the corneal tissue for surgical use.

Donor Maintenance Illustration



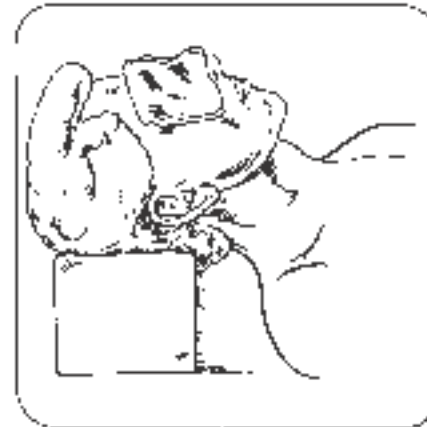
Irrigate the eyes with aqueous sterile solution, such as normal saline--not ointments like lacrilube



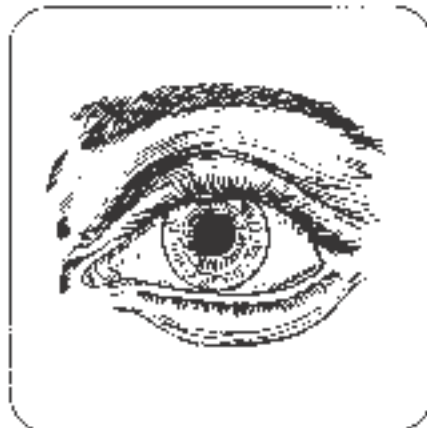Close the eye lids



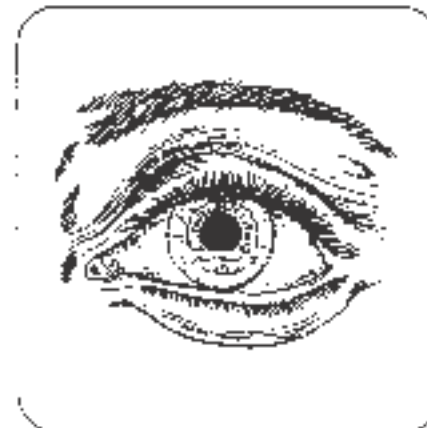Apply cool compress over the closed eye lids.



Keep head elevated!



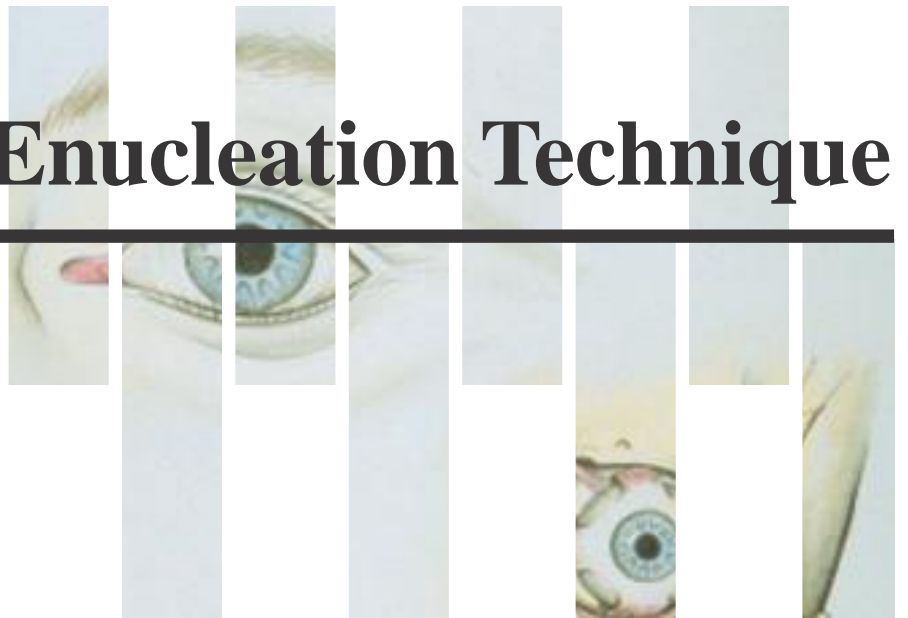
Nursed eye with eye care

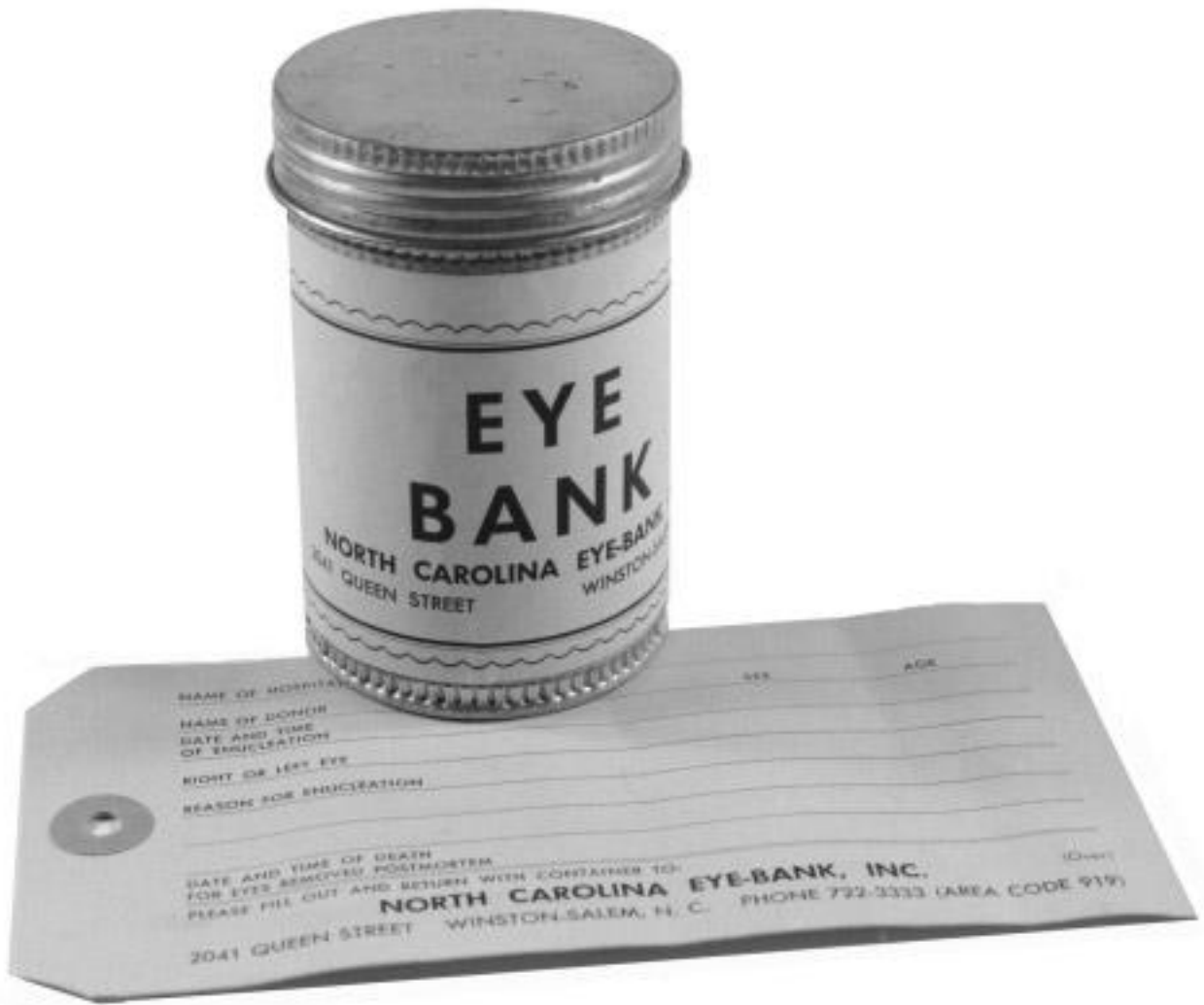

Dry eye without eye care

Courtesy Dean Vavra, M.S., C.E.B.T., Rocky Mountain Lions Eye Bank

Enucleation Technique





*Metal and cardboard can used to transport globes for the North Carolina Eye Bank Inc.
(From the collection of George O.D. Rosenwasser. in Mannis, M.J. and Mannis, A.A., eds. Corneal Transplantation:
A History in Profiles, J.P. Wayenborgh, Belgium, 1999)*

Enucleation

Enucleation of donor eyes is generally used by eye banks serving large geographic, especially rural, areas. When a donation takes place, the eyes are enucleated, placed in moist chambers, and shipped to a central processing laboratory for corneal cap removal. Accompanying the eyes are a blood specimen, consent and screening form.

A kit containing all disposables needed as well as an instrument kit is taken to the donor. The enucleator scrubs and gloves after laying out supplies on a sterile field. Preparation of the enucleation site involves irrigating the area with sterile saline or a similar solution and performing a skin prep with povidone iodine, as well as placing a drop or two of diluted solution (sterile saline and a drop of 10% povidone iodine solution) in the conjunctival cul de sac (the space between the globe and the lids). Some protocols use gentamicin ophthalmic drops or saline irrigation. The sterile drape is then placed.

A lid speculum is placed while opening the lids with sterile gloved fingers, sterile cotton tipped applicators, or sterile gauze, taking care not to touch or otherwise damage the donor epithelium. Using a toothed forceps, the conjunctiva is tented up close to the limbus. The “tent” is then cut with the small scissors. The forceps and scissors are used to cut the conjunctiva close to the limbus, all the way around (Figure 10a). Then the scissors can be opened in the space between the globe and conjunctiva to further separate the conjunctiva from the globe posteriorly (Figure 10b).

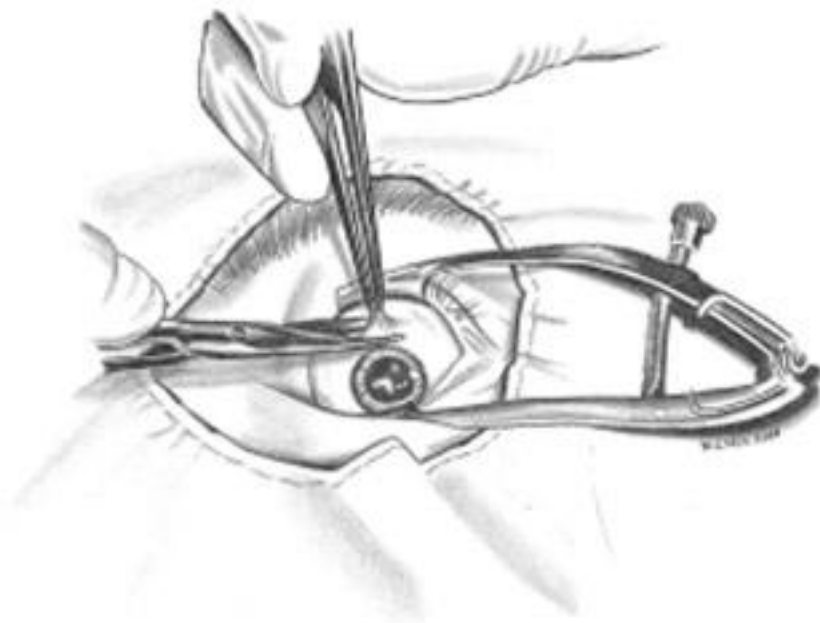
A muscle hook is pressed close to the globe and the tip advanced clockwise or counterclockwise to hook under the lateral rectus muscles. When it “catches” (hooks underneath the muscle) it is lifted vertically (Figure 10c). A forcep is used to remove Tenon’s capsule and each muscle is cut with the scissors close and parallel to the globe (not as shown in the figure, where the scissors are *distal* to the hook). When working on the last muscle, a hemostat is applied to the muscle and the cut is placed past the hemostat, away from the globe, leaving the hemostat attached to the globe by a short stub of muscle acting as a handle (Figure 10d). The globe can be lifted by the hemostat and the nerve then cut with the heavier enucleation scissors from the nasal side.

Insert the enucleation scissors closed, open them prior to getting to the nerve, push more posteriorly and move the closed tips side to side to locate the nerve (“strum” the nerve like an instrument string). Open the tips and straddle the nerve with the blades (Figure 10e). Cut the nerve and lift the globe out with the hemostat. Note that if the scissors can be pushed further back, a longer section of nerve can be obtained. This makes fixing the globe in the transport cage easier.

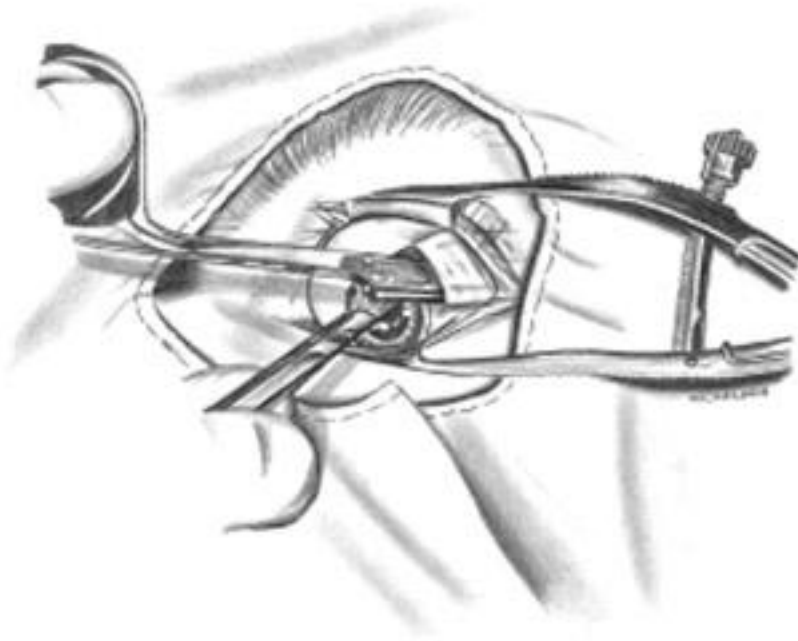
The oblique muscles and fascia can now be trimmed off. The globe is then placed in the sterile cage for transport. An alligator or similar clip is used to secure the nerve and fixate the globe in the cage (Figure 9a).

The jars should be positioned such that appropriate labels can be assigned for right and left. Before inserting, the cage and globe, a gauze moistened with irrigating solution or antibiotic solution is placed in the bottom of the sterile jar. The jar is then sealed and enucleation of the fellow eye performed.

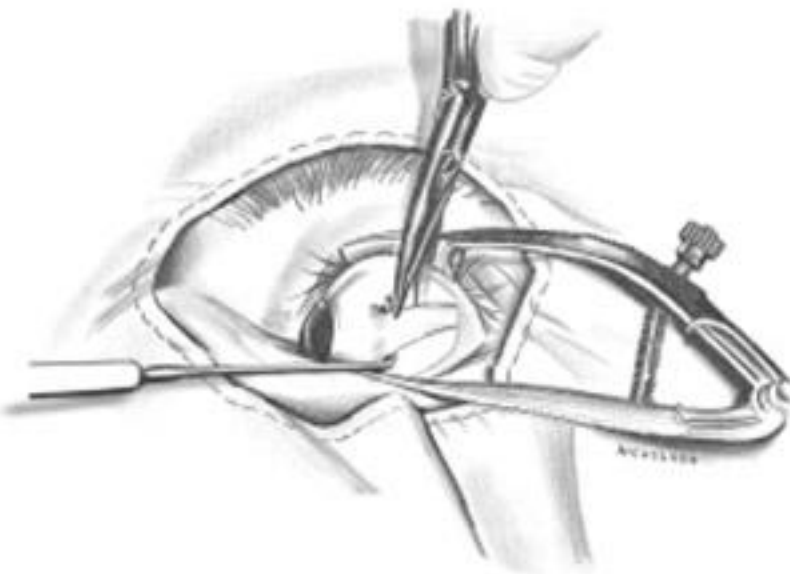
Enucleation technique showing tenting and penetration of the conjunctiva (a), blunt dissection of the conjunctiva (b), using the muscle hook to find and elevate a rectus muscle (c), attaching the hemostat to the muscle near the globe and cutting distal to control the globe (d), and cutting the optic nerve, (e).
(Figure 10)



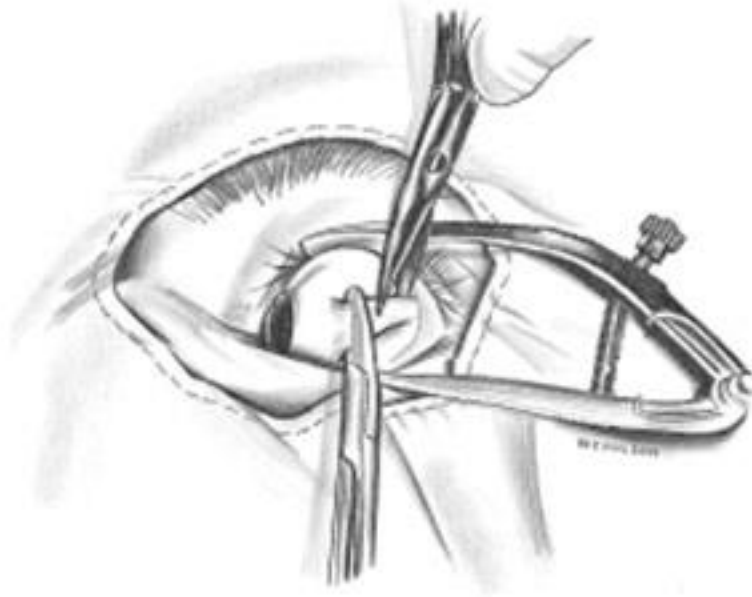
(Figure 10a)



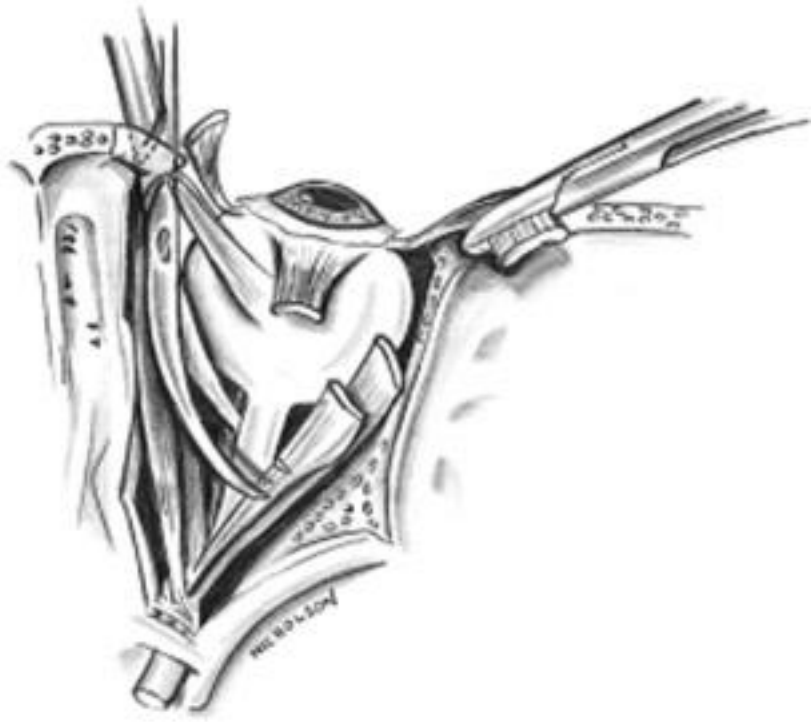(Figure 10b)



(Figure 10c)



(Figure 10d)



(Figure 10e)

EBAA Enucleation Protocol

E1.100 Enucleation

Purpose:

To provide a standardized method for the aseptic removal of human eye tissue.

This procedure describes the basic technique for performing an eye enucleation according to EBAA standards. Certain portions of the procedure are at the discretion and direction of your eye bank's medical director. Please refer to your eye bank's procedures manual as directed.

Materials needed:

1. Sterile Supplies:

A sterile instrument tray: (The tray may be either steam or gas sterilized, appropriately wrapped, labeled with expiration date, and stored in plastic according to your eye bank's policy.)

- 1 Small curved scissors
- 1 Large curved enucleation scissors
- 1 Small (mosquito) curved hemostat
- 1 Small muscle hook (retractor)
- 1 Small toothed forceps
- 1 Eyelid speculum
- 2 Fenestrated eye drapes or 1 double-fenestrated drape
- 2 Plain drapes (optional, if the fenestrated drapes are moisture impermeable)
- 1 Hemostat for handling ophthalmic irrigating solution
- 2 x 2 gauze sponges
- Cotton balls
- Sterile cotton-tipped applicators
- Sterile eye jars, either glass or plastic. The eye jars may be sterilized within your Instrument tray or separately. They should contain dental roll, gauze, or metal cage to hold the eye.
- Sterile gloves (at least 2 pair)
- Sterile gown or sleeves

2. Non-sterile Supplies:

Styrofoam container for transporting the eyes
Personal protective equipment.

Procedure with Rationale in Italics

1. All donor preparatory and pre ocular tissue recovery procedures should be performed according to procedure E1.050.
2. Set up the sterile right and left eye jars. Check instruments to be sure none are missing or damaged.
3. According to your eye bank's policy, begin with the left or right eye. Using 2 x 2 gauze or a cotton tipped applicator, gently open the upper lid by pulling towards the top of the head, insert the closed lid speculum under the upper and lower lids near the nose. Slowly open the speculum while moving toward the middle of the eye. Be very careful not to touch the cornea with the speculum.
This provides access to the eye during the enucleation procedure.
5. Grasp the conjunctiva with the forceps, near the lateral edge of the cornea at the limbus. Cut the conjunctiva with the small, round tip scissors pointed away from the cornea. Continue this 360° all the way around the cornea.
Cutting the conjunctiva provides the enucleator access to the ocular muscles and optic nerve and removes a membrane that may be contaminated with bacteria.
6. Insert the closed scissors under the conjunctiva and perform a blunt dissection.
To facilitate access to the ocular muscles.
7. Sever the ocular muscles one at a time. Insert the muscle hook into the medial quadrant and hook the medial rectus muscle. A hemostat may be applied to clamp the muscle. Remove the muscle hook and cut the medial rectus muscle on the distal side (outside) of the hemostat.
This description of cutting the ocular muscles is one of several ways to remove the eye. Please refer to your local eye bank's procedure manual for any variation. All 6 ocular muscles must be isolated and severed; however, the order and technique may differ.
8. Begin cutting the remaining ocular muscles. Slide the muscle hook superiorly and hook the superior rectus muscle. Pull the muscle up while gently rotating the globe inferiorly. Cut the muscle distal to (outside) the muscle hook with the small scissors.
Be careful not to puncture the globe during severing of the muscles. The sclera is thinnest underneath the insertion sites of the ocular muscles.
- 8a. Repeat step 7 for the inferior rectus and lateral rectus muscles.
9. Optionally you may locate and cut the superior and inferior oblique muscles. With the hemostat, rotate the globe laterally. Be careful not to rub the cornea on the speculum. Open the large scissors about 1/4 inch, and slide into the superior medial quadrant. Sever the superior oblique muscle. Repeat in the inferior medial quadrant for the inferior oblique muscle.
Do not traumatize the cornea during this procedure.

-
-
10. With the globe still rotated laterally, insert the closed blades of the large enucleation scissors behind the back of the eye. Open the blades slightly and position the optic nerve between the blades. Push the scissors towards the back of the orbit and cut the optic nerve, leaving 1/4" - 1/2" (6-12mm) inch stump.

A 1/4" - 1/2" (6-12mm) inch optic nerve stump will assure that it is not cut too close to the posterior so as to risk puncture and collapse of the globe. A generous stump also allows for sufficient length to anchor the eye in the cage, if used by pulling the stump through the bottom.

11. Use the hemostat, which is clamped to the medial rectus muscle, to gently lift the globe from the socket. Carefully cut any remaining connective tissue.
12. If using eye jars with metal cages, place the eye in the metal cage with the cornea facing up. Place the optic nerve through the bottom hole of the cage and hang the hemostat from the optic nerve. Secure the eye in the jar by either clamping or pinning the optic nerve. Place the cage back in the jar.

If a cage is not used, prepare a bed with gauze or cotton dental roll and place the eye in the jar with the cornea facing up. Make sure that the cornea is not rubbing against the sides or top of the jar.

Although pins have been used to secure the eye in the cage, they introduce increased risk of puncture to the ocular tissue and the eye bank technician. They may also be difficult to remove.

13. Pour a **small amount** or approximately 5 ml of balanced salt, antibiotic solution, or other sterile ophthalmic irrigating solution over the eye (just enough to moisten the cotton or gauze in the bottom of the jar). If you are using a non-sterile bottle, handle the bottle with a sterile hemostat. Otherwise, you must reglove. If you have double-gloved, remove outer gloves following handling of the non-sterile bottle.

Handling of a non-sterile bottle will contaminate your glove unless you use a sterile instrument such as a hemostat or test tube holder to handle it. Gauze is an unacceptable barrier and cannot be used to handle non-sterile items.

14. Repeat steps (1-13) above for the other eye. The second eye should already be draped.

15. Completion

- A. Remove drapes

- B. Place a folded piece of gauze or a cotton ball in the socket and insert eye caps per your eye bank's policy. Close the lids and gently wipe off the povidone-iodine or other solution by patting with moist gauze.

To restore the appearance of the donor.

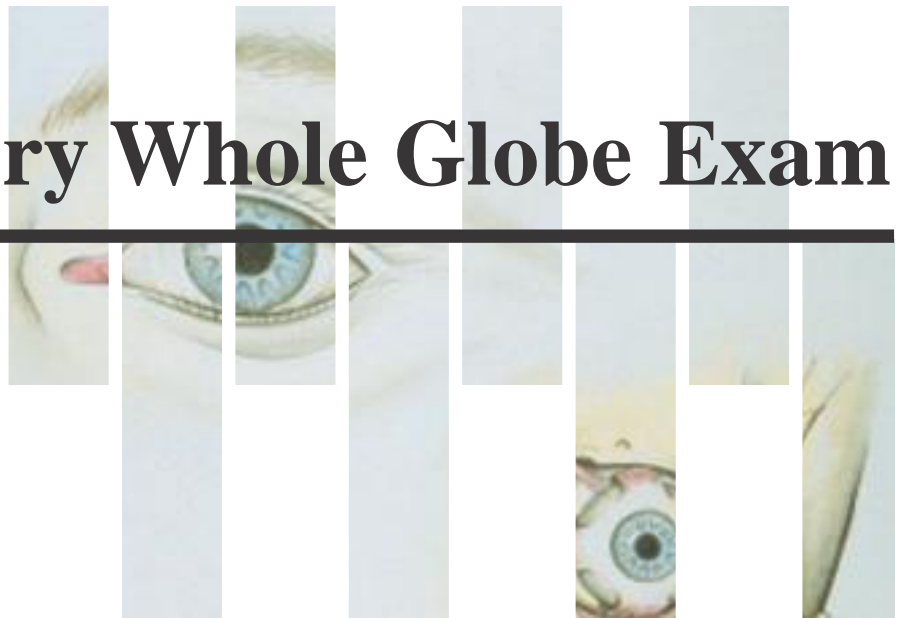- C. If necessary, control excessive bleeding. Check with your local funeral directors and follow your eye bank's protocol. Trocar buttons, local cauterizing agents, gel foam, and other techniques may be used. If this is also a skin donor, apply 4 x 4's over the closed eye

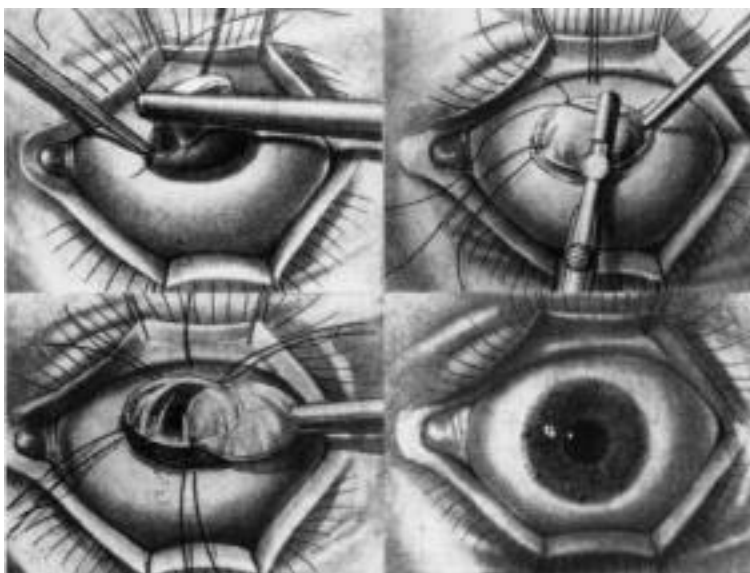
lids and securely wrap the head with kling gauze.

These procedures should be developed in consultation with your local funeral director and skin or tissue bank.

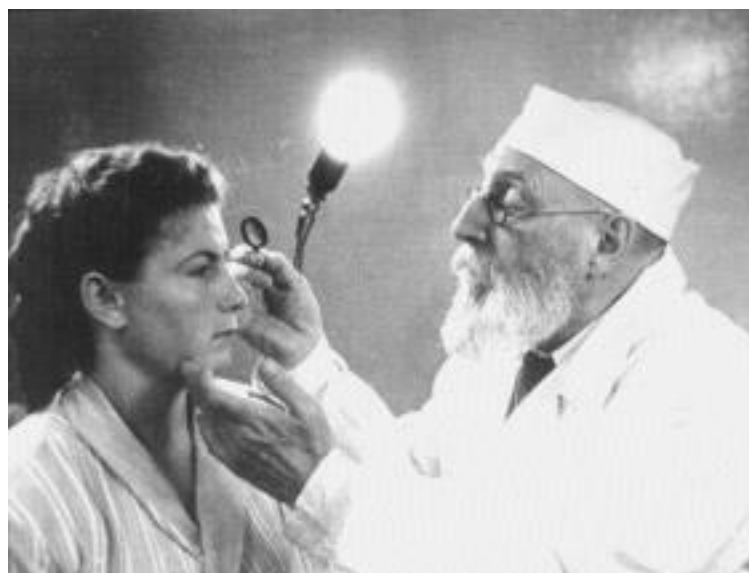
- D. Leave the donor's head elevated.
- E. Remove surgical gloves, place the lids on both jars, being careful NOT to touch the inside of the jar.
Surgical gloves should be removed so that the exterior of the jars are not contaminated with eye tissue or body fluid, avoiding the creation of a potential biohazard.
- F. Label each eye jar (see procedure J1.000) and place both jars in transport canister with wet ice to maintain the temperature between 2 - 6° C.
- G. Record information about the enucleation in the donor's medical record according to your eye bank's policy.
To fulfill JCAHO requirements on documentation of tissue and organ removal.
- H. Complete the eye bank's enucleation form, as required.
- I. Leave a form or attach a tag to the body informing the funeral director that the eyes have been removed and to keep the head elevated. Also give the eye bank's name, location, and phone number with instructions to notify the eye bank if there are any questions or problems.
- J. Don nonsterile gloves and rewrap the donor in the body bag or shroud and return to the storage location from which it was removed.
- K. Clean the work area. Discard all used disposables in a biohazard bag and all sharps in a sharps container.
- L. Rewrap instruments for return to the eye bank or for cleaning and sterilization by the facility if that is your eye bank's protocol.
- M. Transport the eyes to the eye bank as soon as possible.

Laboratory Whole Globe Exam





Filatov's 1930's Keratoplasty technique



Vladimir Filatov. Early 20th century. Pioneering corneal transplant surgeon

(From Vladimir Filatov, 1875-1956, Rosenwasser, G.O.D., Rosenwasser, M. in Mannis, M.J. and Mannis, A.A., eds. Corneal Transplantation: A History in Profiles, J.P. Wayenborgh, Belgium, 1999)

The Whole Globe Exam

After obtaining the donor globes by enucleation the corneal caps are separated from the rest of the globe, and the sclera preserved if desired. The following protocol is an example of one acceptable method for whole globe examination.

EBAA Donor Globe In Vitro Exam Protocol

F1.200 Slit Lamp Examination In Vitro

Purpose: To delineate the procedure for slit lamp biomicroscopy of corneal tissue in the laboratory.

Materials needed:

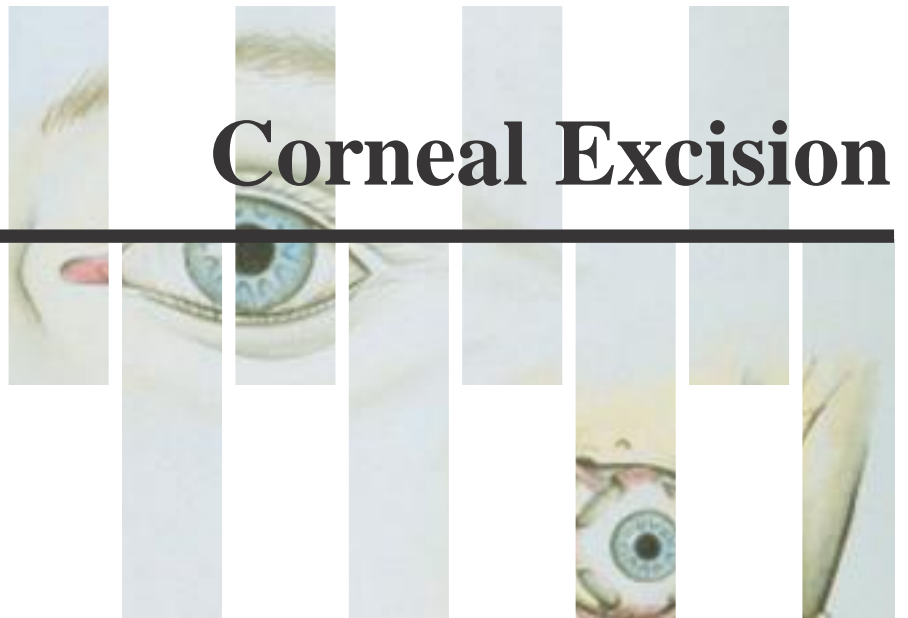
Slit lamp biomicroscope
Utility clamp or other appropriate device to hold the ocular tissue
Sterile Cotton-tipped applicators
Sterile ophthalmic irrigating solution
Sterile gloves
Alcohol prep pads
Mask and cap
Rating scale
Forms for documentation

Procedure with Rationale in Italics

1. Allow the eye or cornea to reach normal room temperature. Avoid multiple repeated warming/cooling cycles.
In order to obtain an accurate evaluation of the corneal endothelium.
2. Don mask, cap, sterile gloves, protective clothing and protective eye wear when examining the whole eye.
3. Remove eye jar lid and place it so that the inside of the cap is facing up in a clean area such as the hood or biosafety cabinet.
Prevents contamination of ocular tissue when lid is returned to eye jar.
4. Remove any excess liquid from eye jar.
Minimizes leakage on slit lamp biomicroscope and work area while evaluating.
5. Insert eye jar, vial, or corneal storage viewing chamber into utility clamp or other appropriate device.
This secures the ocular tissue while performing the evaluation.
6. Using sterile cotton-tipped applicators, gently manipulate eye cage, if one is used, to bring cornea within viewing range of slit lamp. Sterile forceps or hemostats can also be used instead of cotton-tipped applicators.
The contents of the eye jar are assumed to be sterile. Using sterile instruments during examination will ensure sterility is maintained.

-
-
7. Moisten the eye with sterile ophthalmic irrigating solution as necessary.
This prevents excessive drying and possible contamination of corneal epithelium.
 8. Perform a low power examination first at 10 X magnification when evaluating an eye/cornea for the first time.
This gives orientation and location and entire view of cornea and eye simultaneously.
 9. Diffuse illumination of the cornea is done with a wide slit of light directed on the cornea at approximately a 15° to 20° angle of incidence and then moved to scan the entire cornea.
To properly evaluate and see endothelium, the angles indicated must be observed.
 10. Next perform direct focal illumination using high power examination to perform an in-depth evaluation of the cornea. Adjust the width of the beam; a narrower slit beam will allow more in-depth examination and detail. With specular reflection you can observe the endothelium, cell morphology, dark areas, and areas where the cells are absent.
Corneal endothelium is a good indicator of the quality of ocular tissue. Anything other than normal hexagonal shaped cells should be noted and documented.
 11. Make notations on the donor information form regarding the evaluation and what was observed during initial evaluation.
After preserving ocular tissue, the initial evaluation may differ from final evaluation.
 12. Record and diagram any abnormalities present regarding epithelium, stroma, and endothelium. Bowman's layer and Descemet's membrane are not necessarily visible with slit lamp examination.
It is important to record quality of ocular tissue when determining whether it is suitable for surgery.
 13. Evaluate and record the minimum information below:
 - A. Corneal clarity, noting any scars, edema, or significant arcus that would reduce the optical clear zone needed by the transplanting surgeon
 - B. Folds or striae, noting severity, i.e., 0, 1+, 2+
 - C. Presence or absence of epithelial defects, and amount
 - D. Presence or absence of guttate change and amount
 - E. Presence or absence of stretch striae
 - F. Presence or absence of polymegathism or pleomorphism and amount
 - G. Evidence of any technical problems in removal
 - H. Presence of any infiltrates or foreign bodies
 14. Assign a rating to the ocular tissue, such as excellent, very good, etc., according to your eye bank's policy and rating scale. The classification used in the rating scale should be defined in the eye bank's procedure manual.
Slit lamp evaluation of the cornea following removal from the eye and placement into tissue culture medium is mandatory and must be performed and recorded. See EBAA Medical Standards section F1.200

Corneal Excision





*Excised donor cornea in the slotted lucite dish.
(from Max Fine, 1908-1989, Mannis, History of Keatoplasty
(From Max Fine, 1908-1989, Lanier, J.D., Webster, R.G., in Mannis, M.J. and Mannis, A.A.,
eds. Corneal Transplantation: A History in Profiles, J.P. Wayenborgh, Belgium, 1999)*

Corneal Excision

After the globe is received in the eye bank, the cornea with its scleral rim is removed and preserved. The sclera may also be preserved at this time. In-situ removal is very similar. Each eye bank, depending on their retrieval routines and locations will have an individualized protocol for in-situ removal. The principles are the same and combine the preparation phase of the enucleation procedure with the corneo-scleral rim excision procedure.

The excision begins with preparation of the sterile field, hood, media and transport containers (eye jars or similar). The globes are irrigated while in their transport containers. The technician then scrubs and gloves in a standard operating room fashion. An impermeable sterile wrap (such as sterile aluminum foil) is used to hold the container while the globe and cage are removed from the jar. The globe is then wrapped with a sterile 4x4, and the gauze secured with a hemostat.

A scalpel blade is then used to scrape any conjunctiva from the limbus and subsequently discarded as contaminated. A trephine may be used to mark a cutting line for the scleral rim. A new sharp-pointed scalpel blade is used to incise the sclera 2-3mm posterior to the limbus without penetrating the choroid (Figure 11a). With a curve tipped scissors the sclera can then be cut around the circumference of the scleral rim (Figure 11b). Care must be taken not to penetrate and cause a vitreous leak or physically damage the cornea while completing the incision.

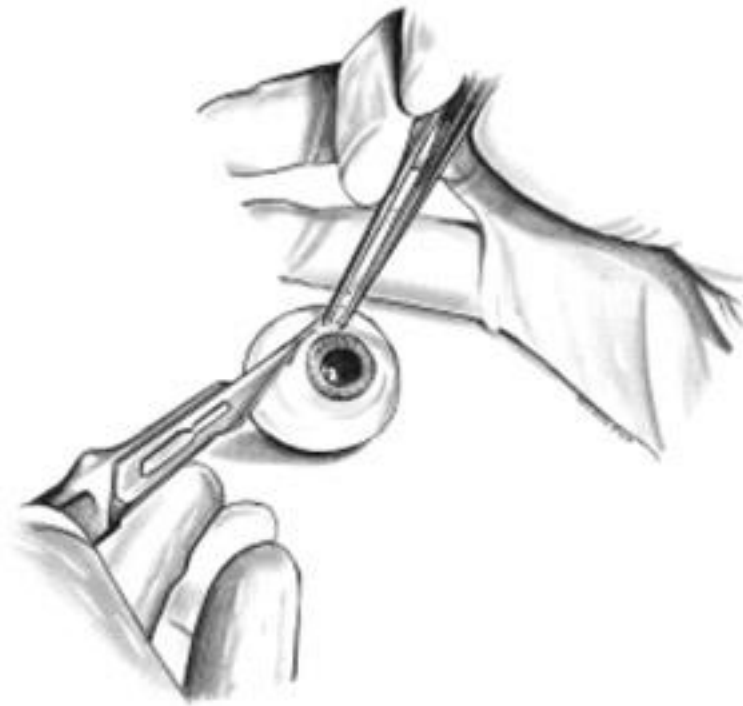Using a toothed forceps to hold the corneo-scleral rim, the ciliary body, choroid, and other posterior structures are very carefully pushed away and separated from the corneo-scleral rim at the scleral spur (Figure 11c). Extreme care must be taken not to bend, fold or stretch (stress) the cornea. The corneo-scleral tissue may then be placed in a corneal storage and viewing chamber (CSVC) filled with media or placed in a sterile container filled with preservation media (Figure 12). This is repeated for the second globe using new instruments that have not touched the conjunctiva. The tissue must be appropriately labeled including which eye, right or left, is in the container. The posterior globe should be examined for whether a lens or a lens implant is present, or whether a lens is absent (aphakia).

The sclera can be preserved in alcohol or other media by removing remnants of the conjunctiva, Tenon's, the nerve and any of the internal structures. Separate protocols are available to explain this procedure in depth.

Corneal Cap Removal.

The sclera is incised tangentially with a scalpel blade (a). Scissors are then used to cut the sclera (b). The cap is lifted with care, and the ciliary body teased posteriorly, avoiding any buckling of the tissue (c).

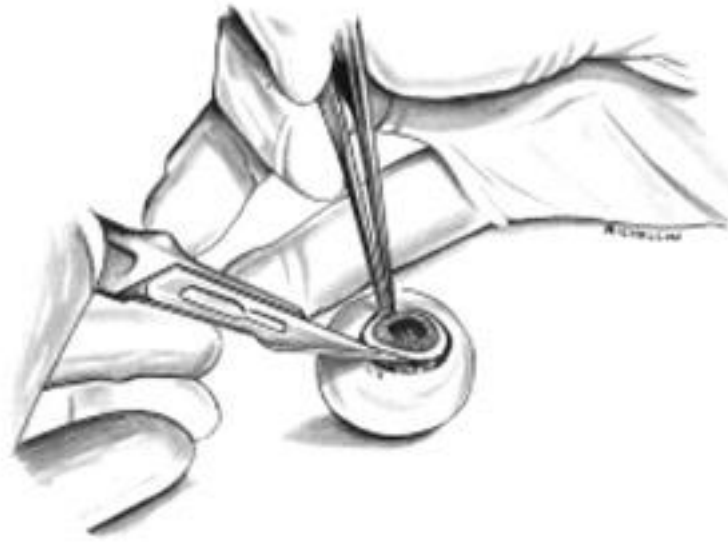(Figures 11)



(Figure 11a)



(Figure 11b)



(Figure 11c)



Media vial

The sterile media and its vial can used to store the corneal cap, or to fill the corneal storage and viewing chamber.
(Figure 12)

EBAA Laboratory Corneal Excision Protocol

E1.220 Laboratory Corneal Excision

Purpose:

To provide a standardized method for the aseptic preservation of corneal tissue in the laboratory that will minimize endothelial cell loss and contamination and maximize the number and quality of cells that are ultimately grafted.

Materials needed:

Sterile Supplies

- Sterile gown or sleeves
- Sterile gloves
- Sterile scrub brush for scrubbing hands
- 1 sterile towel
- Sterile ophthalmic irrigating solution
- Sterile ophthalmic broad spectrum antibiotic
- 2 vials corneal storage medium
- 2 mini tipped cassettes (if cultures are performed by the eye bank)
- Sterile cotton-tipped applicators
- Sterile gauze
- Jars containing whole eyes
- Class 100 Hood or Class II or Class III Biosafety Cabinet or an operating room

Appropriately wrapped sterilized instrument tray containing the following:

- 2 Small toothed forceps
- 2 Scalpel handles
- 2 #11 or #15 blades
- 1 Corneal section scissors, or Castroviejo or Aebli scissors
- 2 Tenotomy or iris scissors
- 1 Hemostat
- 1 Forceps to handle cages and/or solution bottles
- 2 Medicine cups or other small 30 cc glass/steel container

Non-Sterile Supplies

- Moisture impermeable protective clothing
- Mask
- Cap to cover hair
- Protective eyewear (goggles or face shield)
- Slit Lamp
- Evaluation Form

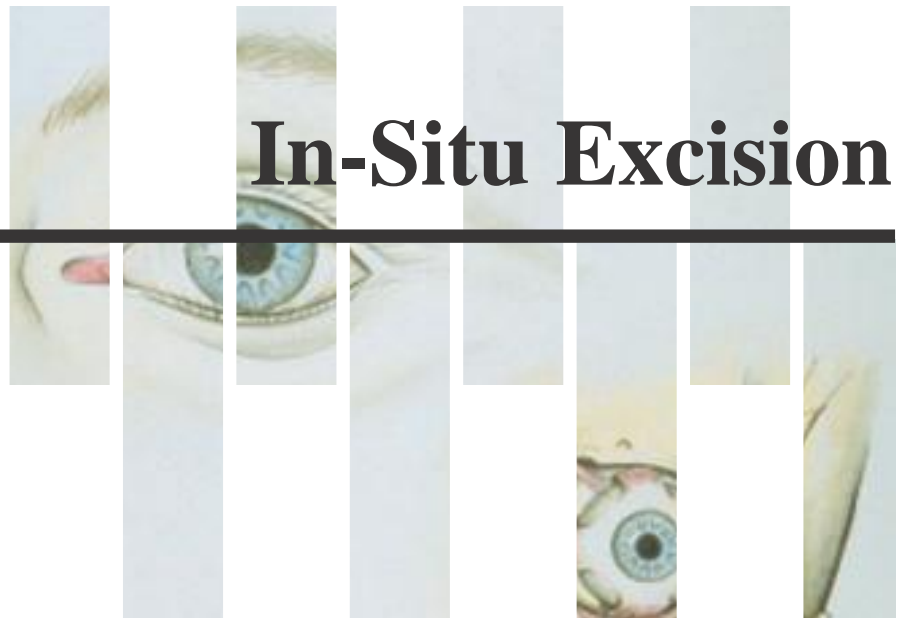Procedure with Rationale in Italics


1. Perform the corneal removal (excision) in the laboratory in a Class 100 Hood or Biosafety Cabinet following a whole eye enucleation. Wipe down and air dry the work surface of the hood or cabinet with a disinfectant solution immediately prior to use. Turn on laminar airflow of hood and allow to run at least fifteen according to manufacturers' instructions prior to use.
2. Don appropriate protective apparel consistent with the biological safety cabinet being used. *Use of a biosafety cabinet with a plexiglass shield protects the technician and tissue. Therefore, protective eye wear and mask in particular may not be necessary. However, if tissue is opened outside of the hood, e.g., while slit lamping the whole globe, full protective apparel is still required.*
3. Place sterile instrument pack, eye jars, antibiotic solution, and labeled corneal storage medium vials on the prepared surface of the laminar airflow work surface.
4. Position the eye jars so that they are immediately adjacent to the edge of the sterile field formed when the sterile instrument pack is opened. The eye jar lids are removed and placed with inner side up next to their respective jars. The labeled storage medium vials are positioned so that they also will be adjacent to the sterile field, Remove the caps of the vials. Position eye jars and medium vials to ensure that left and right specimen bottles are clearly and readily identified.
5. Uncap a 10 cc bottle of broad range sterile ophthalmic antibiotic solution or a povidone-iodine solution container and place near the eye jars and medium vials, according to your eye bank's policy. *Antibiotic or antiseptic application to the whole eye prior to corneal excision reduces themicrobial population. (Povidone-Iodine 0.5% solution has demonstrated effectiveness as an anti-fungal agent.*
6. Set up the sterile field by opening the outer and then inner wraps of the sterile instrument tray (if two wrappers are used). Alternatively, a sterile moisture impermeable barrier drape may be opened and placed on the work surface of the laminar airflow hood or cabinet, followed by opening sterile instruments in peel packs and dropping them on. Avoid contaminating the sterile field created by touching or reaching over the field. Open individually wrapped sterile items, such as gauze or sterile cotton-tipped applicators and flip onto the sterile field with the surgical instruments.
7. Scrub three to five minutes according to procedure E1.050. Dry hands with a sterile towel. Don sterile gloves and gown or sleeves. Double glove if this is your eye bank's policy.
8. Fold a sterile 4 x 4 gauze sponge to form a long strip. *This is used to hold the eye during the corneal removal.*
9. Lift the eye and the eye cage, if one is used, from the eye jar with sterile forceps (or the cage with a sterile cotton-tipped applicator.) Remove the pin if one is in place from the optic nerve with a hemostat. Remove the eye from the cage using forceps to grasp a rectus muscle.

-
-
10. Soak or irrigate the eye using an antibiotic solution for 3 to 5 minutes in a sterile medicine cup according to your eye bank's procedure. Avoid contaminating the sterile field by wetting of a cloth drape, if one is used. Irrigation should be performed over a metal instrument pan or a moisture impermeable drape.
Studies have shown that whole globe immersion is superior to irrigation for removal of microbes (see reference list.)
 11. Wrap the eye securely with the gauze strip several times around the equator.
To prevent strike through contamination of the sterile field.
 12. Lift and cut any remaining conjunctiva at the limbus and extending out 5 mm from the limbus using small toothed forceps and iris or tenotomy scissors. The exposed sclera may be carefully scraped from the limbus outward with a scalpel blade (#11 or #15) to remove all remaining conjunctival tissue. It is important to remove all conjunctiva flush at the limbus.
To remove microbial contaminants that may be present on the conjunctival tissue.
 13. The instruments and blade used to remove the conjunctiva should be isolated from the other instruments on the sterile field and should be used only to remove the conjunctiva on the opposite eye.
These instruments are contaminated since they have touched the "dirty" conjunctiva.
 14. Pick up the gauze-wrapped globe and hold with one hand.
 15. Make an incision through the sclera 2 mm - 4 mm from the limbus and parallel to the limbus approximately 5 mm in length using a second scalpel with a #11 or #15 blade and small toothed forceps. Carefully cut all the way through the sclera without perforating the choroid.
Perforation of the choroid causes vitreous leakage, which may collapse the globe including the anterior chamber. This would compromise the corneal endothelium.
 16. Extend the scleral incision 360° around the cornea using corneal section scissors (Castroviejo or Aebli). Avoid perforating the choroid, breaking into the anterior chamber, or causing any deformation of the cornea's normal curvature. The scissors should not be visible in the anterior chamber.
*Trauma to the cornea during cutting due to bending, loss of the anterior chamber, or collapse of the globe through vitreous loss would severely compromise its suitability for surgical use. Keep the incision parallel to the limbus to produce an even scleral rim between 2 mm and 4 mm in width.
Scleral rim width is important because some surgical corneal holding devices require a minimum 2 mm rim while other devices require a rim no wider than 4 mm. Also, cutting a rim less than 2 mm wide greatly increases the chance of entering the anterior chamber while performing the peritomy.*
 17. Inspect to be certain the incision is complete and that the anterior chamber is intact. If the incision has been made properly, the corneo-scleral button should be attached to the ciliary body-choroid only at the scleral spur.
The risk of endothelial trauma and cell damage is greatest at this stage of the excision process.

-
-
18. A culture of the incision site may be performed at this time, per your eye bank's policy.
 19. Set the wrapped eye down near the center of the sterile field which may be stabilized by attaching a sterile hemostat. Complete the corneal removal using one pair of the small forceps to hold the scleral rim stationary and a second set of small forceps, an iris spatula or back of a scalpel blade to push the ciliary body-choroid downward and away from the corneo-scleral button. Gently pull away remaining adhesions from the corneo-scleral button working side to side. The corneo-scleral rim must never be pulled in such a way as to cause cross corneal tension. The corneo-scleral rim should never be allowed to drop back down onto the anterior chamber.
To avoid pulling on the cornea and creating folds. Aqueous fluid should escape from the anterior chamber at this point assuring that the anterior chamber was indeed intact. To avoid stretching or damage to the endothelium.
 20. Continue to hold the cornea by the scleral rim with the small toothed forceps and transfer it to a labeled vial of storage medium from which the caps have already been removed.
The vials may remain open under the laminar airflow hood or biosafety cabinet for a period of 1 hour, which is acceptable operating room practice.
 21. You may examine the posterior chamber for crystalline lens.
Inspect for signs of previous cataract surgery, which would possibly contraindicate use of the corneal tissue for penetrating keratoplasty, depending on your eye bank's policy (See E B A A Medical Standards (D1.120).
 22. Carefully unwrap and return the remaining posterior segment to its respective eye jar.
Avoid contaminating the posterior segment, instruments, or surgical gloves.
 23. Repeat the procedure on the second eye.
 24. After the second cornea is placed in storage medium, replace both vial caps and tighten. Replaced the lids on the eye jars. The vials containing the ocular tissue are immediately labeled and sealed and the tissue refrigerated.
See procedures I1.000 and J1.000
 25. Instruments and eye jars are immediately cleaned according to your eye bank's policy and procedure. Discard all disposables in a biohazard receptacle.
See procedure C3.300.
 26. Immediately after use, wipe down the work surface of the hood with a disinfectant and to dry. Document these cleaning procedures according to your eye bank's policies and procedures.
See EBAA Medical Standards C3.300.

In-Situ Excision





Franceschetti's mushroom graft trephine. The cross-section of the tissue trephined from the donor was similar to that of a button mushroom. (From B.W. Rycroft, Corneal Grafts, Mosby Inc, 1955. Reprinted with permission.)

(From Photo Museum, Rosenwasser, G.O.D., in Mannis, M.J. and Mannis, A.A., eds. Corneal Transplantation: A History in Profiles, J.P. Wayenborgh, Belgium, 1999)

In Situ Excision

In-situ excision is useful in situations where the eye bank or its processing technicians are geographically located close to the donors. The enucleation of the entire eye is unnecessary, but highly skilled technicians are required.

EBAA In-Situ Removal Protocol

E1.200 Corneo-scleral Rim Removal: In situ

Purpose:

To provide a standardized method for the aseptic in situ removal of corneal tissue for surgical use that will minimize endothelial cell loss and contamination, and maximize the number and quality of cells that are ultimately grafted.

Materials needed

Skin prep tray, povidone-iodine or other microbicidal solution and sterile 4 x 4's or

Sterile ophthalmic irrigant solution, such as sterile saline

Sterilized appropriately wrapped instrument tray to include the following:

1 Lid speculum

2 Forceps with teeth

2 Pair of iris or tenotomy scissors

2 #11 or #15 blades

1 Corneal section scissors, Castroviejo scissors, or Aebli Scissors

1 Pair of forceps to handle lids of medium (optional)

2 vials of corneal tissue culture preservation medium

2 single fenestrated drapes or one double fenestrated drape, or sterile towels

Cultures or other items specified by your eye bank if culturing of the corneo-scleral rim at time of removal is desired.

Procedure with Rationale in Italics

1. All donor preparatory and pre ocular tissue recovery procedures should be performed according to procedure E1.050.
2. Some eye banks may perform a culture at the time of procurement. Please refer to section G1.000 and your eye bank's policy for specific direction about cultures .
3. Label the corneal storage media vials, loosen the caps to the top thread, and place these adjacent to a top corner of the sterile field.
Take care in the positioning of the storage medium vials to avoid accidentally knocking over the vials while reaching for instruments if they are at the bottom of the field or contaminating the field by reaching over if they are at the top of the field.
4. If required by the coroner or medical examiner, label test tubes for blood and vitreous samples and position near the sterile field along with the syringe, needle, and cosmetic restoration materials.

-
-
6. Open the eyelid using a sterile cotton tipped applicator or small toothed forceps and insert a solid blade eye speculum. If forceps are used to insert the speculum, isolate these from the other surgical instruments on the sterile field and use them only to open the eyelids of the second eye. *The forceps used to open the eyelid has been in contact with the skin and may introduce contaminants into the eye.*

 7. Lift and cut the conjunctiva at the limbus 360° around the cornea using small toothed forceps and iris or tenotomy scissors. Any adhesions between the conjunctiva and the anterior globe are separated so that the conjunctiva is not in contact with the anterior globe to within 5 mm of the limbus. If necessary, make several relaxing cuts in the conjunctiva radially to accomplish this. Remove any remaining conjunctiva by carefully scraping from the limbus with a scalpel blade (#11 or #15). *The conjunctiva tissues should be considered contaminated with microorganisms. Therefore it is necessary to completely remove the conjunctiva at the limbus.*

 8. Isolate the instruments and scalpel used to scrape the conjunctiva from the other instruments on the sterile field. Use these only for the same purpose on the opposite eye. *The conjunctiva is considered a contaminated membrane. Use of this same blade would introduce microorganisms into the incision area.*

 9. Make an incision through the sclera 2 mm - 4 mm from the limbus and parallel to the limbus approximately 5 mm in length using a second scalpel with a #11 or #15 blade and small toothed forceps. Care must be taken to cut all the way through the sclera without perforating the choroid. *Perforation of the choroid leads to vitreous leakage, which may cause collapse of the globe including the anterior chamber, resulting in endothelial cell damage. Additionally, vitreous leakage would make cosmetic restoration more difficult.*

 10. Insert the blades of the corneal section scissors (or Castroviejo or Aebli) into the suprachoroidal space. Perform a peritomy to complete the scleral incision 360° around the cornea. Avoid perforating the choroid, breaking into the anterior chamber, or causing any deformation of the cornea's normal curvature. *Trauma to the cornea during excision due to bending, loss of the anterior chamber, or collapse of the globe through vitreous loss would severely compromise the corneal endothelium and therefore its suitability for surgical use.*

The blades of the scissors should not be visible in the anterior chamber.

This indicates that the anterior chamber has been inadvertently entered, which may damage the corneal endothelium.

Keep the incision parallel to the limbus to produce an even scleral rim between 2 mm - 4 mm in width.

Scleral rim width is important. Some surgical corneal holding devices require a minimum of 2 mm rim while other such devices require a rim no wider than 4 mm. Also, cutting a rim less than 2 mm wide greatly increases the chance of entering the anterior chamber during scissoring.

-
-
11. After completing the incision, inspect to be certain it is complete and that the anterior chamber is intact. If the incision has been made properly, the corneo-scleral button should be attached to the uvea (ciliary body-choroid) only at the scleral spur.

The risk of endothelial trauma or corneal contamination is greatest at this stage of the excision process.

12. Cultures of the incision site may be taken at this time, per your eye bank's policy.
13. Complete the corneal removal using one pair of small forceps to grasp the scleral rim and hold it stationary and a second set of small forceps, an iris spatula, or back of a scalpel blade to pull the ciliary body-choroid downward and away from the corneo-scleral button.

Aqueous fluid should escape from the anterior chamber at this point assuring that the anterior chamber was indeed intact.

14. Gently separate remaining adhesions away from the corneo-scleral button working side to side and taking great care to avoid pulling on the cornea and creating folds. The corneo-scleral rim should never be allowed to drop back down while making this separation. The corneo-scleral button must never be pulled in such a way as to cause cross corneal tension.

To avoid stretching or folds leading to potential loss of endothelial cells.

Care must also be taken to prevent the cornea from contacting the eyelids or other facial skin while removing it from the eye.

To avoid contamination of the ocular tissue.

15. Holding the cornea by the scleral rim with the small forceps, transfer it to a labeled vial of storage medium. The pre-loosened cap is lifted off the vial using sterile forceps immediately prior to placing the cornea in the medium and replaced immediately afterward. If forceps are not used, glove before starting on the next cornea.

Removing the vial cap at the time the cornea is placed in the storage medium minimizes the medium's exposure to airborne contaminants.

16. Examine the posterior chamber for a crystalline lens at this time.
To inspect for signs of previous cataract surgery which would possibly contraindicate use of the ocular tissue for penetrating keratoplasty per EBAA Medical Standards section D1.120, depending on your eye bank's procedure.

17. Repeat the excision on the second eye (Steps 1-15). After the second cornea is placed in storage medium, both vial caps are tightened and appropriately labeled.

18. Completion

A. Remove drapes.

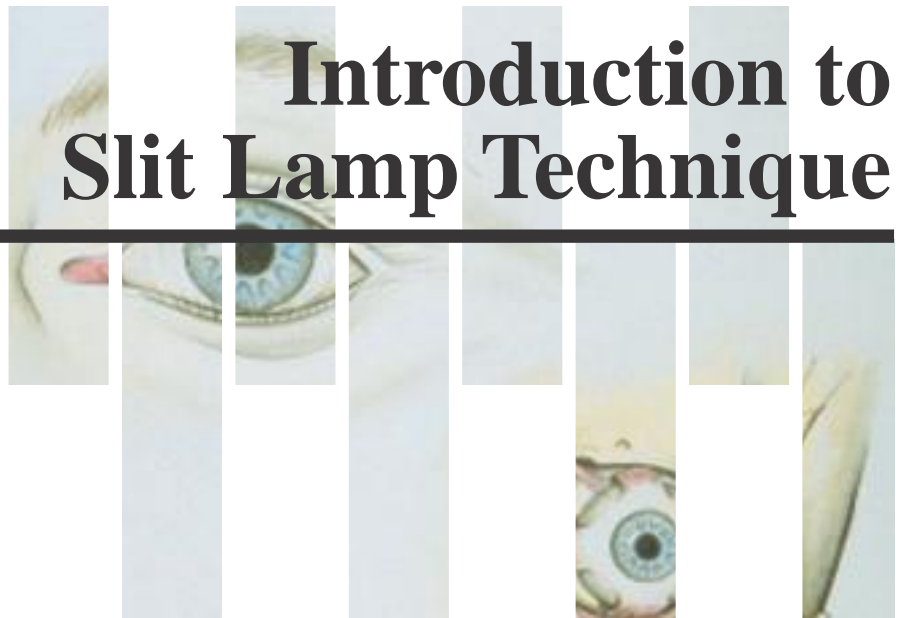
B. Insert eye caps. Close the eyelids and remove all remaining prep solution with gauze and water or alcohol .

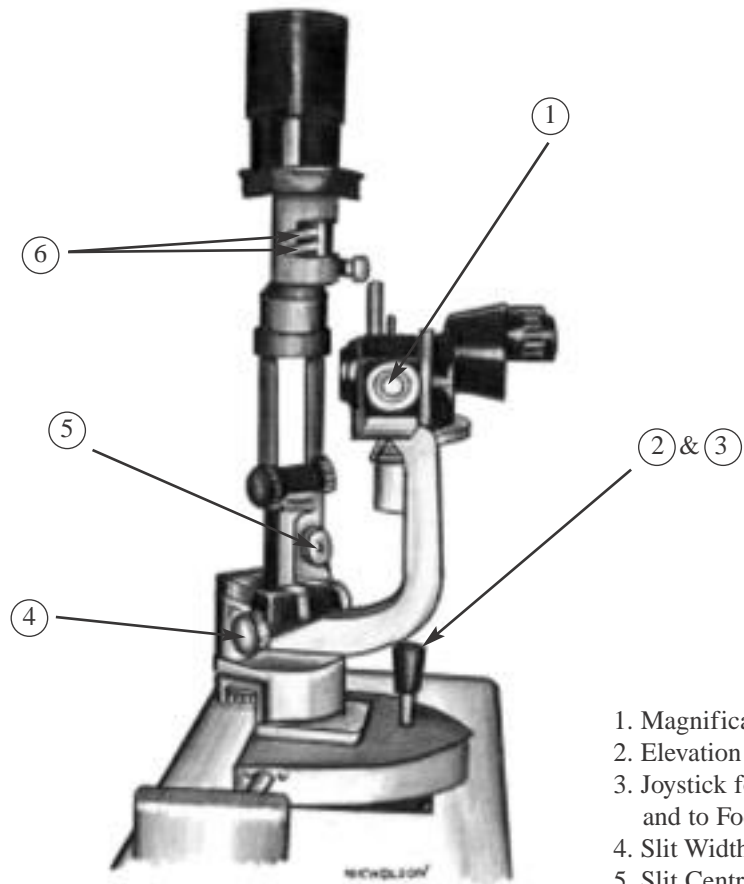
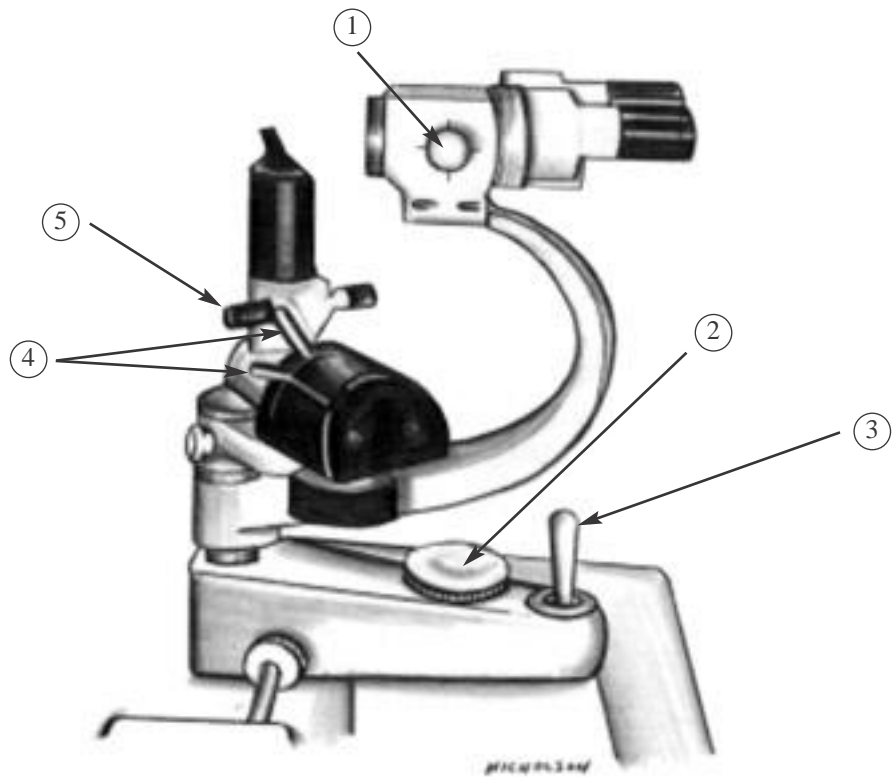
To restore the appearance of the donor.

-
-
- C. Leave the donor's head elevated.
 - D. Record information about the excision in the donor's medical record according to your eye bank's policy.
To fulfill JCAHO requirements on documentation of tissue and organ removal.
 - E. Complete the eye bank's excision form, as required.
 - F. Leave a form or attach a tag to the body informing the funeral director that the corneas have been removed and to keep the head elevated. Also give the eye bank's name, location, and phone number with instructions to notify the eye bank if there are any questions or problems.
As a courtesy to the local funeral director. Also, hopefully, the funeral director will notify the eye bank before discussing problems related to the eye removal with the family.
 - G. Don non sterile gloves and rewrap the donor in the body bag or shroud and return to the storage location from which it was removed.
 - H. Clean the work area. Discard all used disposables in a biohazard bag and all sharps in a sharps container.
 - I. Rewrap instruments for return to the eye bank or for cleaning and sterilization by the facility if that is your eye bank's protocol.
 - J. Transport the corneas to the eye bank as soon as possible.

NOTE: FOR INFANTS, AN INFANT LID SPECULUM AND EYE CAPS SHOULD BE USED.

Introduction to Slit Lamp Technique





- 1. Magnification
- 2. Elevation
- 3. Joystick for Right & Left Movement and to Focus
- 4. Slit Width and/or Height
- 5. Slit Centration or Offset
- 6. Slit Height and Intensity

*Slit lamps
(Figure 13)*

Slit Lamp Technique

The **slit lamp** is a low to medium power binocular microscope mounted to be used horizontally (Figure 13). Illumination is provided by a projected light which can be large and circular or narrowed down to a slit-like beam. The large **wide beam** can be used to survey all or most of the specimen (whole globe or corneal button). The beam is narrowed to give a beam as wide as the cornea is thick to form a **parallelepiped** volume (a box of illuminated tissue). The depth, width and position of small abnormalities can be evaluated with this. The beam can be further narrowed to form an **optical section** (so thin it's just discernible). This allows the smallest change in clarity to be evaluated, as well as pinpointing the depth of pathology. A short parallelepiped or the smallest circle projectable is used to perform **specular reflection**, the technique in which the endothelium is visualized. The light source usually has several or continuous levels of illumination. Medium to high illuminations are used for most purposes. High should be used in optical section and specular reflection. Several levels of magnification are usually available as well. Low power (~10x) is used for survey, medium to high (16-40x) for optic section and parallelepiped, and high (40x) for specular reflection. Normally the light is focused at the same point as the microscope. This configuration is described as parfocal. If it is not, the beam has been decentered or the oculars are not adjusted to their neutral position. Both situations are easily remedied. Check the instrument's manual for how to rotate the slit projector beam.

The slit lamp is mounted on a moveable stand. A joystick is used to move it right and left, as well as back and forth (focusing). The joystick or similar arrangement is used to raise or lower the slit lamp. The slit projector pivots around the microscope mount and can be swung 180° in front of the specimen. The beam can be projected tangential, perpendicular, or at any angle to the specimen. While performing an exam the light should be moved frequently, as the different angles at which the light hits the cornea may make pathology more obvious. **Direct illumination** (the beam directly pointed at the specimen) shows gross pathology, while **retroillumination** (the beam decentered to illuminate behind the area of interest while it is still in focus) may bring out subtle optical changes such as thin vascularization (blood vessels), small incisions, and endothelial abnormalities. **Sclerotic scatter** uses a beam ~1mm wide, half the height of the cornea, pointed at the limbus, to view subtle abnormalities. The light spreads by total internal reflection through the cornea and scatters off of any pathology.

How To Grade Donor Corneas





Needles of various sizes and manufacturers used in eye surgery.
 (From the collection of George O.D. Rosenwasser.)
 (From Photo Museum, Rosenwasser, G.O.D., in Mannis, M.J. and Mannis, A.A., eds. *Corneal Transplantation: A History in Profiles*, J.P. Wayenborgh, Belgium, 1999)



Evaluation of the Donor Cornea

The cornea should be examined systematically. Developing a protocol which addresses each layer of the cornea, the media, and the overall clarity is essential. Many incisions from contemporary cataract surgery are difficult to see. One method is to examine the sclera and then the corneal epithelium, stroma, Descemet's and endothelium. The preservation media needs to be observed in the preserved corneal specimens. The anterior segment and ocular media (aqueous and vitreous) should be examined in enucleated globes or during in-situ retrieval.

Conjunctiva

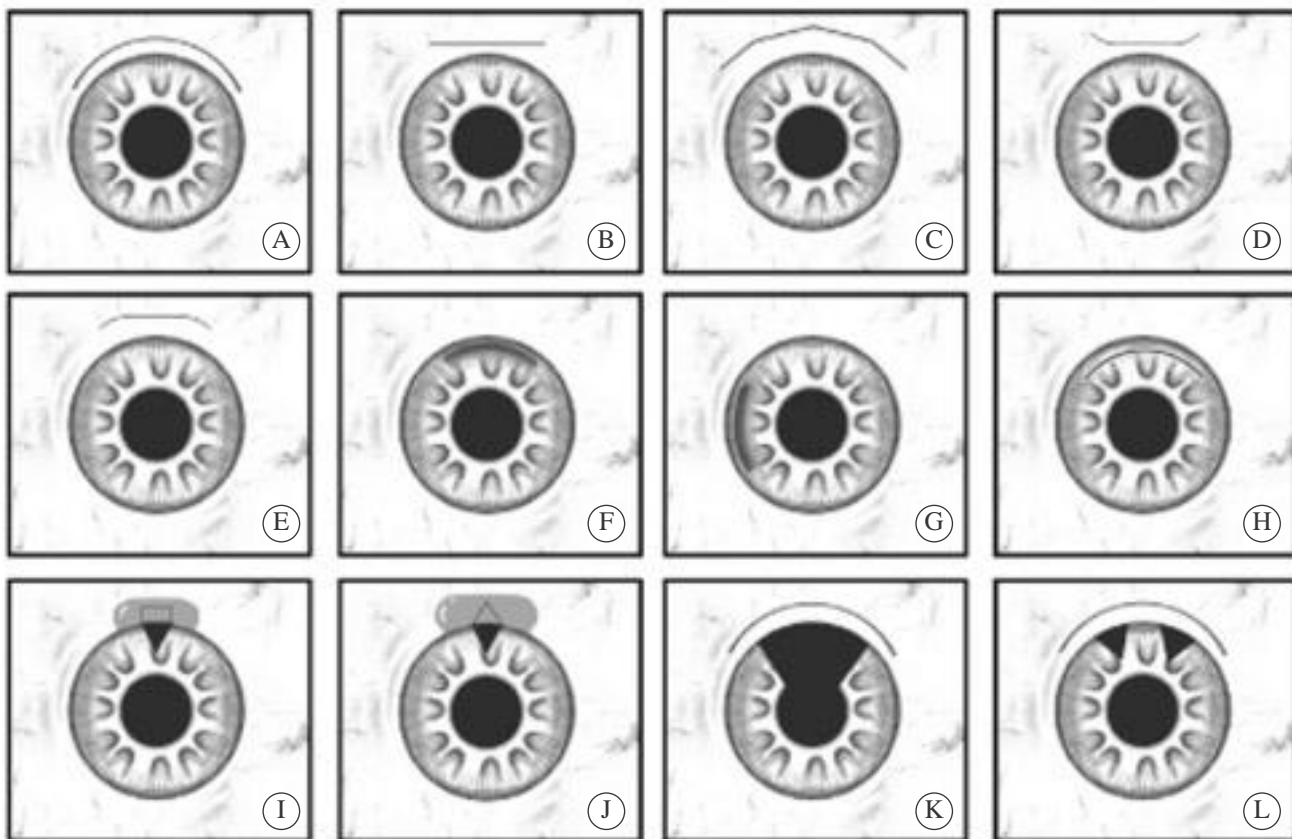
The conjunctiva is rarely present in any significant quantity in an enucleation specimen other than a thin rim around the limbus. Occasionally, a **pinguecula** (a thickened area of conjunctiva at the limbus but not crossing it) or a **pterygium** (thickened area of conjunctiva which does cross the limbus onto the cornea) may be present. During an in-situ removal the conjunctiva should be inspected for any other areas of thickening or irregularity which could represent a tumor. While these are infrequently seen, they are often located at the limbus when present.

Sclera and Surgical Incisions

The sclera is relatively simple from the evaluation standpoint. Color should be checked for **hemorrhage** and **icterus/jaundice**. Any foreign material or trauma should be documented. **Surgical incisions** will appear as **straight, frown shaped, chevron, or concentric** scars at or within 2-3mm of the limbus. Incisions may also be found in the clear cornea. If sutures are present they will be black, blue, or a faded grayish white, usually radial or “x” shaped. Surgical iridectomies associated with cataract or glaucoma surgery may appear to be “extra” pupils or extensions of the pupil. They may be single or multiple. An adjacent incision in the sclera (square triangular, semicircular, etc.) may mean that glaucoma surgery has been previously performed. Figure 14 shows a variety of incision and iridectomy examples.

Epithelium

The epithelium should be graded for clarity, edema, exposure, sloughing, trauma, pterygia, infiltrate and foreign material. The location and area of the abnormalities is important. Establish the area affected and express it as a percentage of the total area and state its location. Quantify and characterize the type of foreign material present. The epithelium may be **hazy** due to swelling of the cells. The haze may be generalized due to the conditions and length of time of preservation, or may be localized due to exposure. **Trauma** may interrupt the layer or remove some of the epithelium leaving a textured edge (ragged or smooth). If enough swelling of the cells occurs, the 4-5 layers of cells which make up the epithelium may detach, also known as **sloughing**. Occasionally, the edge of the detaching epithelium can be seen to be grossly elevated over the rest of the cornea. **Epithelial defects** can be seen as clear areas within an otherwise hazy layer of epithelium. They can always be confirmed by slit beam noting the discontinuity of the defect's edge. The area of the defect may look depressed when compared to the surrounding epithelium. **Pterygia** are a fleshy, tongue shaped, layer of conjunctiva crossing over the limbus and onto the cornea. They make the cornea appear thicker and are opaque on slit beam examination. An **infiltrate** is the appearance of inflammatory (white blood) cells seen as a grayish white discoloration in the epithelium alone, or may be continuous with stromal infiltrate. Document the size in area, location, and density. The depth of the infiltrate can be evaluated with the aid of the slit beam. If the infiltrate is dense and opaque it may obscure details below it in the stroma.



- | | |
|-----------------------------------|--|
| A. cataract extraction (CE) wound | G. temporal clear cornea CE wound |
| B. straight CE wound | H. alternate superior clear cornea CE Wound |
| C. "chevron" CE wound | I. trabeculectomy/CE wound with peripheral iridectomy (PI) |
| D. "smile" CE wound | J. alternate trabeculectomy/CE wound with PI |
| E. "frown" CE wound | K. CE with sector iridectomy wound |
| F. superior clear cornea CE wound | L. CE with multiple PI's |

(Figure 14)

Stroma

The **stroma** is a multilayered collagen structure that may swell with preservation or anything that causes an increase in water content. The swelling produces a lack of optical clarity often described as stromal haze. Endothelial cell dysfunction may also cause the stroma to swell with water. These cells normally act to pump water out of the stroma to keep it clear and compact. The presence of white cells causing opacity in the stroma is called an **infiltrate**. The infiltrate is a response to inflammation and/or infection. **Folds** and **striae** are also physical manifestations of the swelling. When fluid swells the stroma it may cause localized areas to change more than others. Since the diameter of the cornea is fixed, this swelling causes undulations called "**fold**s" of the stroma (Figure 15a).

One approach to grading the severity of the folds is to estimate the physical dimensions of the swollen and unswollen areas of the stroma (the peaks and valleys of the folds) as seen in Figure 15b. Set the slit beam at its thinnest visible width, and at 45° (swung midway between the cornea and the observer). Compare the height of a fold to the baseline thickness of the corneal stroma. Express this as a percent of the thickness of the cornea. For instance, if the fold is 1/4 of the

corneal stromal thickness, call it 25%. The thickest folds indicate the severity of the swelling, so find the thickest folds to grade.

Setting up a convenient scale we see that folds fall into one of five categories:

not present	no folds seen
trace folds	0-10% baseline
mild folds	11-15%
moderate folds	16-25%
severe folds	>25%

The greater the density and severity of the folds, the less transparent the tissue will be. Folds may be less prominent after storage, due to the osmotic effect of high molecular weight compounds added to some long term preservation media. The effect of the high molecular weight material is to draw the water out of the cornea. Likewise, the folds may be more obvious after storage in short term preservation media which do not include such high molecular weight compounds. An example of the different corneal grades is shown in the composite and individual illustrations in Appendix 1. The grades have been arbitrarily categorized as clear and compact, trace, mild, moderate and severe.

Striae may also be seen in the stroma. They appear as fine grayish white lines in the corneal stroma. They probably represent very localized separations of the highly ordered collagen. They can be graded by their presence and density.

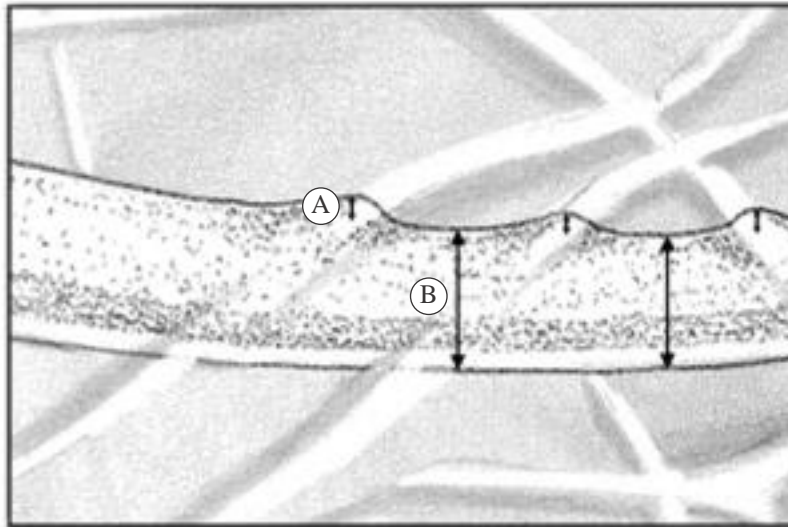
Arcus senilis is a term that describes a grayish white to yellowish deposit in the stromal periphery. This is due to a lipid (fat) like deposit that may increase with age. It may be present as a concentric circle of deposit, or may be present for several clock hours in opposite areas near the limbus. Make note of the location (describe by clock hours if not present everywhere), density, and size of the shortest length between the deposits. This will determine the diameter of the largest clear button of tissue that can be obtained from the donor.

Scars due to **trauma** are grayish white due to the disruption of the stromal tissue, the presence of fibrous tissue, and the scattering of light that occurs. Surgical scars are similar appearing, but fall into typical patterns:

cataract wound	external entry near limbus, internal wound ~ 1mm more central
radial keratotomy	radial lines, spoke-like in arrangement
arcuate keratotomy	arc shaped lines in the periphery
PRK (photorefractive keratectomy)	circular disc of haze in center of cornea
lamellar keratomileusis (LASIK, ALK)	circular or horseshoe shaped, partial stromal thickness
penetrating keratoplasty	circular, full thickness, ~6-9mm diameter, central, may have radial or continuous sutures, or scars from them, present



The formation of corneal folds (above) from thickening of the normal corneal stroma (below). The outer surface of the cornea prevents shape changes while the inner surface can react by thickening and folding.
(Figure 15a)

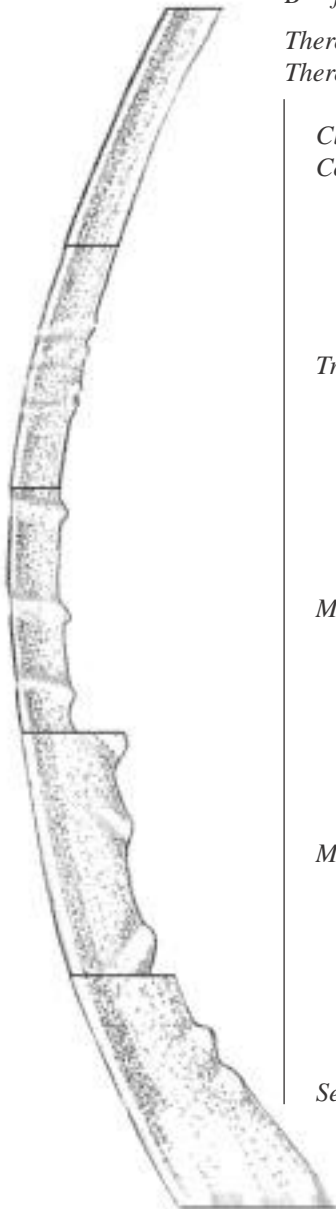


A = make this one unit for the height of the fold over the baseline

B = five units for the thickness of the corneal baseline

Therefore, A/B = the fold's proportion of corneal thickness.

Therefore, 1/5 = 0.2 or 20%, so the fold increases corneal thickness by 20% over baseline.



<i>Clear and Compact:</i>	<i>no folds seen</i>
<i>Trace:</i>	<i>0-10% of baseline</i>
<i>Mild:</i>	<i>11-15% of baseline</i>
<i>Moderate:</i>	<i>16-25% of baseline</i>
<i>Severe:</i>	<i>>25% of baseline</i>

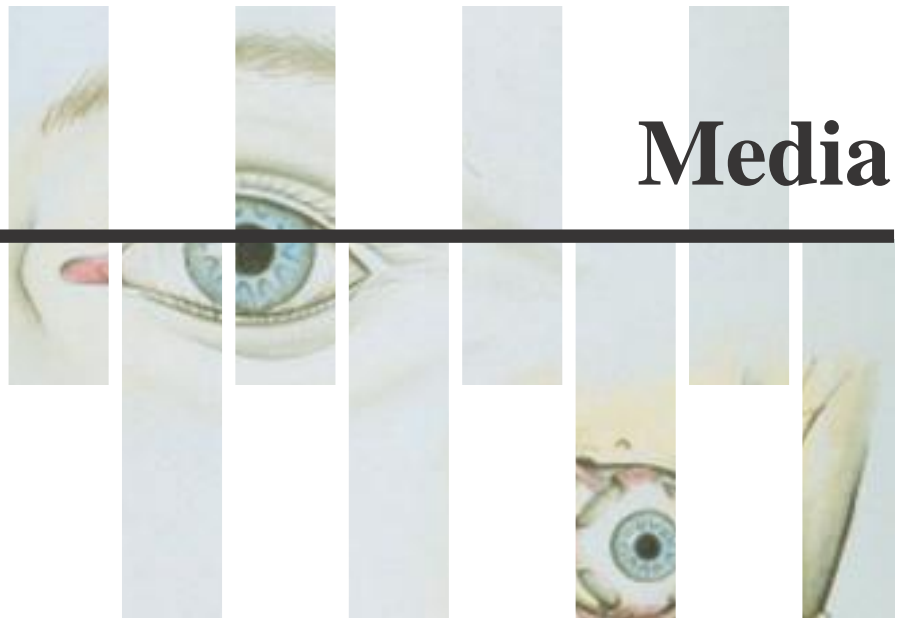
Approach to grading the severity of corneal folds. Sample calculation above and standardization scale for categorizing fold severity below.

(Figure 15b)

Descemet's Membrane and Endothelium

The deepest layer on the concave surface of the cornea is that of Descemet's and the endothelium. Normally it is optically clear. Descemet's membrane is a thin, tough, membrane between the stroma and the endothelial cell layer. Generally, Descemet's and the endothelium are seen together and not separately. The endothelium does not detach separately from Descemet's. Separation of Descemet's membrane and the endothelium from the stroma is called a **Descemet's detachment**. Slit beam examination will show a separate membrane that seems to come from the back surface of the cornea and is continuous with the endothelium and Descemet's. The location and percent of total corneal area should be reported. Occasionally, if very carefully examined at high power, the **endothelial cells** can be seen by **specular reflection**. **Guttae** (*You may also see the word guttatae, the incorrect plural, in common use. Gutta is the singular form*) can also then be identified as individual or multiple dark spots in the endothelial cell mosaic. These are localized enlargements (excrescences) of Descemet's membrane tissue. Each may be the size of one, several or a dozen endothelial cells. They may also be **isolated** (single) or **confluent** (multiple, side by side). A central concentrated area of guttae, becoming more diffuse in the periphery, generally indicate **Fuchs' endothelial dystrophy**. This dystrophy causes corneal thickening and decompensation, frequently requiring corneal transplantation. As such, use of this tissue is contraindicated. **Pseudoguttae** look like guttae while the tissue is at or near 4°C, but disappear at room temperature. Their origin is thought to be from endothelial swelling. **Snail tracks** and **stretch marks or striae** are terms given to **stress lines** that appear at the level of Descemet's and the endothelium. They are thought to be caused by traumatic stretching or folding of the cornea which causes detachment of the endothelial cells. Red blood cells (**RBC's**), precipitates of white blood cells (**keratic precipitates or KP**), pigment debris and particulate contaminants may all be seen on the endothelial surface. Depending on their shape and orientation they may be dark or bright when viewed by specular techniques.

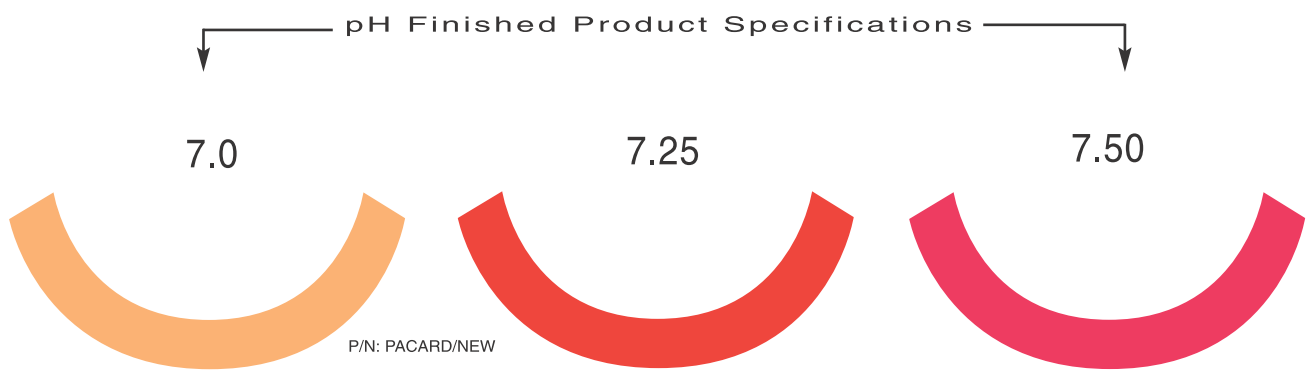Media



Optisol

Chondroitin Sulfate Dextran
Corneal Storage Media

pH Color Reference in Corneal Viewing chamber Only

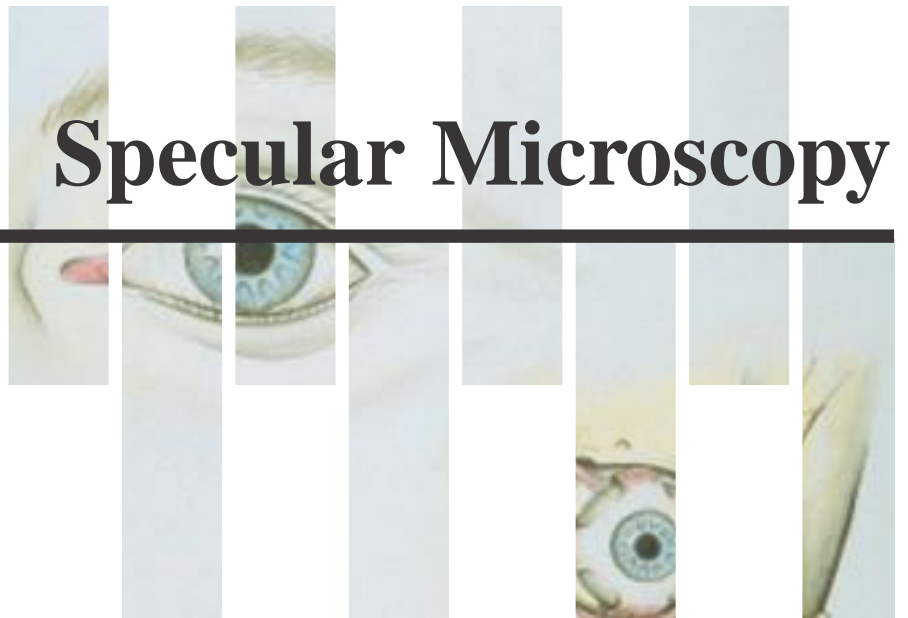



*The color chart shows the ranges of pH and corresponding colors.
(Figure 16)*

Media Evaluation

The color and clarity of the media should be observed. If the color is yellow rather than a light orange or pink, the media has a pH <7.0. This may indicate bacterial growth. Glove dust, blood, and other particulate materials may make their way into the media during harvesting or preservation. It is important to differentiate acceptable materials (e.g. non-adherent iris fragments) from foreign materials such as vegetable material, glass, sand or gunpowder. A color chart showing the ranges of pH and corresponding colors for Optisol® media is shown in Figure 16.

Specular Microscopy



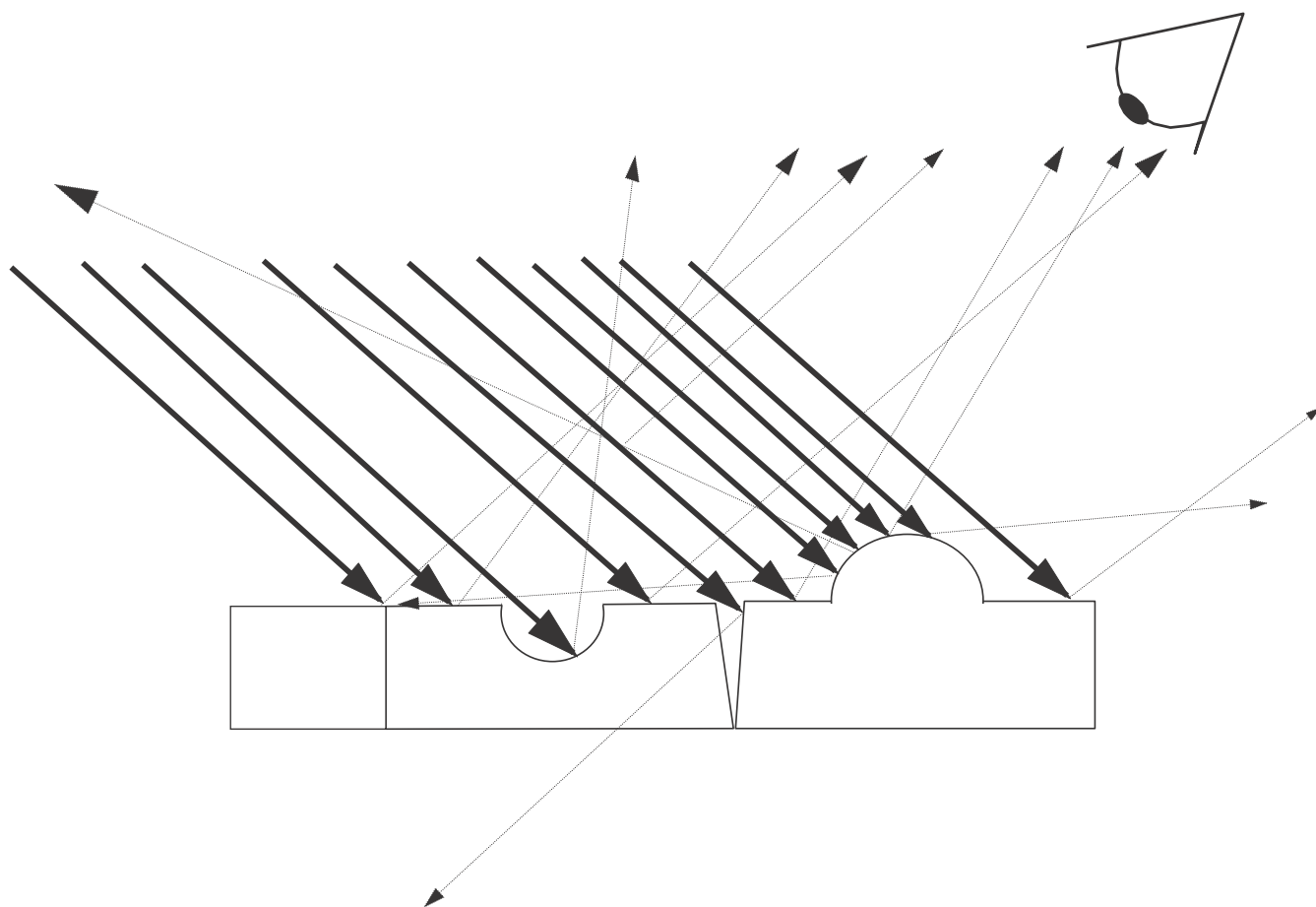


*The first laboratory specular microscope (courtesy of David Maurice)
(from photo Museum, Rosenwasser, G.O.D., in Mannis, M.J. and Mannis, A.A., eds. Corneal Transplantation:
A History in Profiles, J.P. Wayenborgh, Belgium, 1999)*

Specular Microscopy Basics

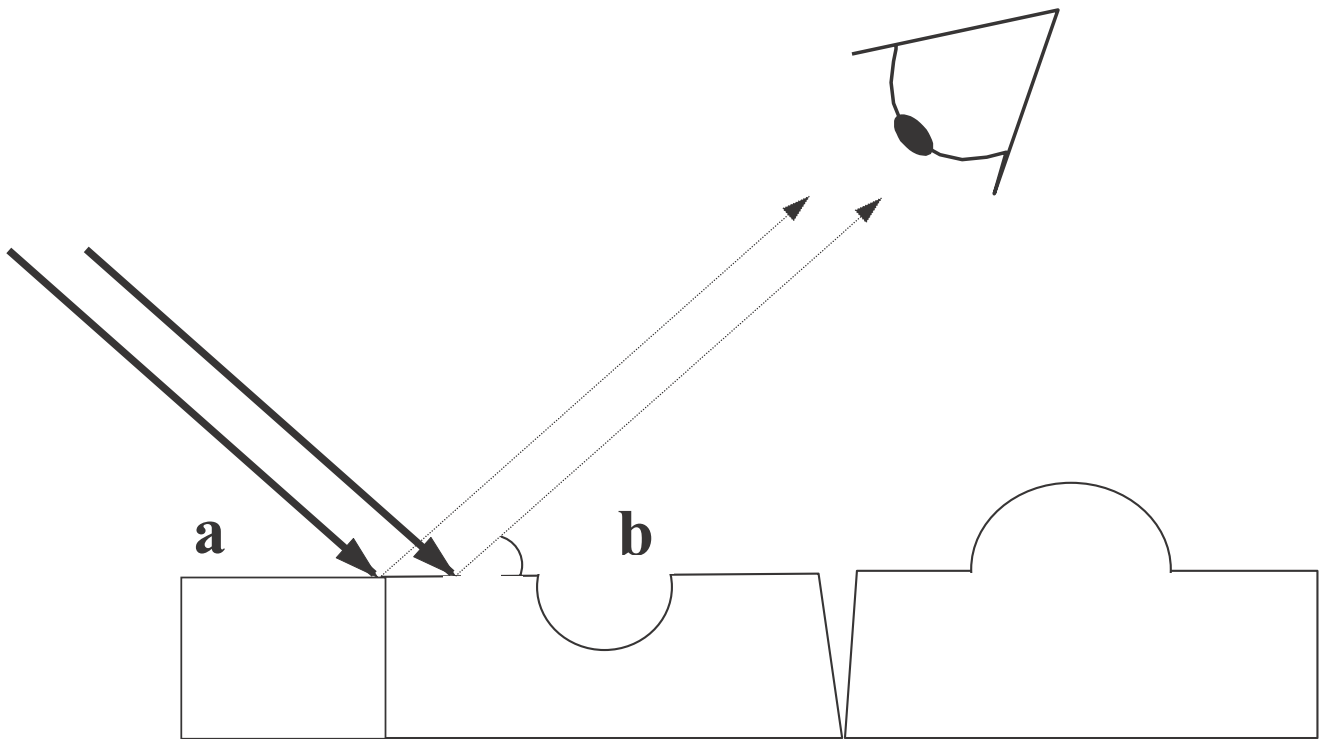
Since the endothelial cells are one of the most important structures in a donor cornea, their morphology and concentration must be carefully evaluated. This can be done at the slit lamp by a technique called specular reflection or with a specular microscope. Specular reflection refers to the viewing of objects that occurs when light is reflected from the interfaces of materials with different indices of refraction. This occurs in a mirror like fashion where the angle of incidence is equal to the angle of reflection. An endothelial cell is different in refractive index than the aqueous and also Descemet's. While most of the light goes through these two transparent layers, about 0.02% is reflected backward to form an image of these structures. The more regular and numerous the cells are, the better their function is thought to be. Tightly packed, hexagonal-shaped cells with little variation in shape and size are considered normal. Cell densities greater than 2000/mm² are generally accepted as suitable for transplantation.

The optics of specular microscopy appear unfathomable if viewed as a whole picture (below). By breaking down the optics to simple geometric surfaces, however, one can easily understand the principles.



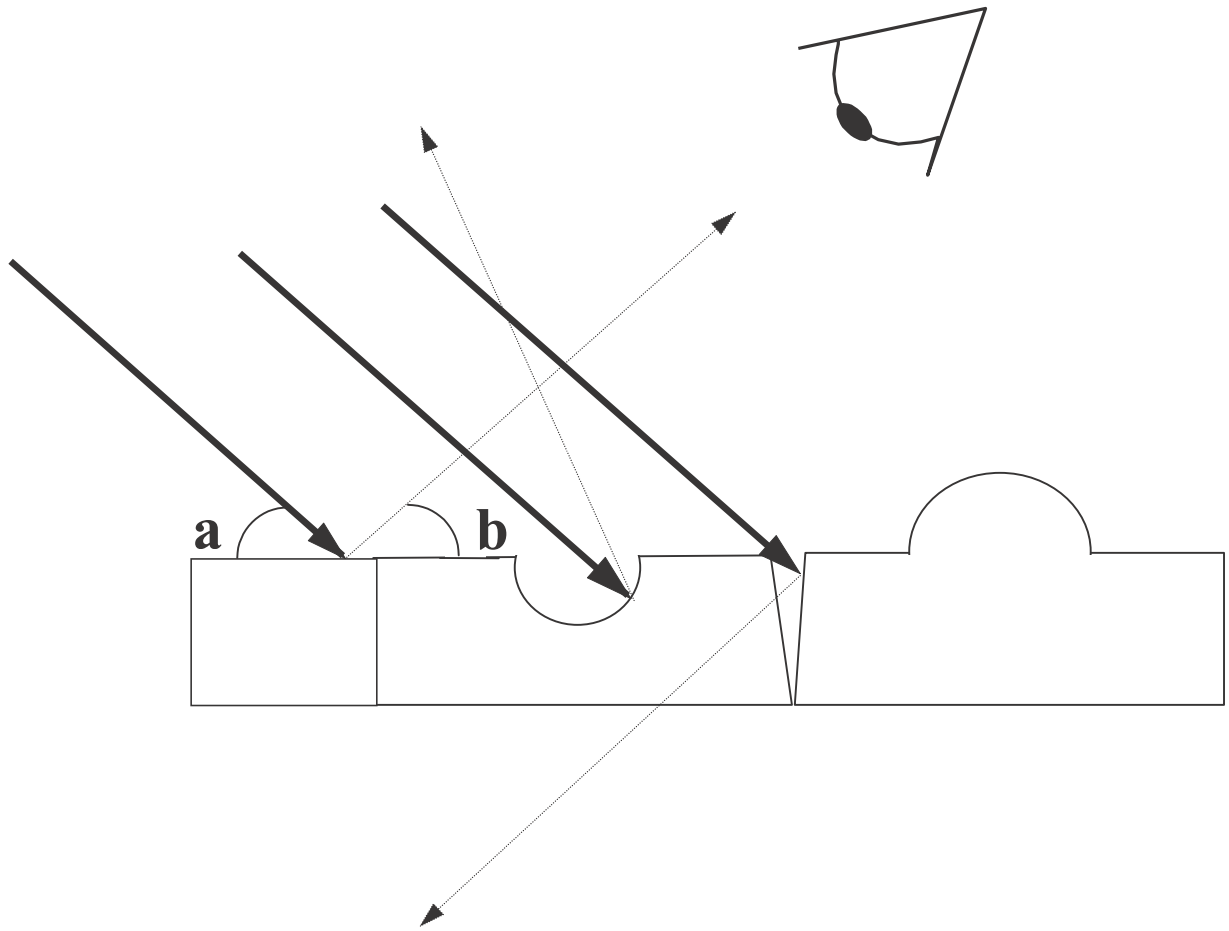
(Figure 17)

The flat surface which acts like a mirror is the easiest to understand. Light which strikes the surface (bold lines) at a particular angle is reflected from the surface (thin lines) at the same angle (angle a = angle b).

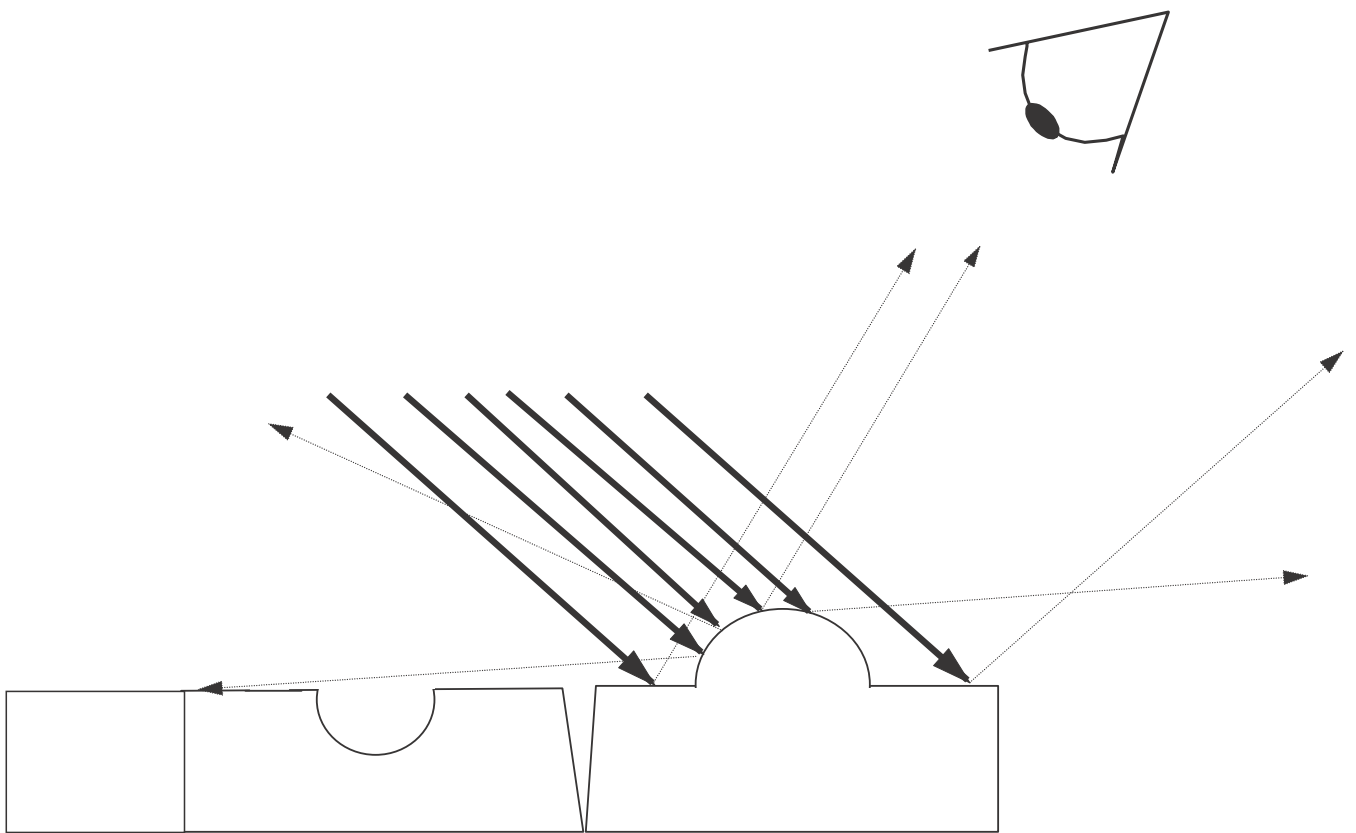


(Figure 18)

The light is reflected from concave and convex surfaces in a similar fashion. The difference is that much of the light is lost by reflecting in directions away from the viewing angle (dotted lines). The techniques of specular reflection and specular microscopes collect a narrow beam portion of the reflected light to avoid unwanted bright reflection, which would wash out the image. Besides the top of convex surfaces, the bottom of concave surfaces, and optically flat (mirror-like) surfaces, the structures appear dark. The top and bottom points may give rise to a central bright spot in these types of structures. If the surface is very irregular, the light reflections are relatively randomly distributed, making the surface appear gray. This is the average of many flat, concave and convex elements which make up the irregular surface.

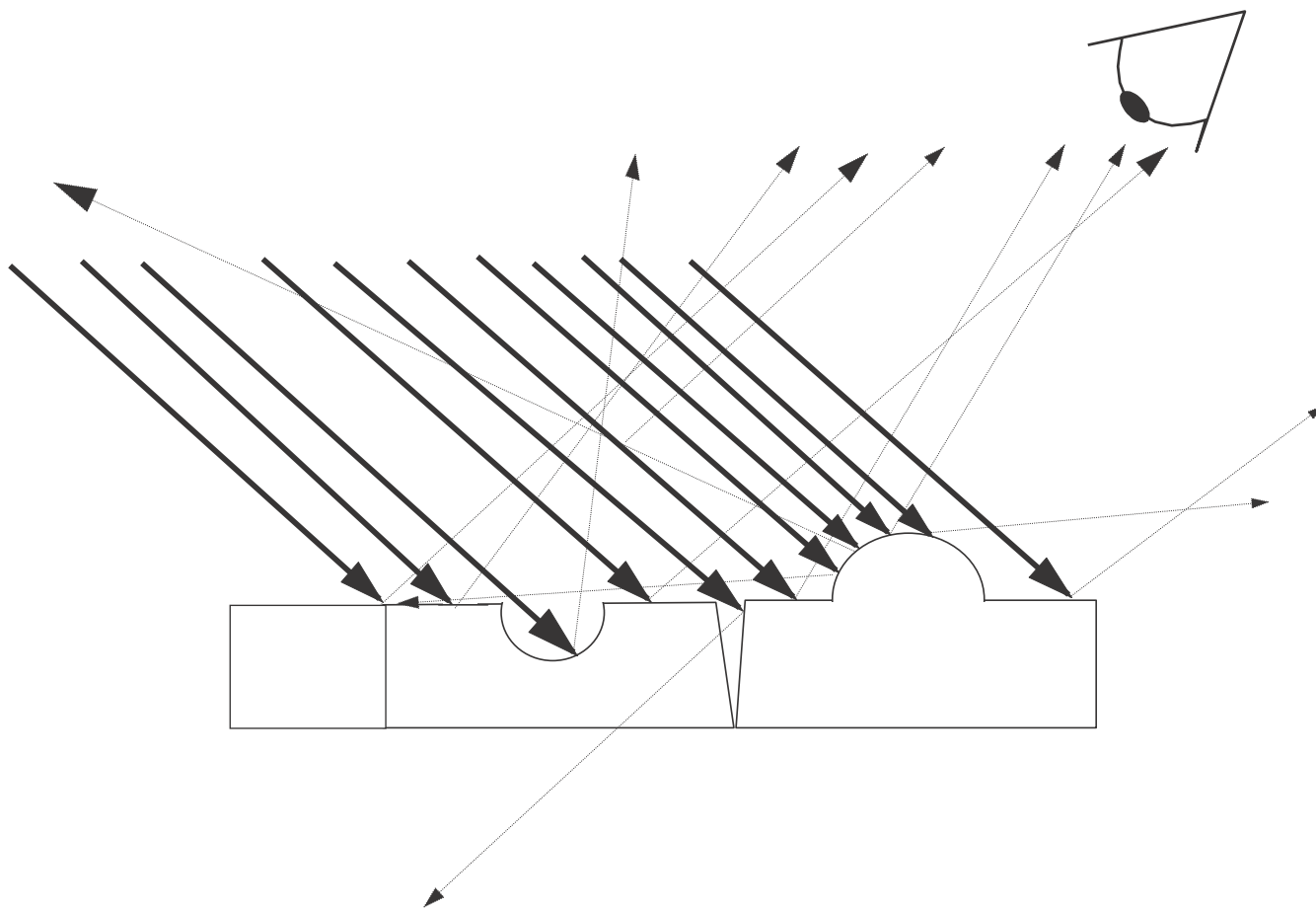


(Figure 19)



(Figure 20)

Putting all the components together we get a complete view of the surface. Note that many rays of light get reflected away from the observer by the irregularities in the surface, while a few from the flat, mirror-like areas, still reach the observer. This is what causes the light and dark areas in the specular microscopy images.



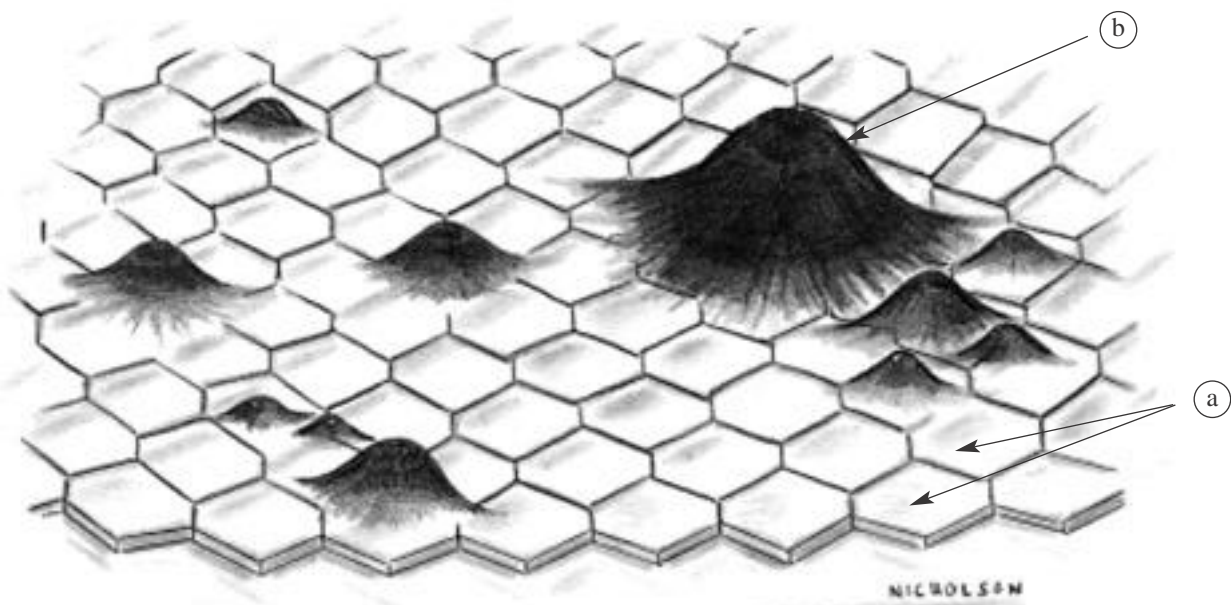
(Figure 21)

Viewing the cells by specular microscopy allows the evaluation for cell density, variation in size (polymegathism), variation in shape (pleomorphism) and other factors such as injury, inherent disease, and inflammatory or foreign material. Specular microscopic appearance of the cells varies with temperature, time of preservation, and media. Freshly preserved tissue at room temperature is most easily evaluated. Refrigerated tissue must be allowed to warm to room temperature to avoid condensation on the container and to allow cells to resume a near normal shape. Warming should not be rushed. The tissue should return to refrigeration as soon as possible.

The cornea should be evaluated as centrally as possible, since this is the area that will occupy the visual axis. Several systems are available to perform specular microscopy. A “back-up” method is to perform it with a slit lamp. Estimates are based on counting 4-5 fixed 0.01mm² frames or approximately 100 cells.

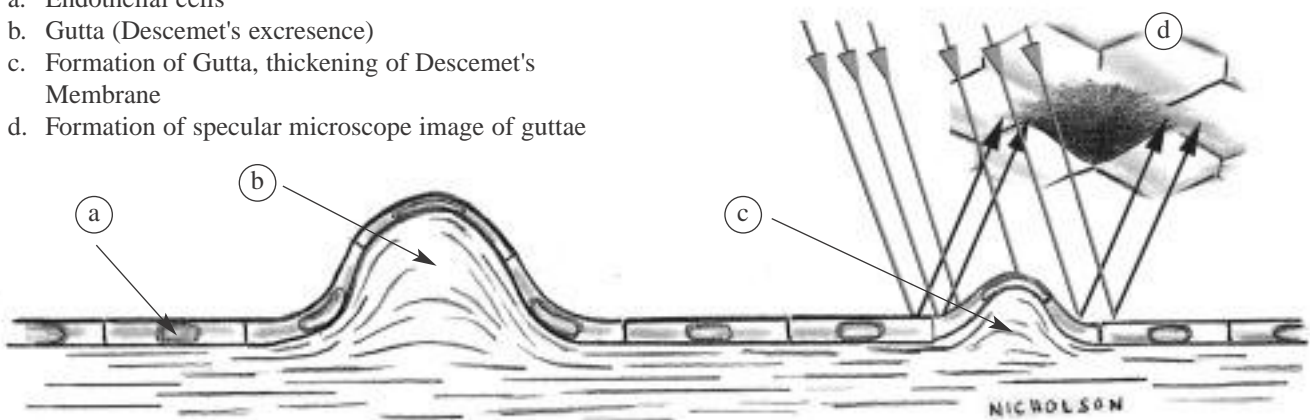
Specular Microscopy of Fuchs' Endothelial Dystrophy

In Fuchs' endothelial dystrophy the endothelial cells that secrete Descemet's apparently are in poor control (metabolically speaking) and cause wart like excrescences to form in groups primarily in the center of the cornea. The excrescences are known as guttae. Figure 22 shows the normal endothelial cells (a) as well as the guttae (b). When looking by specular techniques we see guttae as dark spots which blend with the borders of endothelial cells. The cells may thin while overlying the excrescences and eventually be absent in the area of the guttae. Figure 23 shows the origin of the guttae (a) as well as the formation of the specular image.



*Appearance of normal endothelial cells (a) and guttae (b).
(Figure 22)*

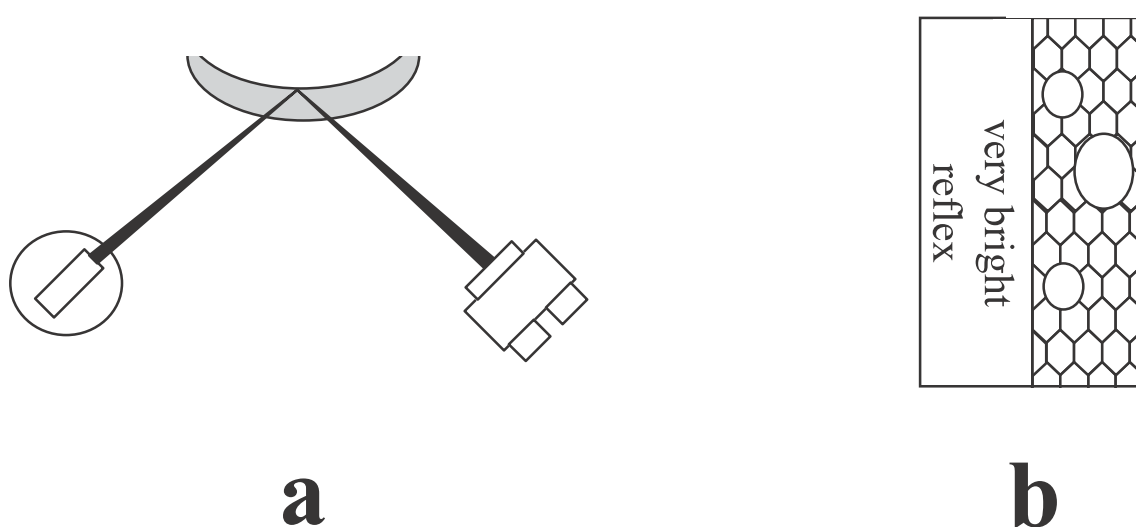
- a. Endothelial cells
- b. Gutta (Descemet's excrescence)
- c. Formation of Gutta, thickening of Descemet's Membrane
- d. Formation of specular microscope image of guttae



*Illustration demonstrating appearance, mechanism of formation, and the specular reflection seen with guttatae.
(Figure 23)*

Specular Microscopy by Slit Lamp

Use the highest power available. Mount the tissue in a stable fixture (laboratory three finger flask clamps work well) for viewing (Figure 9c). Holding or taping the container on the chin rest may work as well. Swing the slit beam source to one side at about 45 degrees and the observing microscope to the opposite direction at 45 degrees. Focus on the endothelial surface and scan from side to side. A very bright reflex will be seen coming from the endothelium. If the beam is coming from your left, look just to the right of the bright reflex. If the beam is coming from the right, look to the left of the reflex. When you see the dim reflex, focus back and forth until you see the cell mosaic in the dim reflex. Depending on the number of cells in the field, you can estimate the cell concentration. The power of the magnification and field size differ with brands and models of slit lamps. Comparing specular microscope results to the slit lamp specular reflection mosaic will allow you to accurately estimate cell counts.



(Figure 24)

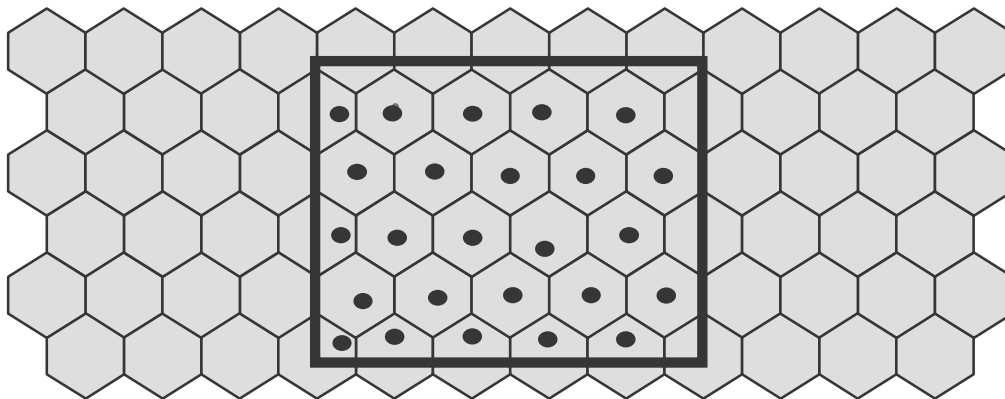
Specular Microscopy with Eye Bank Specular Microscopes

The eye bank specular microscope is designed to allow accurate evaluation of corneal endothelial cells while the cornea is in-vitro in a specially designed storage chamber. The specific operating protocol for the specular microscope should be obtained from the manufacturer or their representative. The basic procedure is to place the storage chamber on the microscope stage (the holder for the chamber). The chamber can then be positioned to make the light from the microscope shine on the central corneal endothelium. The chamber can also usually be tilted in the stage to get the maximum reflected image. Using the microscope stage the X-Y plane {tabletop} position may also have to be adjusted to maximize the reflected image intensity. Focus the image and scan the area to find a representative grouping of cells. Look for other pathology such as guttae, folds, snail tracks, etc. at the same time. Most specular microscopes have a means of recording the image to count the cell density, evaluate the morphology, and place an image on the tissue record.

Fixed Frame Analysis

Fixed frame analysis is a technique that uses a standard size frame to count the cells. The frame is used as an overlay, counting all cells within the area, those touching two sides and excluding the cells that touch the other two sides. One then divides the known area of the frame by the number of cells. The test is subjective in that the technician must pick a representative area of cells within the frame, all of which must be readily identifiable so that they can be counted. If the area of cells is irregularly shaped or doesn't fill the "frame", **variable frame analysis** can be used.

In the example below of fixed frame analysis the grid is 0.01mm^2 . The cells are counted by marking with a dot for those to be included. The cells touching the left and bottom grids are counted while those split, but not completely included by the top and right, are excluded. Dividing the number of cells by the area of the grid gives the cell density. For the example in Figure 25: **[whole cells (18) + partial cells (7)] divided by the frame area = 2500 cells/ mm^2 .**




$$\frac{25 \text{ cells}}{0.01 \text{ mm}^2} \times \frac{100}{100} = 2500 \text{ cells/ mm}^2$$

(Figure 25)

Variable Frame Analysis

Variable frame analysis in specular microscopy refers to the counting of cells using a variably shaped boundary to outline the counted cells. A computerized planimetry device is used to measure the area. The device can then divide the area by the number of cells within it to arrive at a cell density. This technique works especially well when the countable areas are irregularly shaped. The cells still need to be identified manually, generally by “clicking” on each one with the computer mouse. Since the area is defined by the borders of the cells, none are excluded. The computer then calculates the area and the number of cells is divided by the area to give the cell density.




$$\frac{13 \text{ cells}}{0.005 \text{ mm}^2} \times \frac{200}{200} = 2600 \text{ cells/mm}^2$$

(Figure 26)

Normal Cell Morphology


The endothelium is usually made up of hexagonal, regular, cells which are roughly uniform in shape.



(Figure 27)

Polymegathism

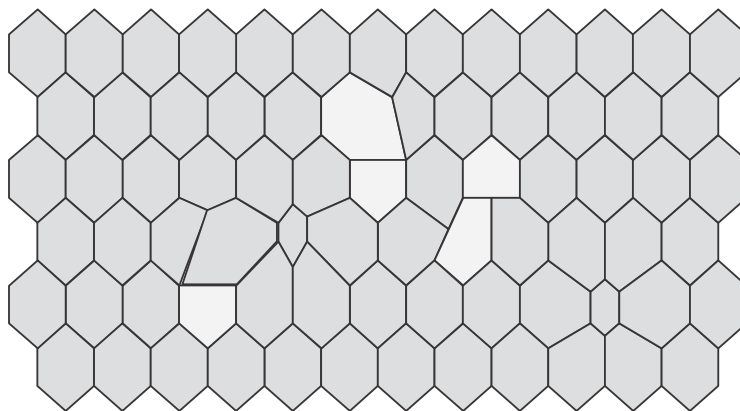
Polymegathism refers to variation in cell sizes. It rarely occurs in isolation without variation in cell shape. It is graded separately as trace, mild, moderate or severe. Note the **rosettes** which are seen as very small cells (dark shading) surrounded by much larger cells (light shading). Rosettes are not a finding specific to a disease, but rather indicate the presence of polymegathism.



(Figure 28)

Pleomorphism

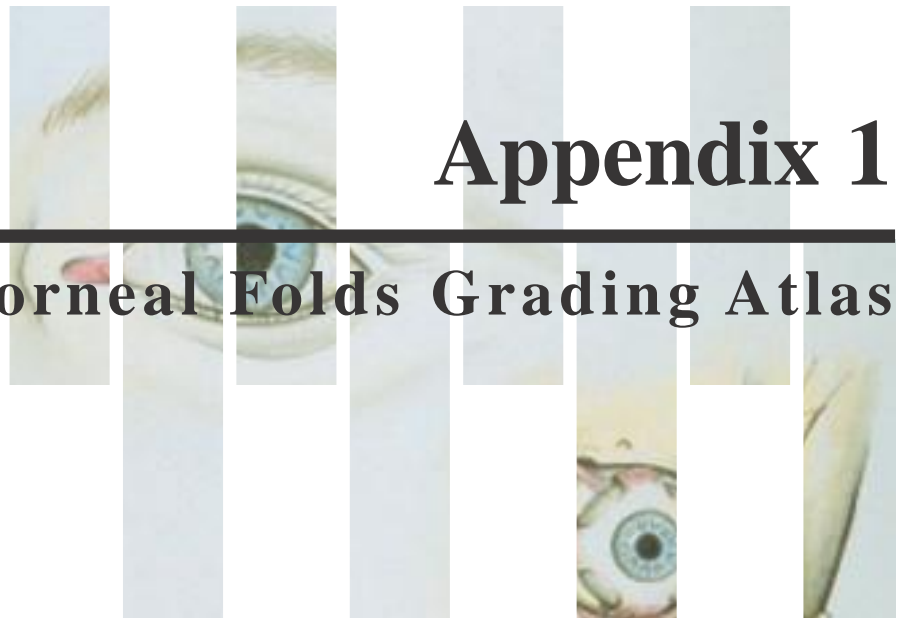Pleomorphism (also known as polymorphism) refers to variation in cell shape or their deviation from the normal hexagonal shape. By the time these changes are apparent, the variation in cell sizes (polymegathism) is usually obvious and of at least moderate degree. The polymorphic cells (light shading) shown below have different numbers of sides than their hexagonal counterparts (darker shading). Polymegathism is also present, with some rosettes seen.



(Figure 29)

Appendix 1

Corneal Folds Grading Atlas





Normal



Trace



Mild

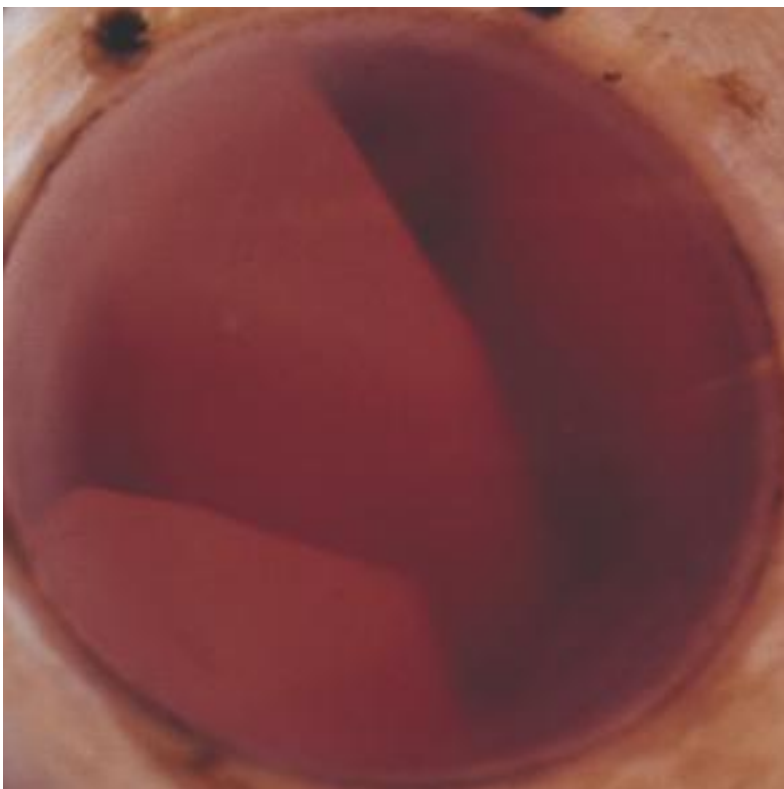


Moderate

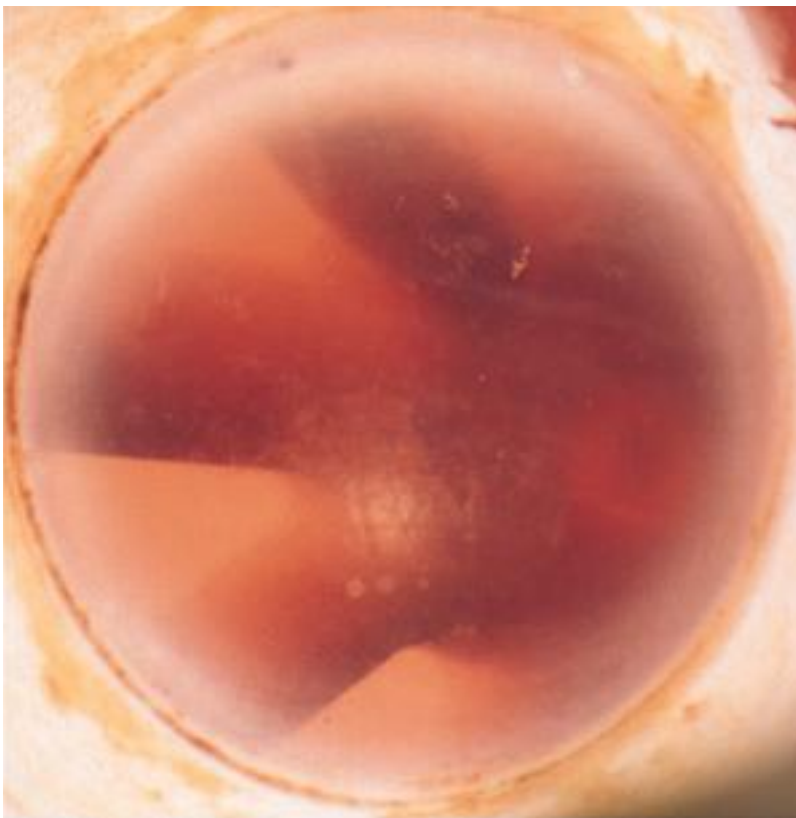
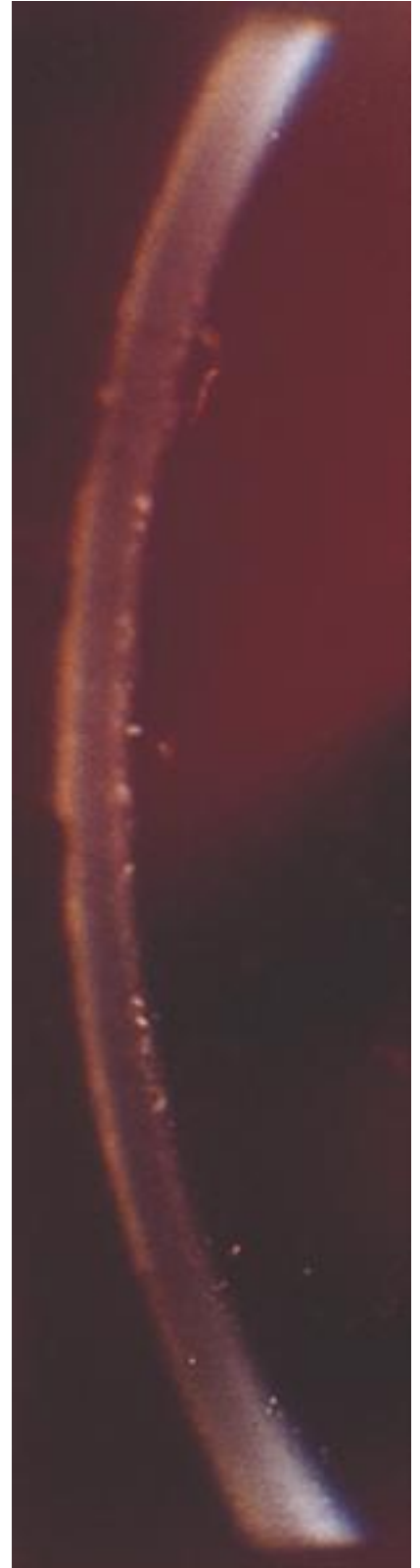
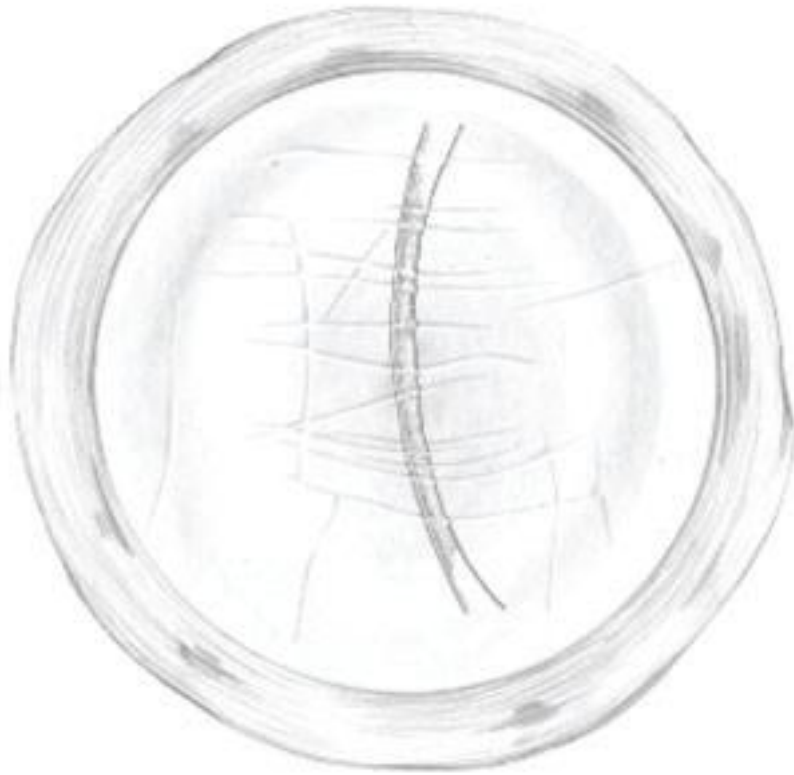

Severe

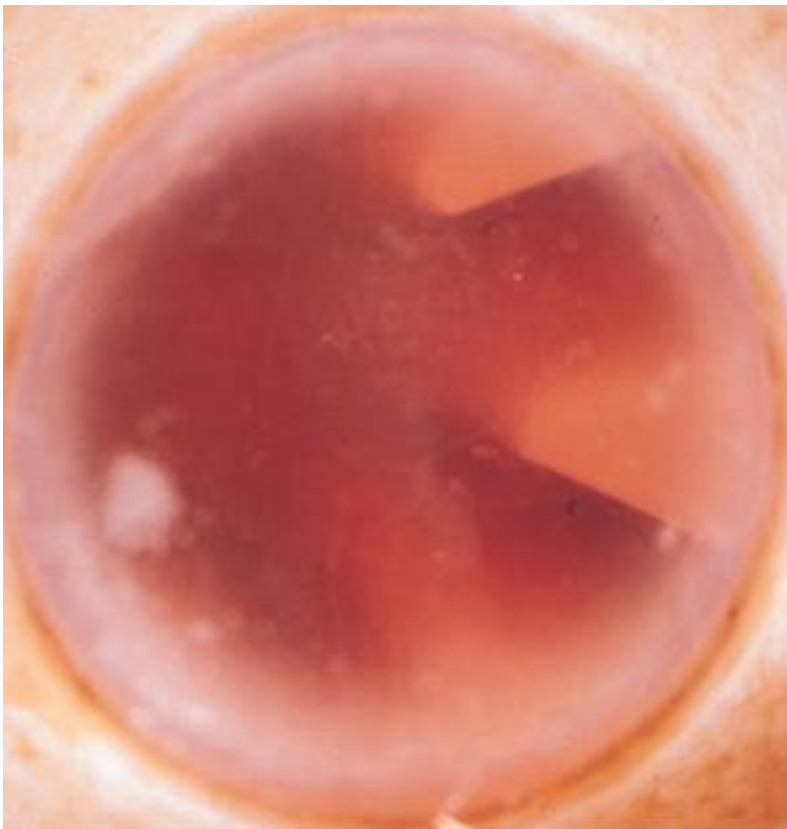

*Composite
(Appendix 1 - Figure 1)*



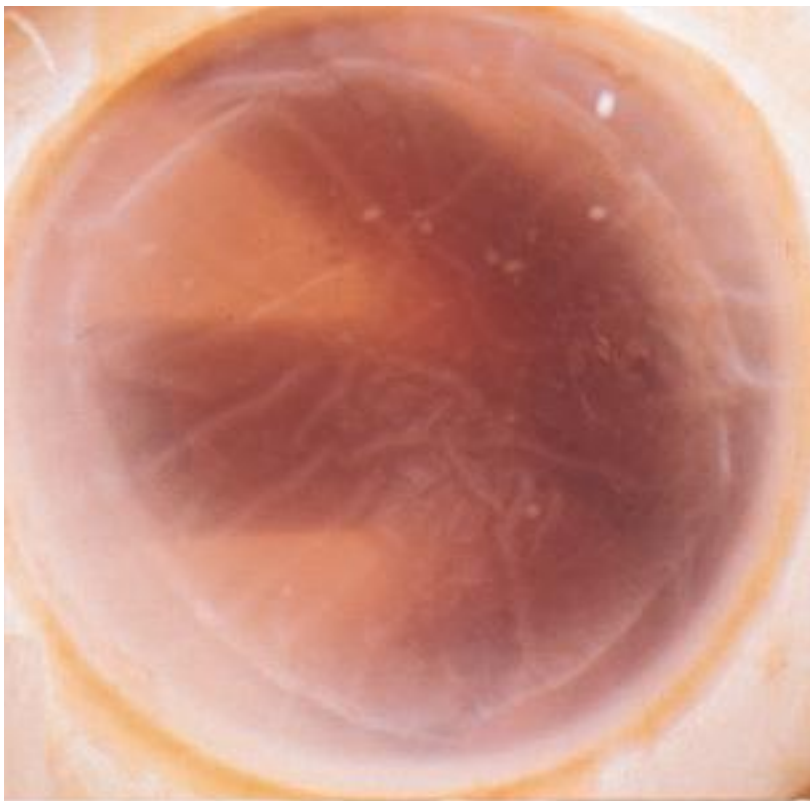

Normal
(Appendix 1 - Figure 2)



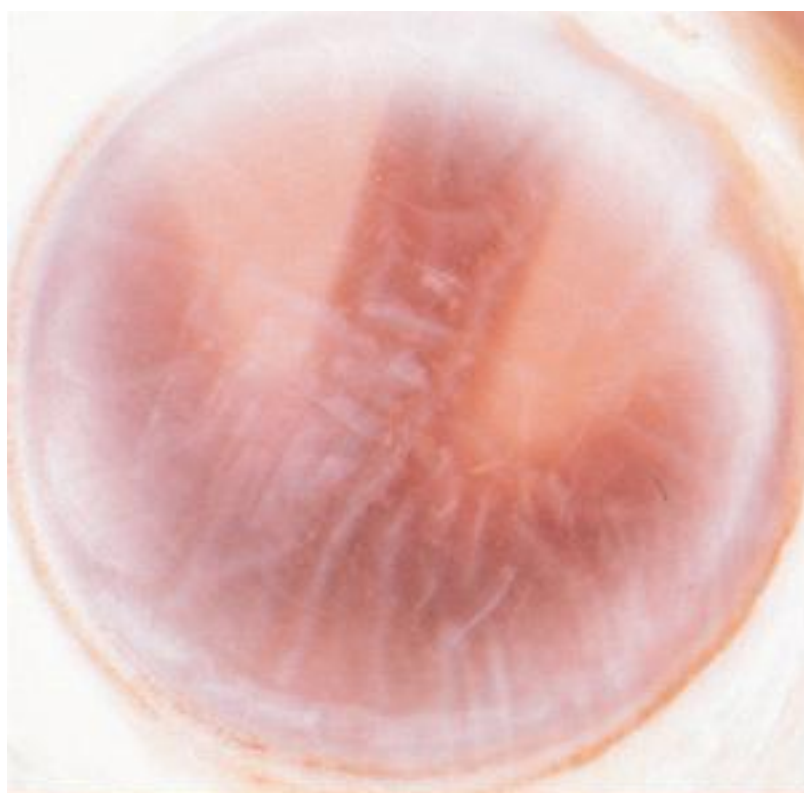
Trace
(Appendix 1 - Figure 3)



Mild
(Appendix 1 - Figure 4)



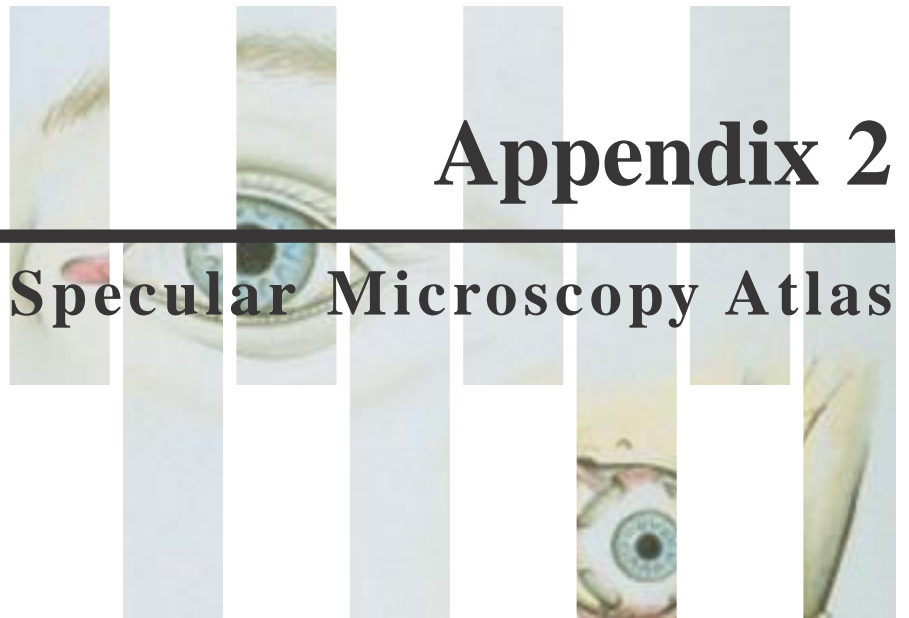
Moderate
(Appendix 1 - Figure 5)



Severe
(Appendix 1 - Figure 6)

Appendix 2

Specular Microscopy Atlas



Endothelial Specular Microscopy Legend 1-5

Top

Normal endothelium (left and right). Note the uniformity of the cell sizes and shapes. The cells are predominately hexagonal and honeycomb-like in appearance. The variation of cell size is negligible.

Middle


Swollen endothelial cells (left). The cells have highlights indicating the swelling of the individual cells. There is a dry corn cob like appearance to the surface, with the surface appearing to have shrunken inward.

Polymegathism and pleomorphism (right). Endothelial cells show considerable variation in size (polymegathism) and shape (pleomorphism).

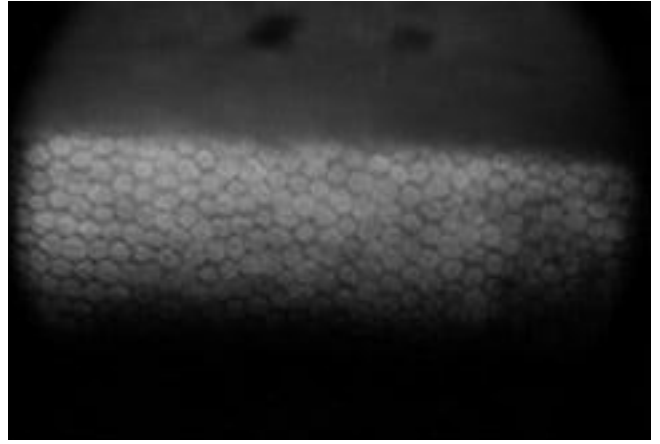
Bottom

Cells may vary in shape from triangular to nearly round, losing their hexagonal nature. Likewise, density may vary from very high to very low (left).

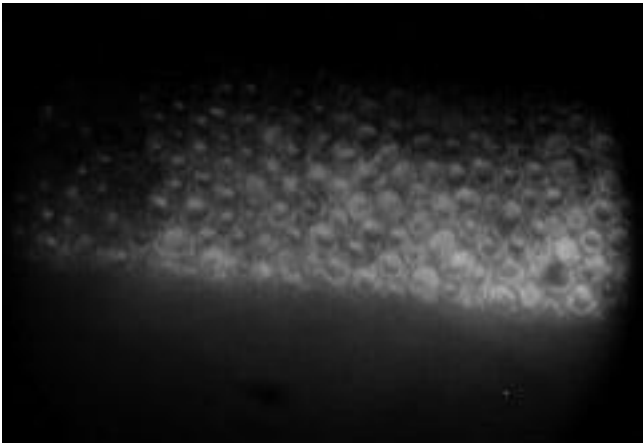
An excrescence of Descemet's membrane causes a gutta (singular) to form. Several may coalesce into a group of guttae (plural) (arrows, right).



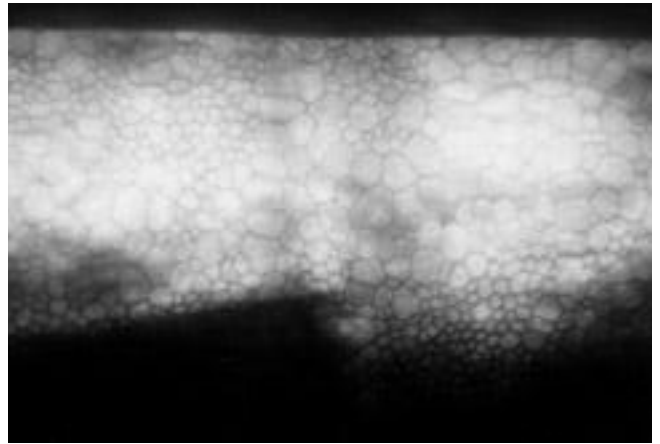
*Intact, normal endothelium.
(Figure 1)*



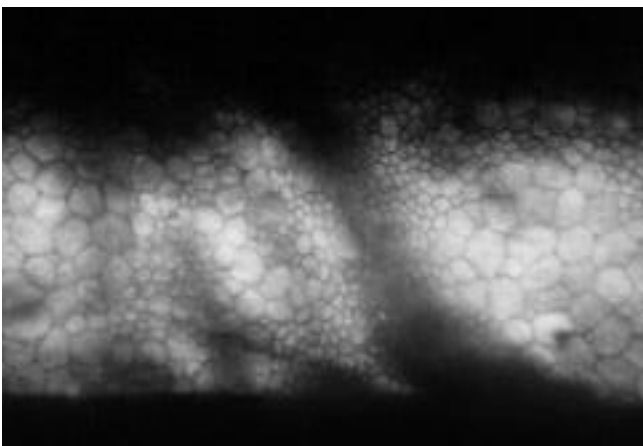
*Intact, normal endothelium.
(Figure 2)*



*Intact endothelium with swollen cells
(Figure 3)*



*Folds with pleomorphism and polymegathism
(Figure 4a)*



*Folds with pleomorphism and polymegathism
(Figure 4b)*



*Dark spots confirmed to be guttae
by scanning electron microscopy
(Figure 5)*

Endothelial Specular Microscopy Legend 6-11

Top


Small clusters of guttae on a low cell density cornea (left). Random lysed cells noted within a relatively high density endothelium (right).

Middle

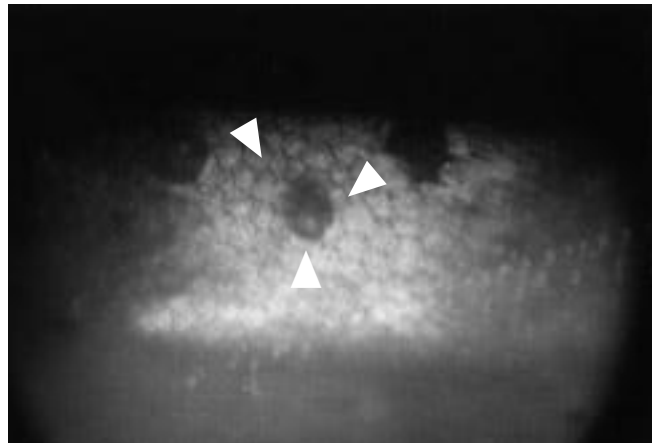
Random lysed cells (arrows, left). Striae (snail tracks, stress striae) appear as dark excavated appearing lines (right).

Bottom


Traumatic endothelial damage due to blunt trauma during a motor vehicle accident (left). An example of polymegathism in a relatively high endothelial cell density cornea (right).



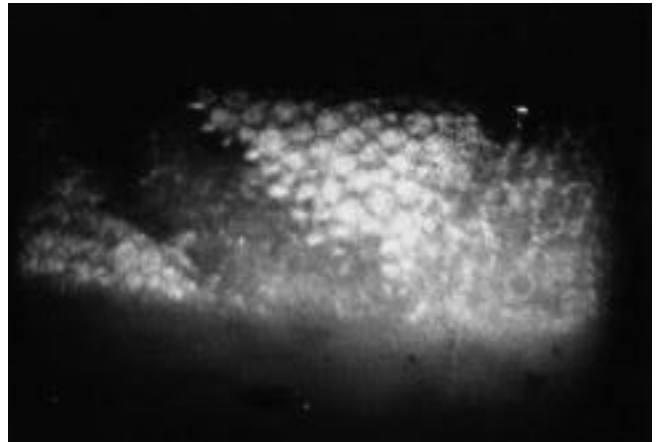
*Dark spots confirmed to be guttae
by scanning electron microscopy
(Figure 6)*



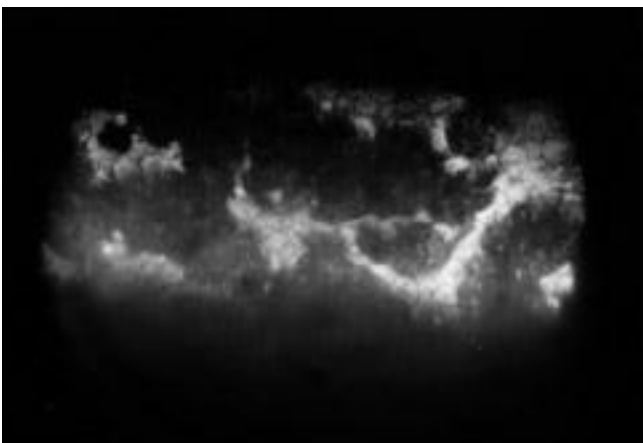
*Dark spots confirmed to be lysed cells
by scanning electron microscopy
(Figure 7)*



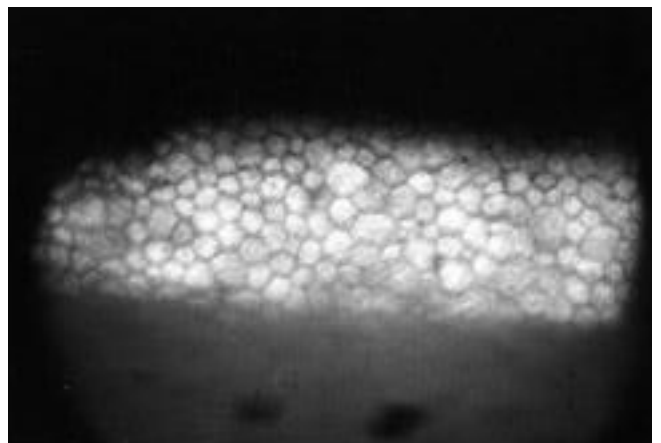
*Dark spots confirmed to be lysed cells
by scanning electron microscopy
(Figure 8)*



*Donor endothelium bisected by a dark stress line
(endothelial striae) probably caused by bending and
trauma during corneal excision
(Figure 9)*



*Damaged donor endothelium due to trauma.
Donor involved in motor vehicle accident
with obvious external trauma to the orbit
(Figure 10)*



*Intact donor endothelium with mild polymegathism
(Figure 11)*

*Endothelial Specular Microscopy
(Appendix 2 - Figures 6-11)*

Endothelial Specular Microscopy Legend 12-17

Top

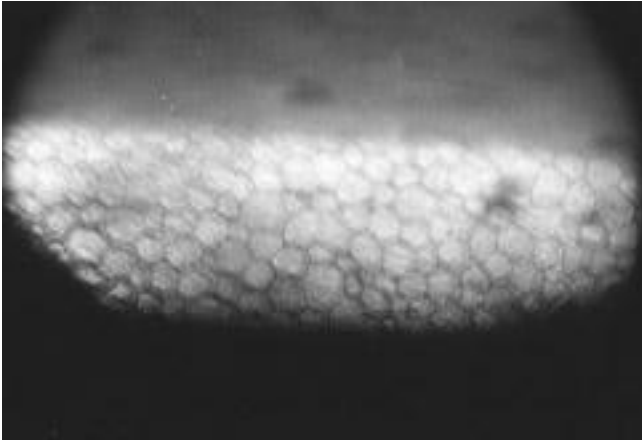
Mild polymegathism (left) and moderate polymegathism (right).

Middle

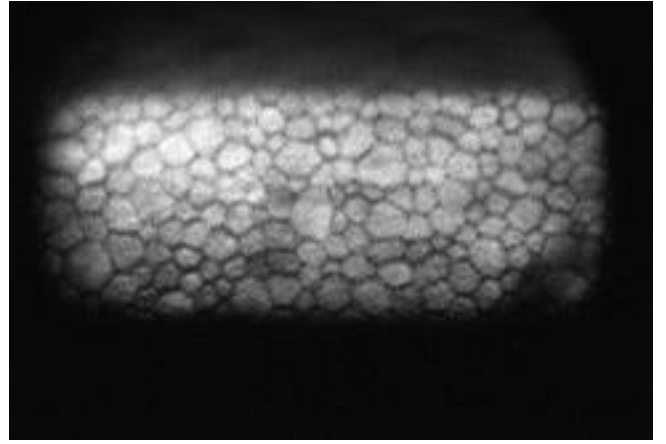
Moderate polymegathism (left) and severe polymegathism (right).

Bottom

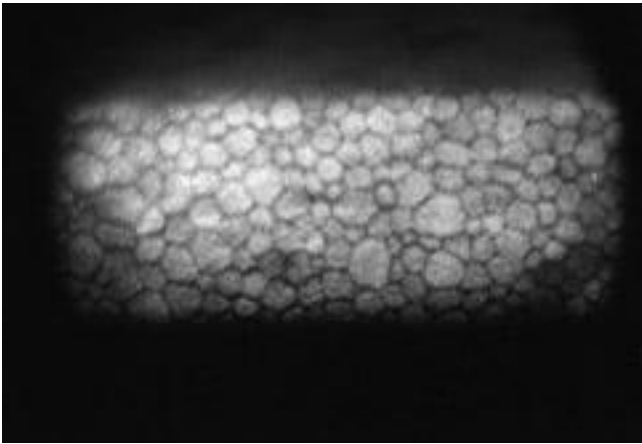
Examples of severe polymegathism (left and right).



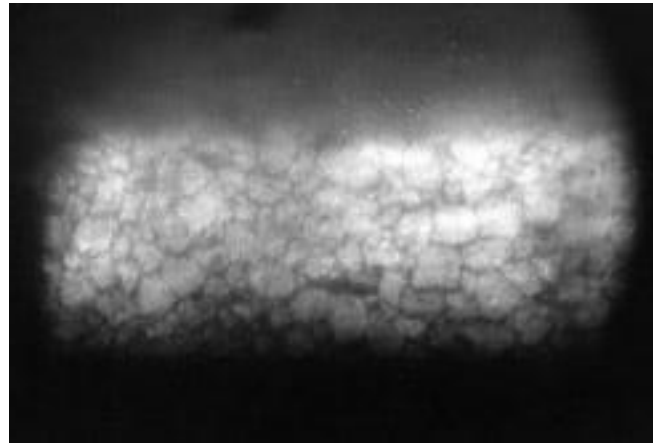
*Intact donor endothelium with mild polymegathism
(Figure 12)*




*Intact donor endothelium with moderate polymegathism
(Figure 13)*



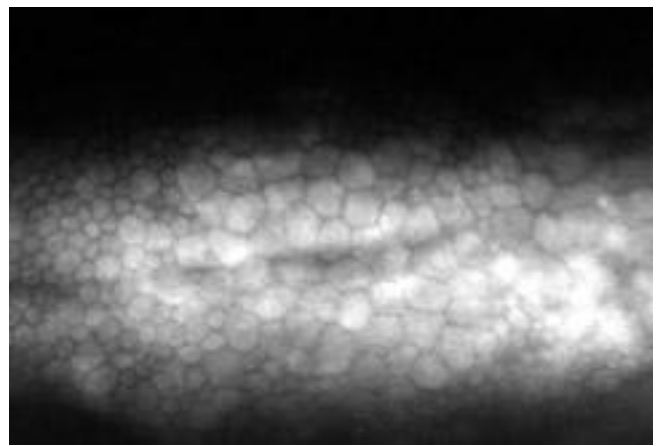
*Intact donor endothelium with moderate polymegathism
(Figure 14)*



*Intact donor endothelium with severe polymegathism
and pleomorphism
(Figure 15)*



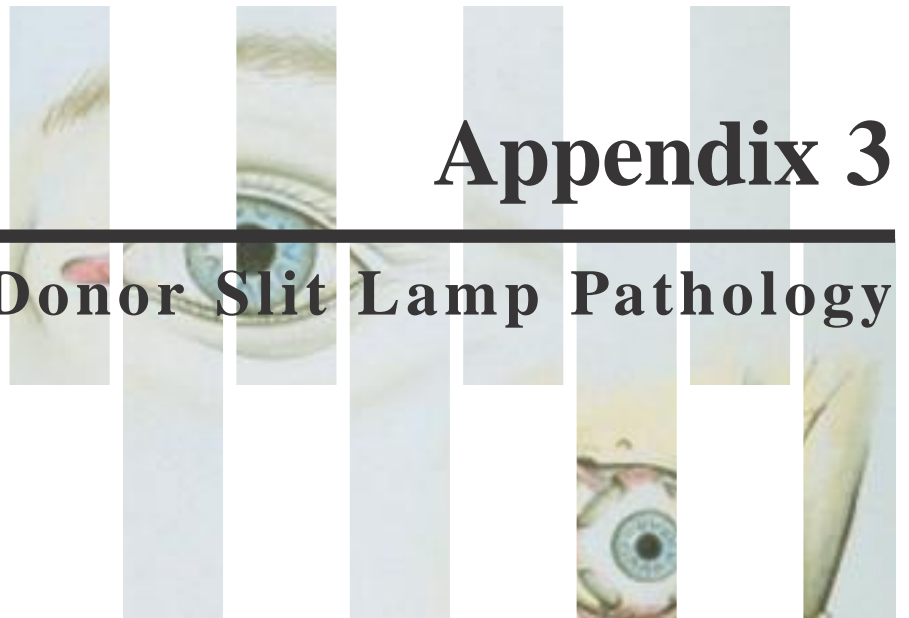*Intact donor endothelium with severe polymegathism
and pleomorphism
(Figure 16)*



*Human endothelium in vivo with severe polymegathism
due to long term contact lens wear
(Figure 17)*

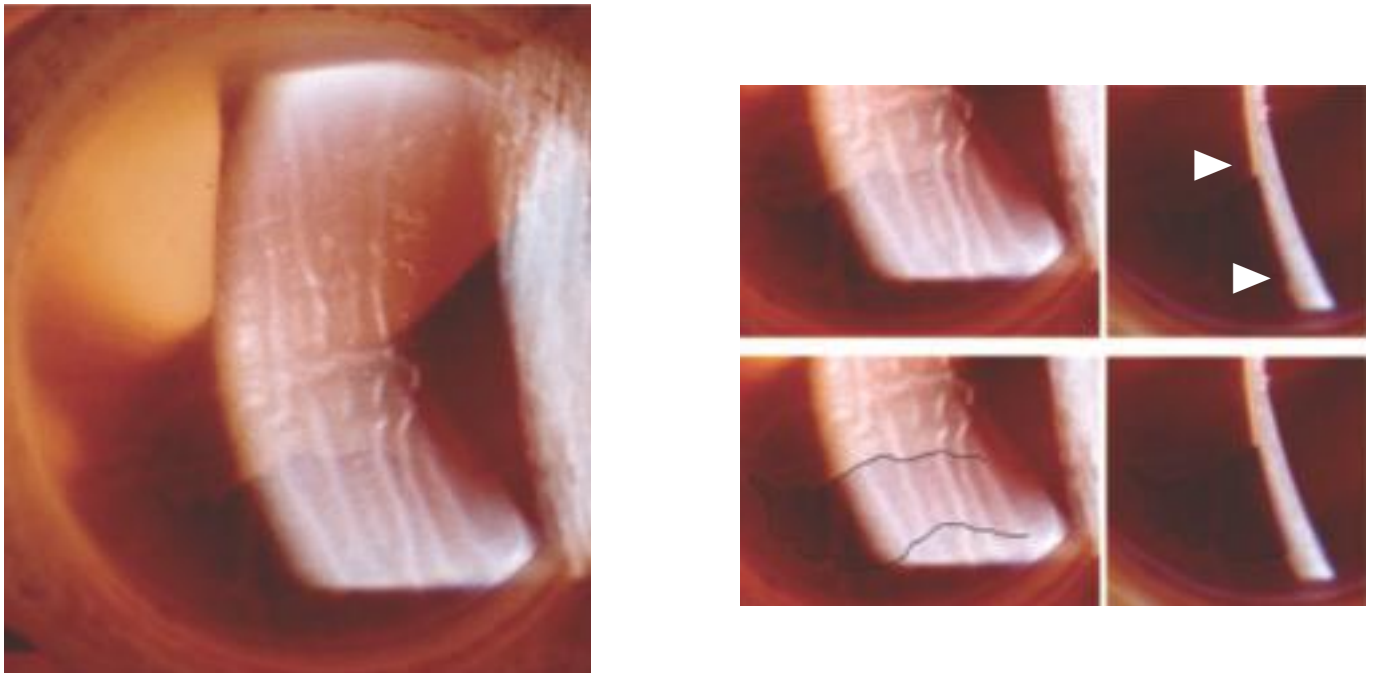
Appendix 3

Eye Donor Slit Lamp Pathology



Epithelial Defect

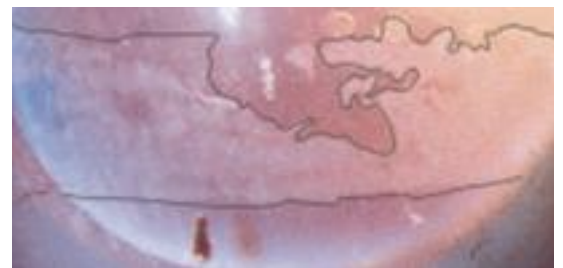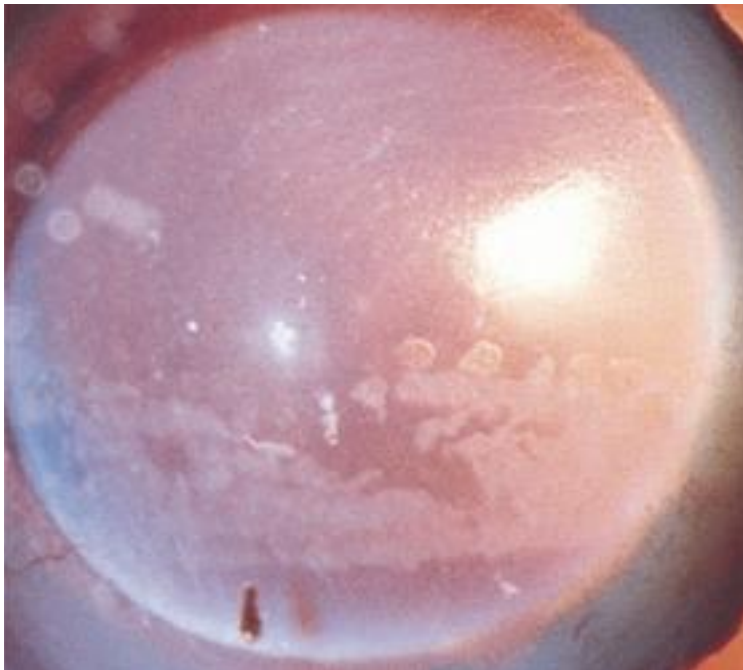
Donor tissue epithelial defect. An epithelial defect on the lower portion of the cornea is seen in the photograph on the left. The slit beam view seen in the upper right photograph shows the elevated edges of the epithelium (arrows). The epithelial defect is outlined in black in the photographs on the lower right.



Epithelial Defect
(Appendix 3 - Figure 1)

Exposure Keratopathy

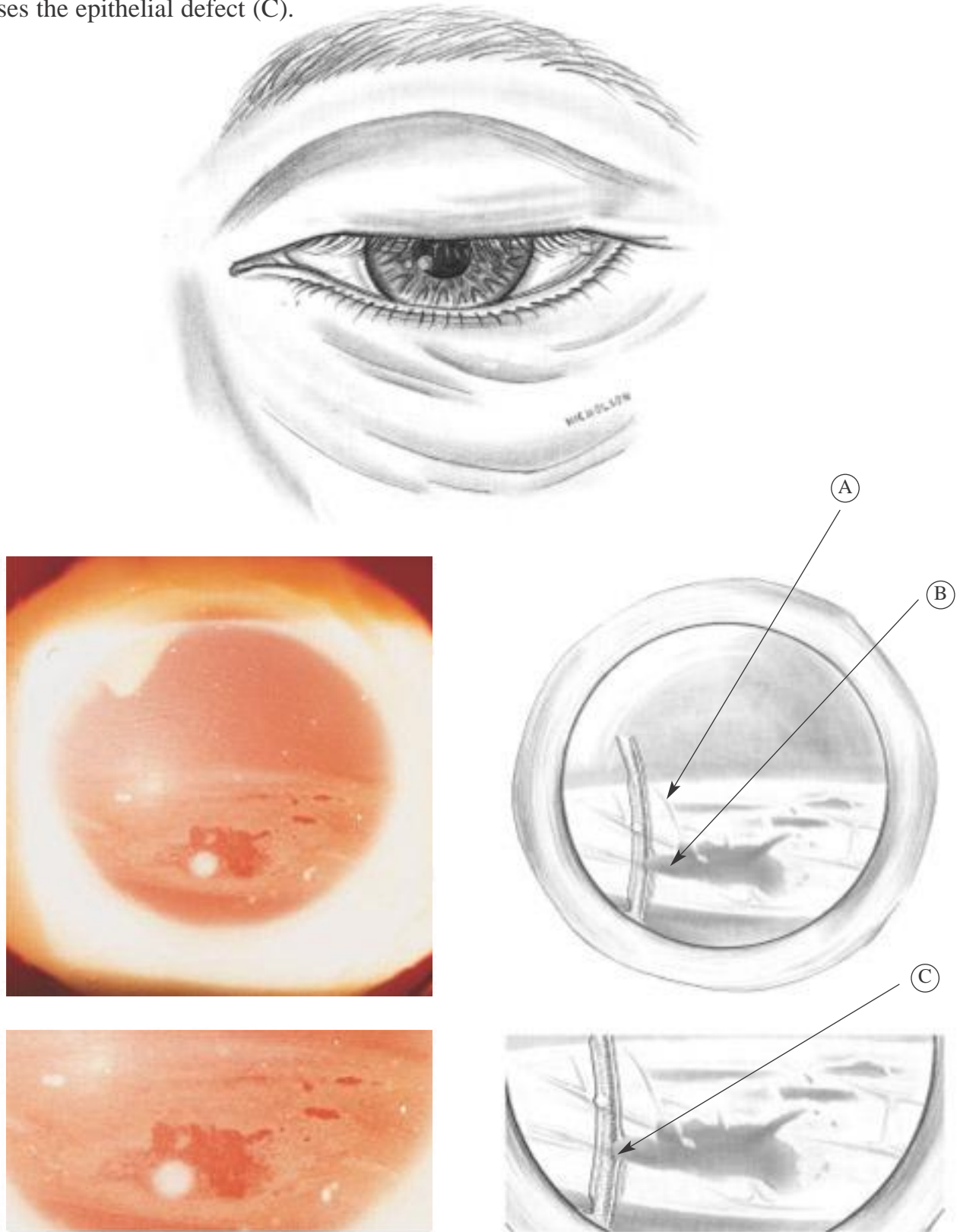
Epithelial exposure is seen as a band-like swelling and opacification of the epithelium where the lids remained open pre- or post-mortem. The photograph on the right shows the area outlined in black.



*Exposure Keratopathy
(Appendix 3 - Figure 2)*

Epithelial Defect and Exposure

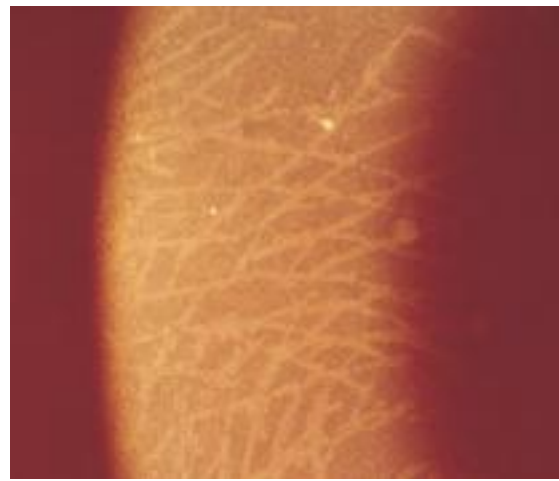
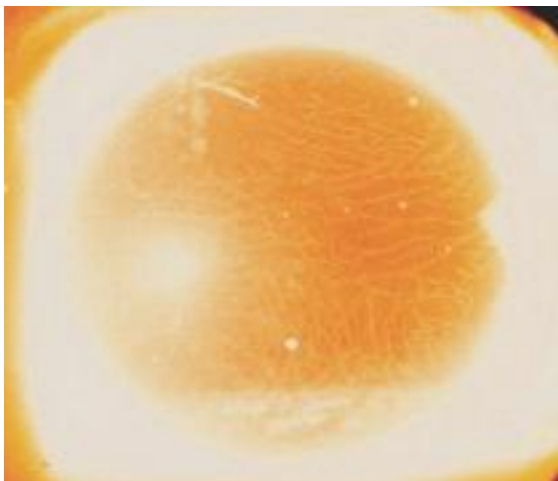
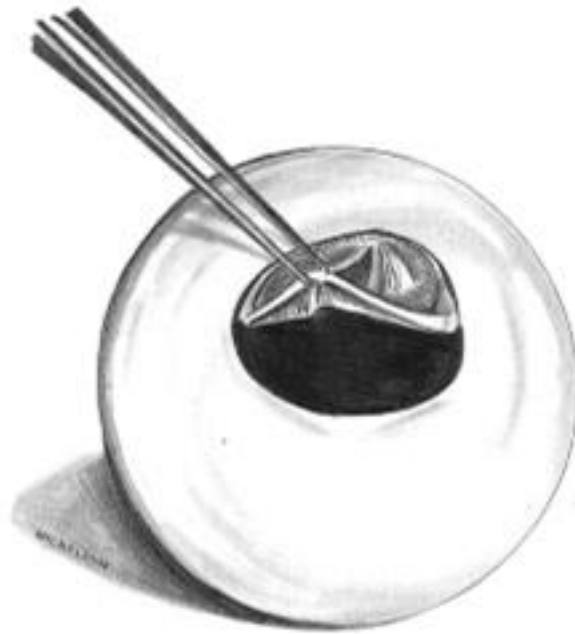
Epithelial defect (B) within an area of exposure (A). The epithelial defect is denoted by the arrowheads. Poor closure of the lids, pre- or post-mortem, is responsible for the shape of the area involved. This corresponds to the outline of the lid margins. Note the break in the slit beam as it crosses the epithelial defect (C).



*Epithelial Defect and Exposure
(Appendix 3 - Figure 3)*

Snail Tracks, Stress Striae

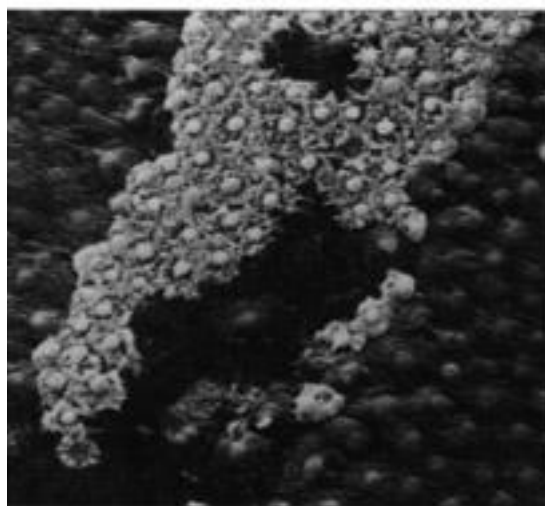
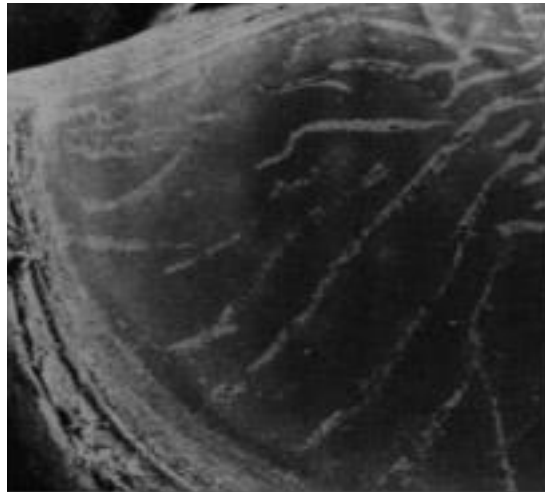
Careless folding of the corneal cap during removal causes snail tracks (top). The middle and lower illustrations show snail tracks at varying degrees of magnification.



Snail Tracks, Stress Striae
(Appendix 3 - Figure 4a)

Electron Microscopy of Snail Tracks

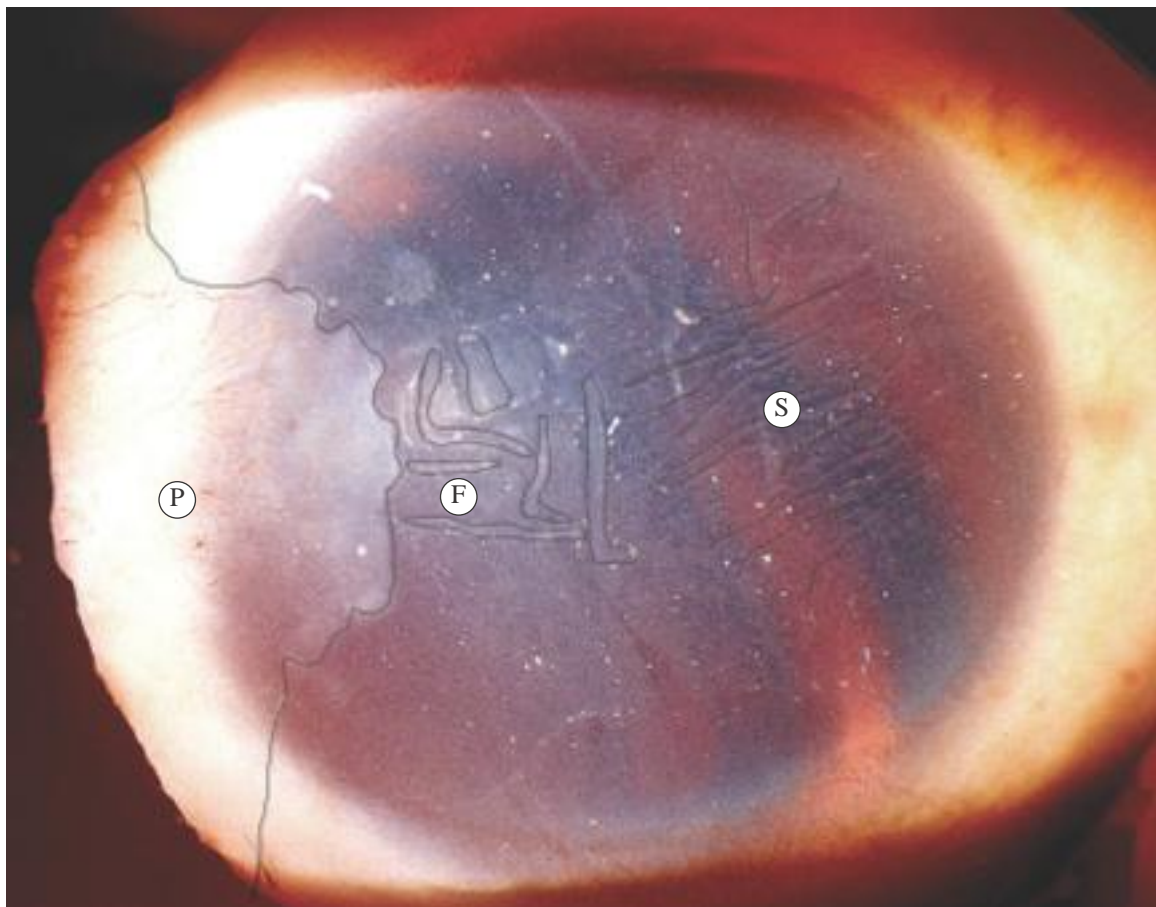
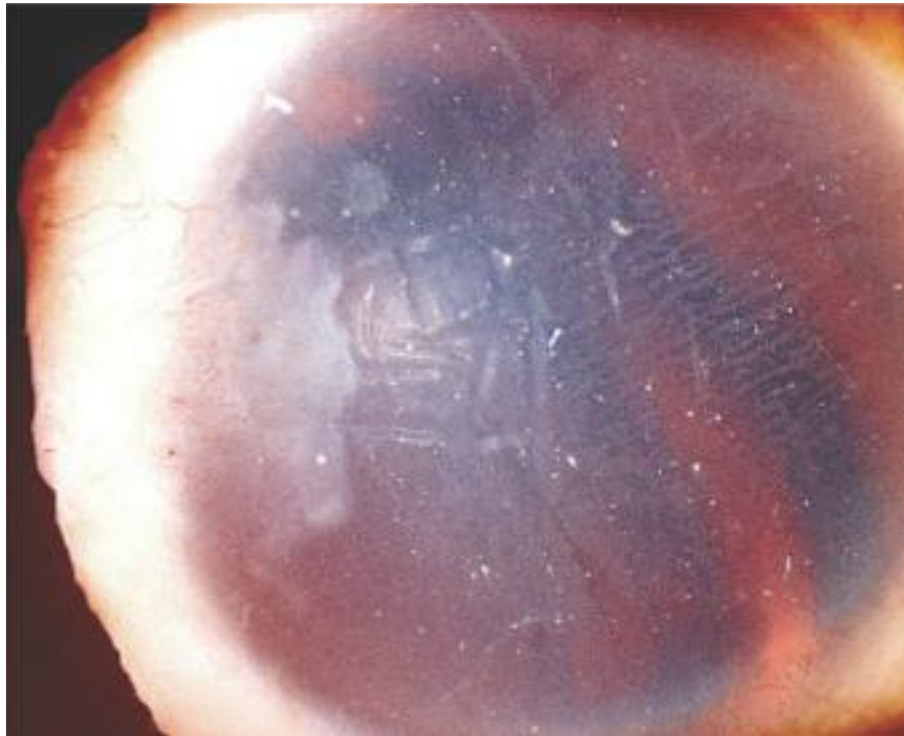
Low (top) to high (bottom) magnification views of endothelial snail tracks. Electron microscopy shows snail tracks as areas of disruption which appear to have detached endothelial cells. The detachment of the cells will cause them to die and be lost into the aqueous.



*Electron Microscopy of Snail Tracks
(Appendix 3 - Figure 4b)*

Pterygium and Snail Tracks

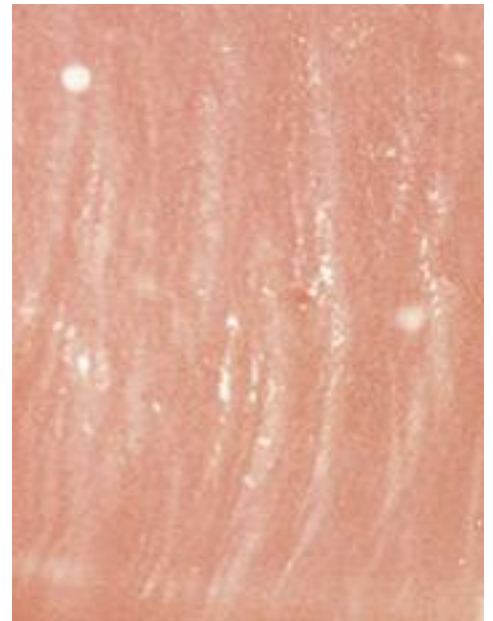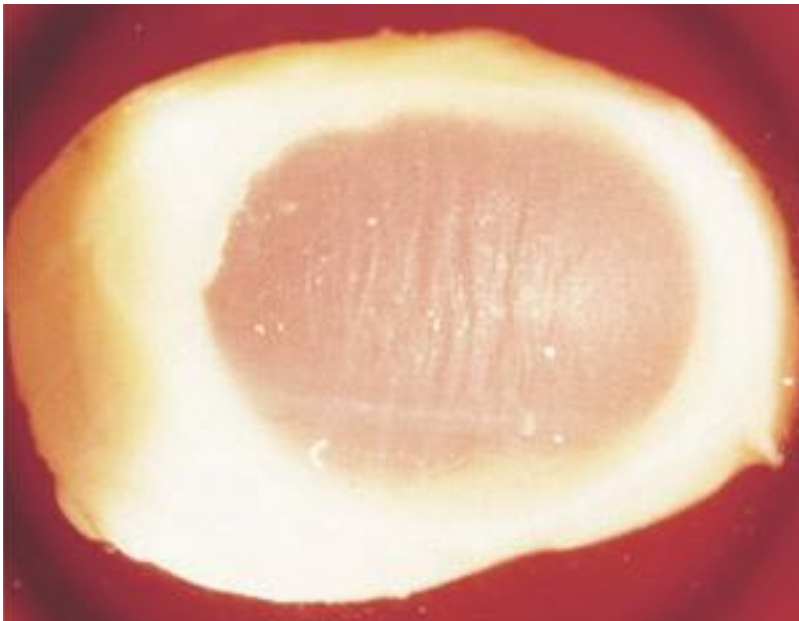
Pterygium, (P), folds (F), and snail tracks(S).



Pterygium and Snail Tracks
(Appendix 3 - Figure 5)

Infant Cornea


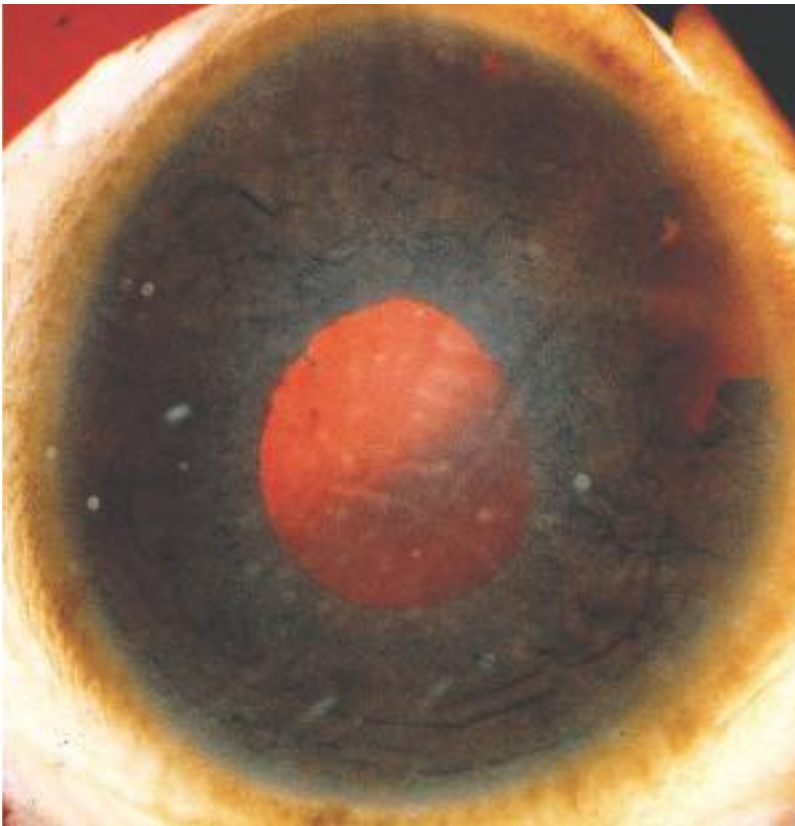
Infant corneas may show overall shape changes (left) and striae (right) as a result of their pliability, which is substantially greater than that of adult tissue.



Infant Cornea
(Appendix 3 - Figure 6)

Donor Rim with Iris

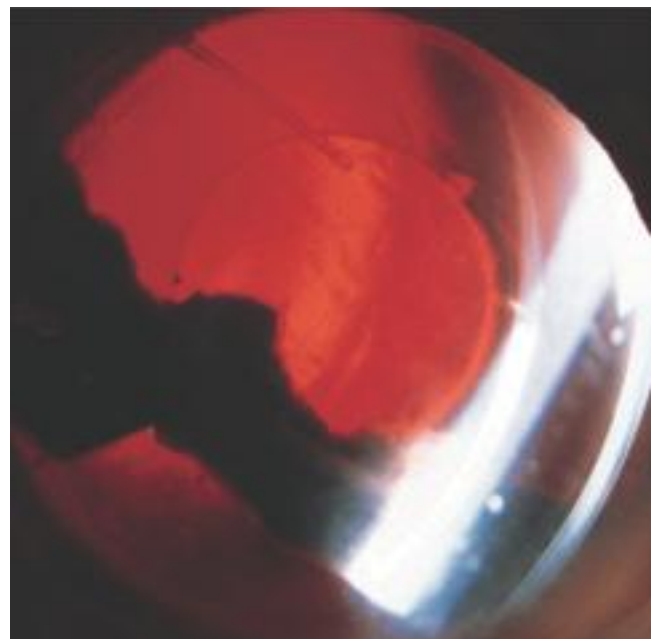
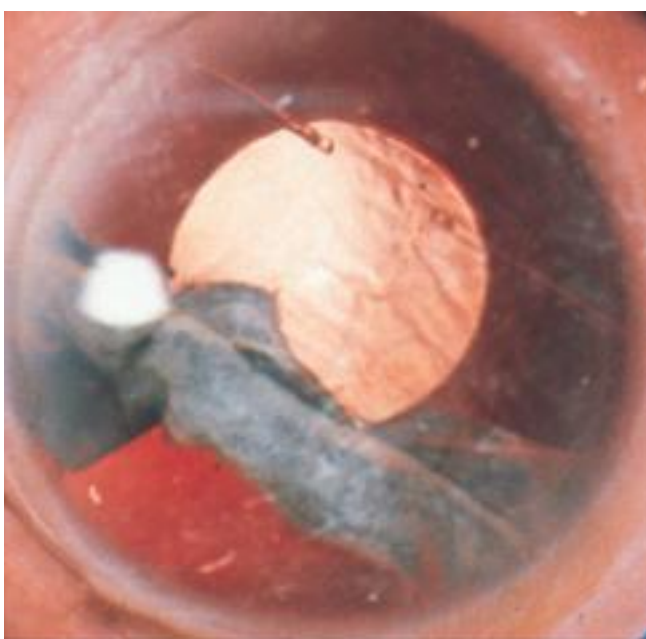
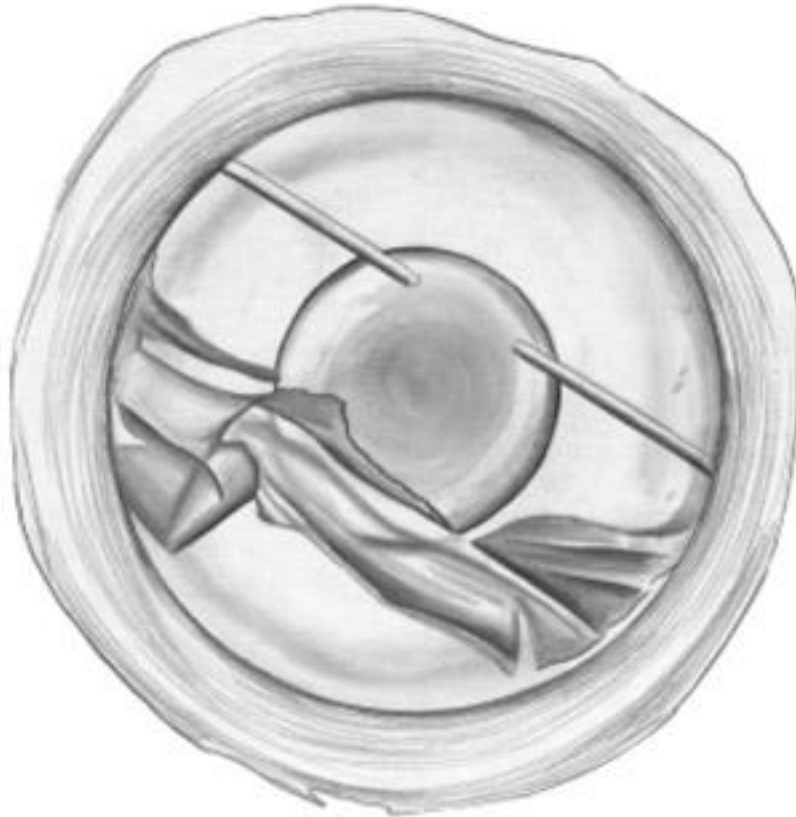
The corneal scleral rim in this picture has been removed with the donor's iris (left). A peripheral iridectomy is seen as well. The slit beam illuminates the cornea and falls next on the iris (right).



*Donor Rim with Attached Iris
(Appendix 3 - Figure 7)*

Donor with Lens Implant and Iris

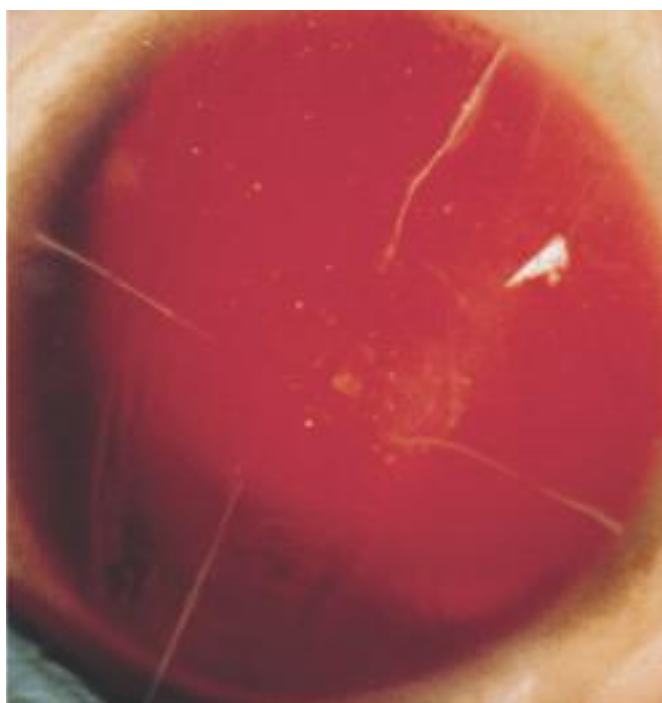The cornea and scleral rim in this picture have been removed with the donor's iris, as well as an anterior chamber lens implant, which is positioned in the angle between the iris and the cornea. Arrows identify the lens optic, haptic and iris (above). The view seen in the lower two photographs is from behind the cornea with direct illumination (lower left) and retroillumination (lower right).



*Donor Rim with Lens Implant and Iris
(Appendix 3 - Figure 8)*

Radial Keratotomy

The photograph demonstrates a four incision radial keratotomy in a donor. The incisions are normally quite deep (90% to nearly full thickness). The arrows indicate the radial incisions.

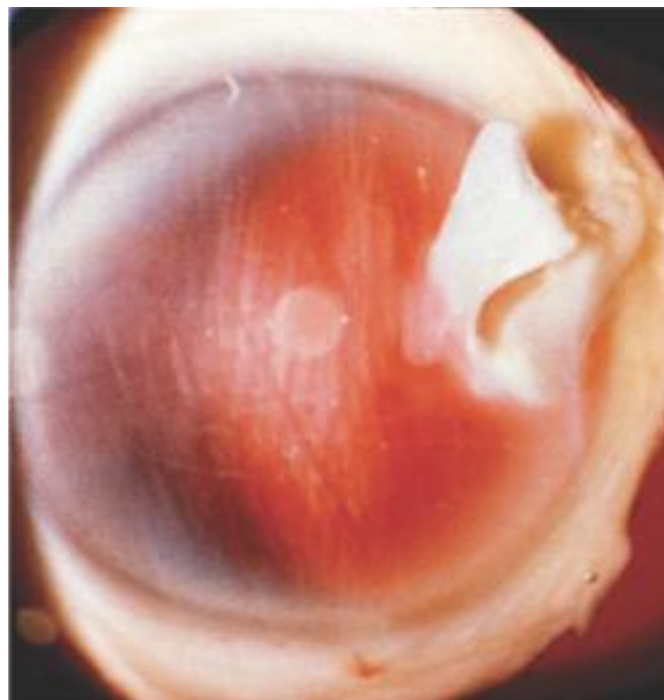
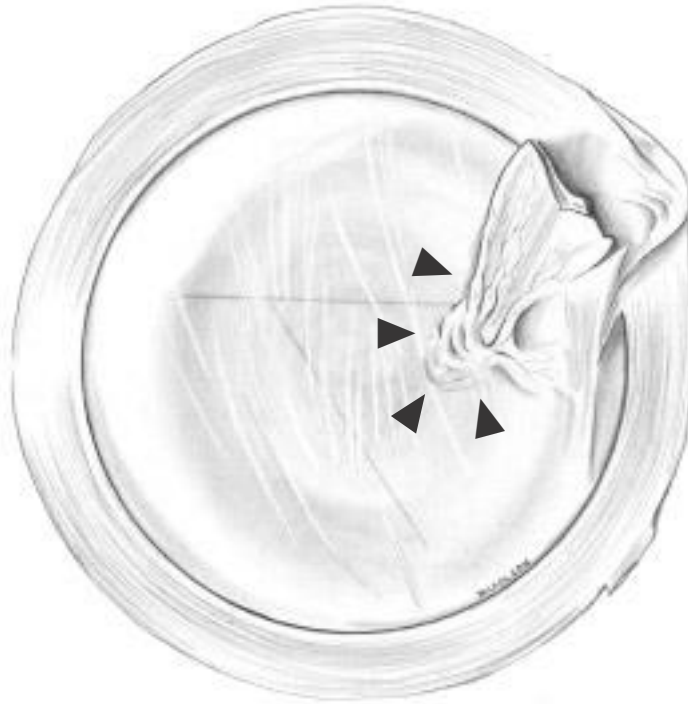

*Radial Keratotomy in a Donor Cornea
(Appendix 3 - Figure 9)*

Pterygium

A pterygium is a fleshy attachment of conjunctiva which crosses the limbus and is attached to the cornea. When preserved the conjunctiva may appear to float freely above the cornea as is seen in the photograph. The pterygium is identified by the arrowheads in the photograph and drawing.

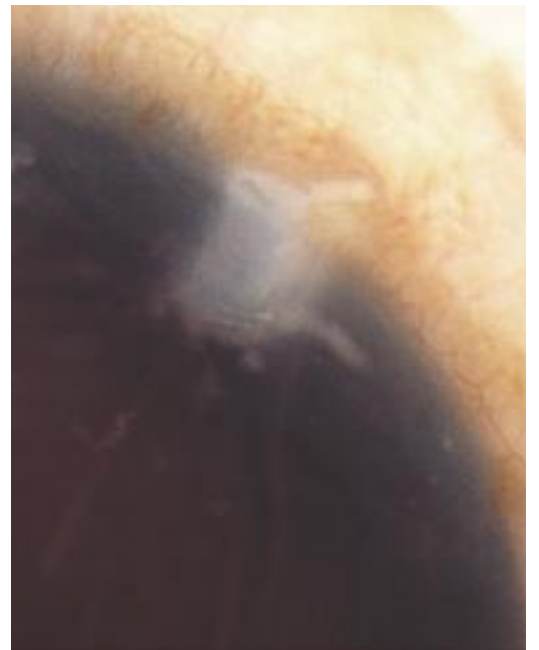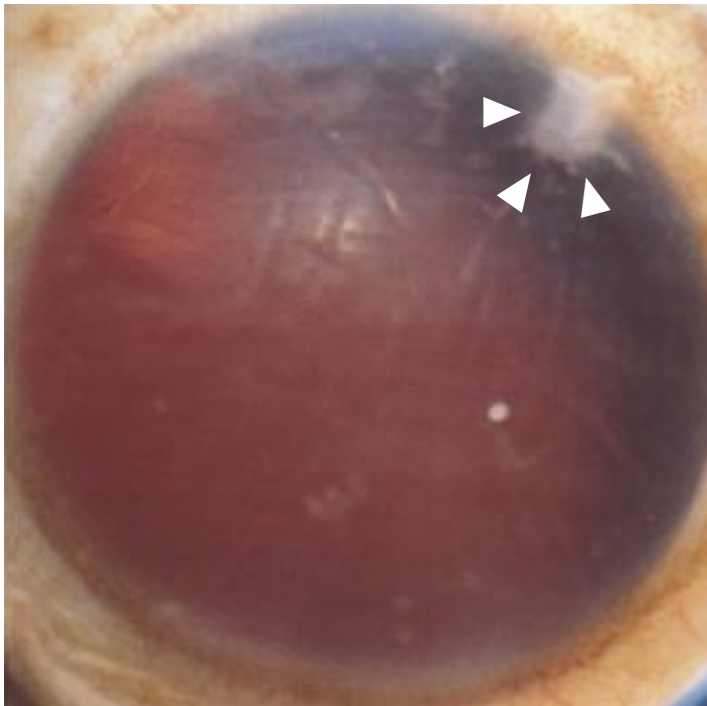
If the corneal button to be taken from the donor contains part of the pterygium, the clarity may not be satisfactory for a successful transplant.



Pterygium.
(Appendix 3 - Figure 10)

Puncture Wound in Donor Cornea

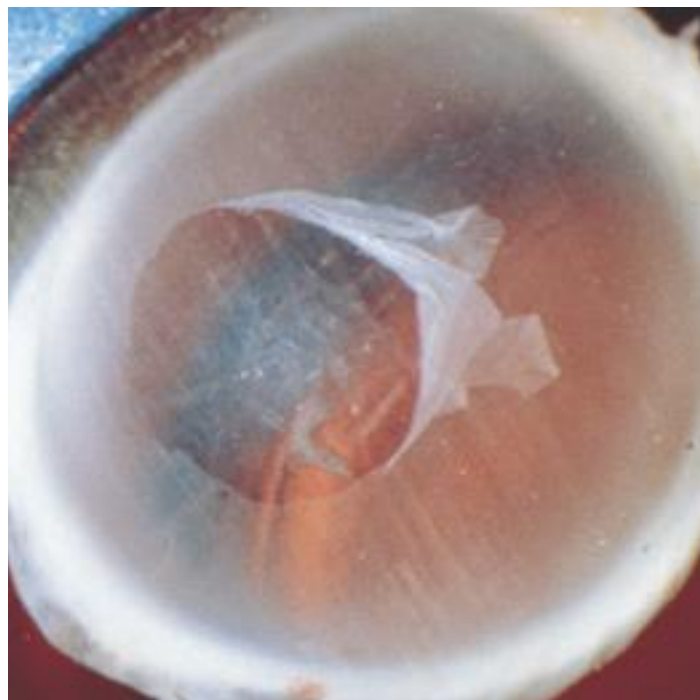
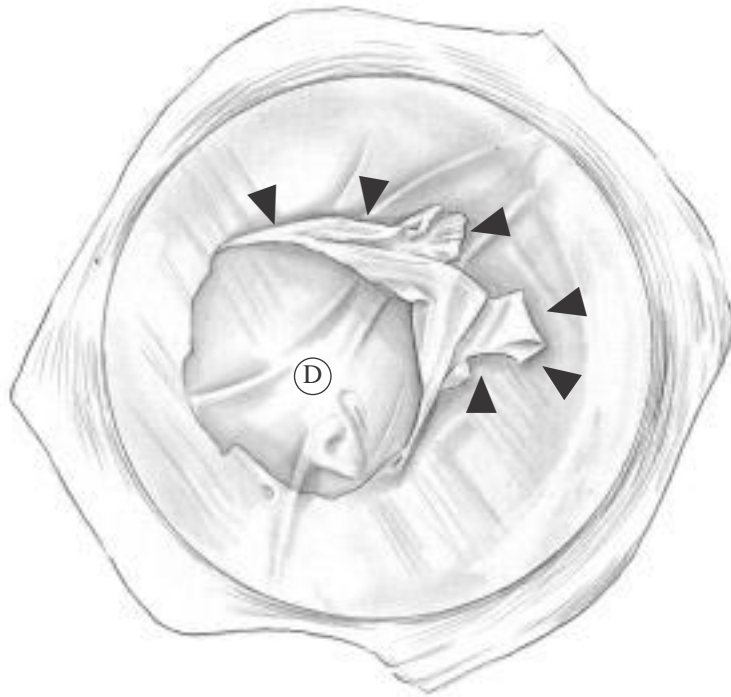
Puncture wound in a donor cornea. A morgue technician removing vitreous for toxicology analysis mistakenly inserted the needle through the cornea rather than the posterior sclera. The resulting wound may jeopardize the quality of the donor button. The external entry point is indicated by the arrow and the balance of the trans-corneal wound by the arrowheads.



*Puncture Wound in the Corneal Periphery
(Appendix 3 - Figure 11)*

Epithelial Sloughing

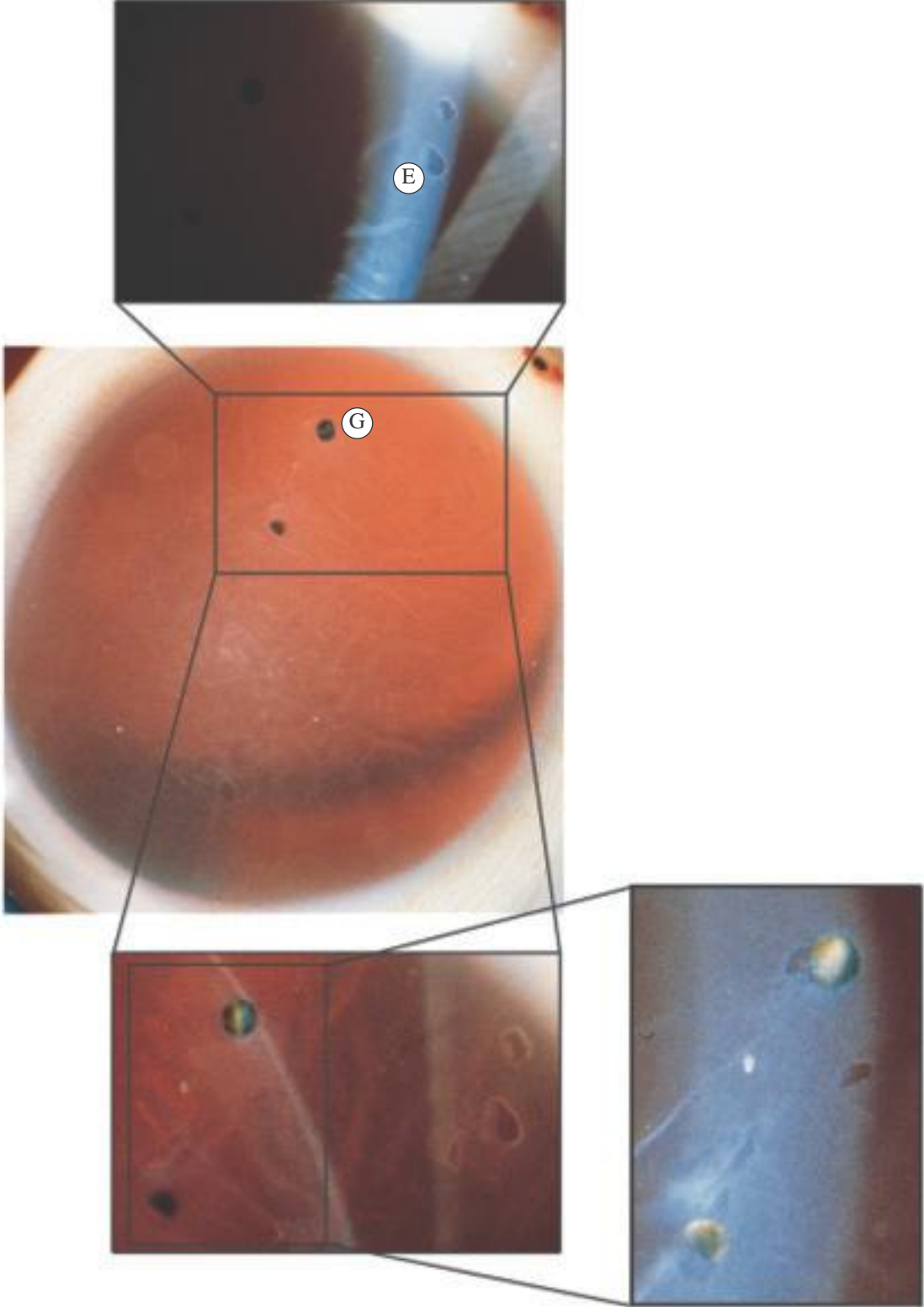
Epithelial sloughing. During preservation the epithelial cells may swell and become optically opaque. When the multiple layers of epithelium detach from the corneal surface sloughing occurs. The area “D” represents an epithelial defect. The sloughed area of epithelium is folded back on itself and is outlined by the arrows.



Epithelial Sloughing.
(Appendix 3 - Figure 12)

Gunpowder Foreign Bodies

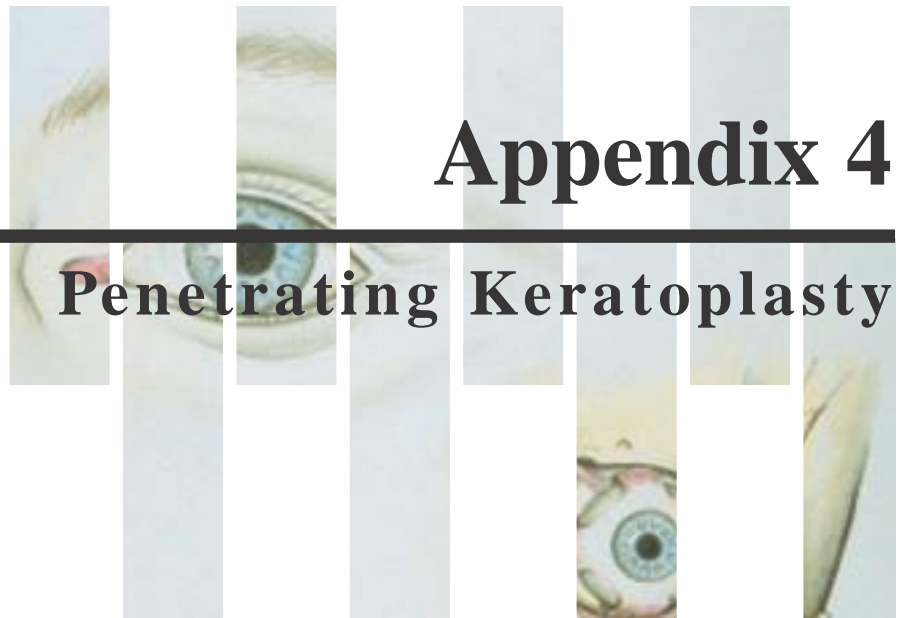
Gunpowder foreign bodies. The donor tissue shows evidence of gunpowder deposition (G) on the corneal surface. This has also caused multiple epithelial defects (E). The presence of the foreign material as well as the blunt injury that impact delivers may make the tissue unsuitable for use.



*Gunpowder Foreign Bodies and Epithelial Defects Due to Impact.
(Appendix 3 - Figure 13)*

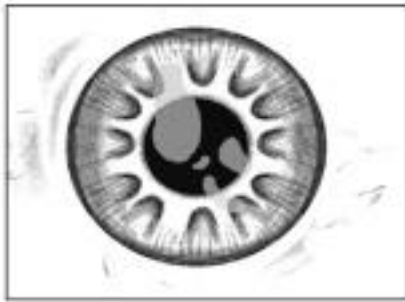
Appendix 4

Penetrating Keratoplasty



Penetrating Keratoplasty

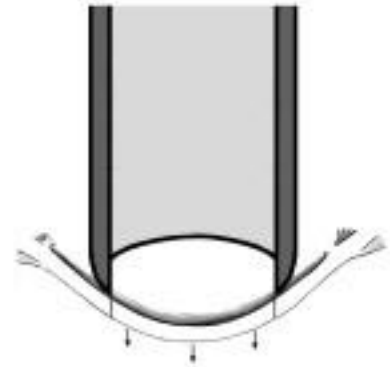
Donor Preparation
Recipient Preparation
Suturing Technique



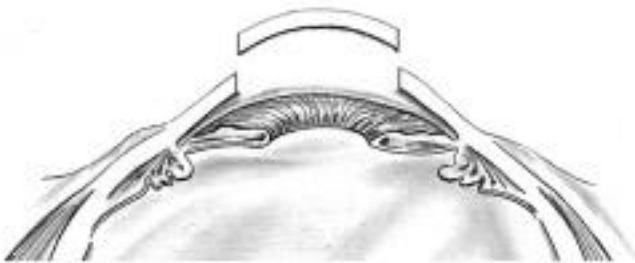A



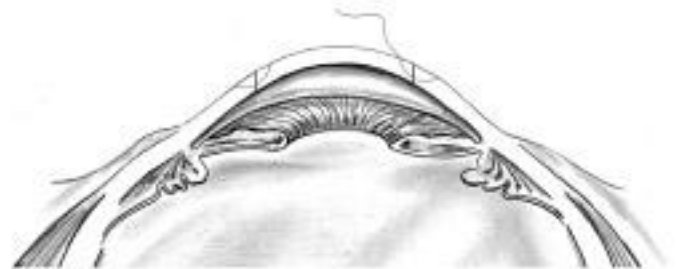
B



C

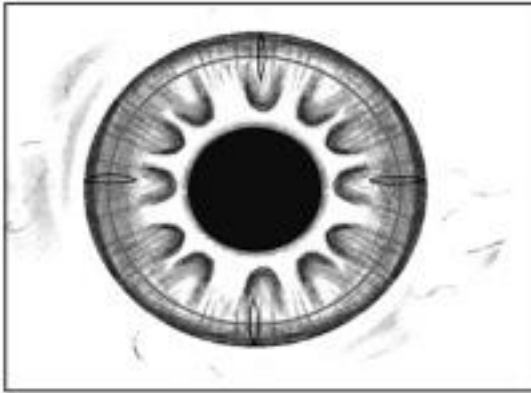


D

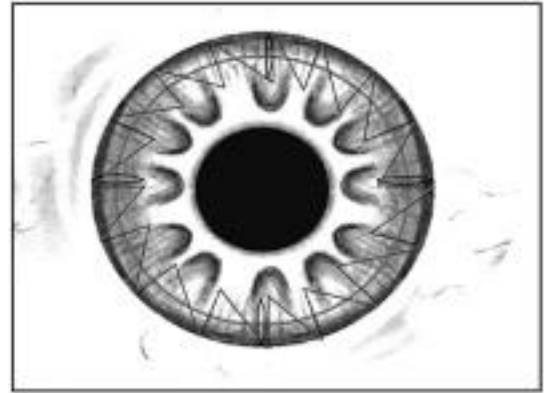


E

- A. A scarred cornea about to receive a corneal transplant.
- D. Trephining of the recipient from the epithelial side with a suction trephine. The inner trephine rotates to achieve a measured depth cut.
- C. Trephining of the donor button from the endothelial side. The cornea is frequently held by a suction base. The cut is achieved by plunge cutting (pressure squeezing the corneal donor between the trephine and base).
- D. The patient's cornea is removed and the donor button is transferred to the recipient bed.
- E. The donor is sutured to the recipient with interrupted sutures generally of 10-0 nylon.



F



G

- F. The donor tissue is held in place with four interrupted cardinal sutures.*
G. A running or many other interrupted sutures are placed to complete the suturing of the transplant.
The sutures are usually left in place for a year or longer to allow healing of the graft host junction.
(Appendix 4 - Figure 1)



Appendix 5

Glossary

anterior capsule: The capsule of the lens from the lens equator forward.

anterior chamber: The space defined by the cornea and iris anteriorly and posteriorly. It is filled with aqueous humor.

anterior chamber angle: The anatomic zone between the cornea and the iris containing the trabecular meshwork.

arcus: Also known as arcus senilis. This refers to peripheral clouding of the cornea due to lipid (cholesterol) near the limbus in what would normally be clear stroma. The density may make it difficult to determine the depth of the arcus. It generally causes peripheral clouding.

arcuate keratotomy: An arc shaped incision in the cornea which is used to correct astigmatism.

astigmatism: The shape variation in the cornea which causes it to be curved more in one direction than another (shaped more like a football than a basketball).

Bowman's layer: The acellular stromal tissue between the cellular corneal stroma and the basement membrane of the epithelial cells.

CSVC: Corneal Storage and Viewing Chamber. A container used to store donor corneas and also view them for specular microscopy.

canthus: The inner or outer corner where the eyelids meet. The medial canthus is the juncture of the lids near the nose. The lateral canthus is the juncture of the lids near the ear.

caruncle: The small conjunctival membrane at the medial canthus that also has sebaceous glands and occasionally fine hairs.

cataract: A change in the lens proteins which causes a decrease in its clarity. This can occur in the nucleus (innermost part / nuclear cataract, nuclear sclerosis), cortex (middle part / cortical cataract, cortical spokes) or in the zone just inside the capsule (the outermost membrane / subcapsular cataract)

choroid: The layer between the retina and sclera which contains many large and small blood vessels as well as Bruch's membrane. It is supplied by the ciliary circulation from the ophthalmic artery. It supplies the metabolic nutrients to the retina.

cilia: The eyelashes which grow from the skin side of the lid margin.

ciliary body: A structure of muscular and glandular tissue at the peripheral base of the iris. It produces aqueous fluid, can contract to cause front to back thickening of the lens for close focusing, and extends from the root of the iris to approximately the pars plana.

conjunctiva: The thin clear mucosal membrane that contains blood vessels, nerves and glands. It attaches at the limbus, allows the eye to move, and separates the inner orbital structures from the outside.

cornea: The clear connective tissue membrane which assists in the focusing of light and provides a smooth anterior optical surface.

Descemet's fold: The protrusion caused by localized swelling along curved linear paths of the corneal stroma. The swelling forms a line or ridge referred to as fold in Descemet's. It represents thickening of the cornea which causes ridges to form internally at the level of Descemet's membrane, since the outer corneal surface cannot change (it is on maximal stretch to form the anterior corneal surface).

Descemet's membrane: The tough connective tissue membrane between the posterior corneal stroma and the endothelial cells. Descemet's can be repaired and regenerated by the corneal endothelium.

endothelium: The cells which form the innermost layer of the cornea. They prevent aqueous fluid from passing into the corneal stroma by actively pumping the fluid back into the anterior chamber. This prevents swelling and lack of clarity of the cornea. It is a single layer of cells that is not capable of reproducing itself. It produces, repairs and can regenerate Descemet's membrane.

endothelial striae: See snail tracks.

enucleation: Removal of the globe from a donor cadaver.

enucleation spoon: A spoon shaped instrument with a notch cut out for the optic nerve to allow elevation of the eyeball.

epithelium: The outer surface of the cornea, comprised of 5-6 layers of cells which replace themselves continuously. It takes approximately 7-14 days for the epithelial cells to mature from recent products of basal cell division to shedding superficial (surface) cells.

epithelial defect: The absence of a portion of the epithelial layer caused by trauma such as a corneal abrasion, infection or intrinsic disease.

evisceration: A procedure in which the contents of the globe are removed, leaving only the scleral shell behind.

excision: Removal of the corneal cap with a scleral rim of tissue from the globe. This can be done in-situ (from the donor cadaver itself) or in the laboratory (under a vertical laminar flow hood).

forceps: An instrument used to pick up tissue. These come in several varieties including smooth tipped, serrated or toothed, in order of increasing grasping and fixation ability.

fornix: The potential space between the lids and the globe. Normally this space doesn't exist because the lid is against the globe. If the lid is pulled away from the globe, the space can be seen, and is called the fornix.

gutta: The wart like excrescences of Descemet's which are the primary abnormality seen in Fuchs' endothelial dystrophy. Generally seen on specular reflection or specular microscopy. The plural is guttae. May be seen in literature as guttata (*s*) guttatae (*pl*).

hyperopia: The optical condition of the eye in which images come into focus behind (short eye) the retina, also known as far-sightedness.

IOL (intraocular lens implant): This refers to an anterior chamber lens implant (placed in front of the iris) or a posterior chamber lens implant placed in the capsular bag or between the capsular bag and the posterior iris/ciliary sulcus. Lenses can have an "optic" and "haptics". The optic is the central lenticular portion. The haptics are the small loops, either J, C, or a variety of closed shapes which hold the lens in position. In addition, both anterior and posterior chamber lens implants can be made in a plate form in which the optic is merely the central portion of a large plate of rigid or flexible plastic. Occasionally, these implants may be sewn to the iris or sclera.

icterus: The presence of excessive bilirubin, a compound which the body produces during the breakdown of hemoglobin, at a high level in the blood. This causes a yellowish discoloration of the skin. It is synonymous with jaundice.

infiltrate: The presence of white blood cells which accumulates in the cornea as an inflammatory response to infection, exposure or other stimuli. It usually appears as a white, grey, or slightly yellowish spot in the corneal epithelium or stroma.

in-situ: The term used in eye banking to mean that a component of the eye, the corneo-scleral rim, is removed without removing the globe.

iris: The color portion of the eye. It varies in color depending on the amount of pigment deposited on the iris membrane.

iris radial muscles: The spoke like muscles which contract to open the pupil.

iris sphincter: The round sphincter muscle which acts like a purse string to close the pupil.

jaundice: See icterus.

keratic precipitate: Also known as KP, they are the accumulation of white blood cells on the corneal endothelium which arise as a result of inflammatory reactions. They may be seen singularly or frequently as groups of multiple precipitates.

keratocyte: The basic cell type which is found in the corneal stroma. The keratocytes are sparse in distribution, occupying less than 5-10 % of the stroma.

keratoplasty: Any tissue-altering surgical procedure on the cornea.

lamellar keratomileusis: The reshaping of a partial thickness layer of the cornea done to change its refractive state.

lamellar keratectomy: The removal of a partial thickness layer of the cornea.

laminar-flow hood: A laboratory device which flows filtered air onto a specially enclosed work surface. Typically, eye banking uses vertical flow hoods, which projects clean filtered air down onto the work surface. This prevents particulate and microbial contamination, while protecting the technician from the potential exposure to infectious material being handled.

lateral canthus: The angle formed by the joining of the lids furthest from the midline or closest to the ear.

lens: The crystalline protein structure, which is normally flexible to allow focusing in the early years of life. Later, it becomes less flexible, may be cloudy (cataractous) and require removal.

lens cortex: The relatively soft lens material just inside the capsule.

lens nucleus: The inner, harder portion of the lens which has several layers.

lid margin: The lower most edge of the upper lid or upper most edge of the lower lid which contains the opening of the meibomian glands. It is the location of the junction of the skin and mucous membranes (mucocutaneous junction).

limbus: The juncture between the cornea and sclera. It is not a separate anatomical structure, but is defined as an anatomical transition zone.

medial canthus: The angle of the eyelid opening nearest to the midline or nasal side.

meibomian gland: The sebaceous/oil glands within the eyelid tarsal plates. They release oil onto the surface of the eye which forms the surface layer of the tear film, preventing evaporation.

meibomian gland orifices: The opening of the sebaceous/oil glands within the eyelid which anatomically open to the lid margin.

muscle hook: An “L” shaped instrument that is used to locate and grasp eye muscles.

myopia: The optical condition of the eye in which images come into focus in front of the retina (long eye), also known as near-sightedness.

oblique muscles: There are two oblique muscles, the superior and inferior. The superior arises above and medial to the optic foramen, but tracks forward to a small pulley, the trochlea, in the superonasal orbit. It then tracks under the superior rectus muscle, back to the superotemporal posterior globe to insert near the optic nerve. It causes the eye to move downward and laterally on contraction. The inferior oblique originates from behind the lower orbital margin, tracks posteriorly, between the inferior rectus and the floor of the orbit, under the lateral rectus, and inserts laterally and posteriorly on the globe. It tracks forward and attaches near the orbital rim. Contraction causes the eye to look upward.

PK: See penetrating keratoplasty

pars plana: The anatomic zone between the ending of the ciliary body posteriorly and the retina anteriorly.

penetrating keratoplasty: The procedure in which a full thickness button of cornea is removed from the recipient and replaced with a similar sized or larger button of tissue from a donor.

photorefractive keratectomy: Laser assisted removal of part of the anterior corneal stroma to change the refractive state of the eye.

phototherapeutic keratectomy: Laser assisted removal of part of the anterior corneal stroma to remove scar tissue from the cornea.

pinguecula: The abnormal growth of conjunctival tissue which occurs in the three or nine o'clock meridians at the limbus, but does not cross the limbus.

pleomorphism: Variation of endothelial cell shape, also known as pleomorphism

polymegathism: Variation of endothelial cell size.

polymorphism: . see pleomorphism

posterior capsule: The capsule of the lens from the lens equator posteriorly.

posterior chamber: The portion of the eye posterior to the iris.

pre-corneal tear film: The combination of the mucous which adheres to the cornea, the aqueous tears or water like tears that coat the mucous and the oily tears that float on top of the aqueous tears. It helps to provide a smoothing of the corneal surface and optical clarity as well as lubrication.

pseudoguttae: Dark spots on the endothelium seen while the cornea is cold which disappear when the cornea is warmed to room temperature.

pterygium: The abnormal growth of conjunctival tissue which occurs in the three or nine o'clock meridians at the limbus, which crosses the limbus and grows onto the cornea.

puncta: The opening of the lacrimal drainage system which passively or actively allows tears to drain from the eyelid surface.

pupil: The opening in the iris which changes in size with response to different light levels. It is similar to the aperture in a camera.

radial keratotomy: A surgical procedure in which four, six, eight or more radial incisions are made in the cornea to reduce myopia.

rectus muscles: The muscles which act directly up and down or right and left. There are four rectus muscles, the superior, medial, inferior and lateral.

retina: The membrane which consists of the nerves, pigment layer photoreceptors and supporting cells that sense the reception of light within the eye.

ring scissors: A scissors which has ring like ends to put your fingers through.

rosette: The pattern formed when a small endothelial cell is surrounded by larger nearest neighbor cells, making it appear flower like.

scar: Fibrous tissue replacing the normal tissue destroyed by injury or disease. The size, density and depth of the lesion should always be mentioned in any evaluation. . Any opacity or irregularity of the cornea which cannot be readily identified as normal anatomy may be included under this term.

semilunar fold: One of the folds of conjunctiva that is the transition between the medial canthus caruncle and medial conjunctiva.

snail tracks: Also known as endothelial stress lines. See stress lines.

specular reflection: The procedure in which the endothelium may be viewed through the slit lamp.

speculum: An instrument that spreads tissue apart such as the eyelids to hold them open while a procedure is performed.

spring scissors: Scissors which are connected at the end away from the hinge by a spring. The scissors blades are closed by squeezing the handles together. The scissors open again when the handles are released.

stroma: The thick central layer of the cornea which is composed of a highly ordered matrix of collagen fibers. It provides most of the cornea's strength and optical clarity.

stress lines: Also known as snail tracks or endothelial striae, refer to linear opacities seen at the level of Descemet's endothelium. These represent areas where folding of the cornea has caused stretching of the endothelium and generally rupture of the endothelium and/or separation from Descemet's membrane.

striae: Grayish white lines within the stromal substance itself which are caused by swelling between layers of the corneal stromal collagen. This causes light to scatter from these areas of localized linear swelling and form "striae". These may occur anywhere at any depth throughout the stroma. Also see stress lines, snail tracks or endothelial striae.

tarsus: The cartilage like plate within the eyelids which harbors the meibomian glands and gives structural support to the lid.

Tenon's fascia: The connective tissue fascia which inserts at the limbus, between the conjunctiva and the sclera, and covers the globe and muscles. Also known as the episclera.

trabecular meshwork: The meshwork of tissue that allows aqueous fluid to flow from the anterior chamber into Schlem's canal which drains the fluid away from the eye.

trephine: A round cutting blade to either mark or cut tissue, such as the cornea or sclera.

uvea: The iris ciliary body and choroid.

zonules: The small fibers that attach the peripheral lens to the ciliary body.



Medical Standards

**The Eye Bank Association of America
Medical Standards - November 2003
Revision**

Table of contents

A1.000	Introduction and Purpose	147
	A1.100 Scope	147
B1.000	Accreditation	147
	B1.100 Eye Bank Inspection.....	148
C1.000	Personnel and Governance	148
	C1.100 Director	148
	C1.200 Medical Director.....	148
	C1.300 Technical Staff	149
	C1.400 Change in Governance.....	150
C2.000	Training, Certification, and Continuing Education of Technical Personnel...	150
C3.000	Facilities	150
	C3.100 Eye Bank Laboratory.....	151
	C3.200 Equipment, Maintenance and Cleaning	151
	C3.300 Instruments and Reagents.....	151
	C3.400 Procedures Manual	152
	C3.500 Satellite Laboratories.....	152
	C3.600 Infection Control and Safety	152
	C3.700 Waste Disposal.....	152
D1.000	Donor Screening	153
	D1.100 Screening of Donors.....	153
	D1.110 Tissue from donors with the following is potentially hazardous	153
	D1.120 Contraindications.....	153
	D1.200 Documentation on Donor Information.....	156
	D1.300 Method of Consent.....	157
	D1.400 Donor Age	157
	D1.500 Interval Between Death, Enucleation, Excision, and Preservation.....	157
	D1.600 Eye Maintenance Prior to Enucleation.....	157
	D1.700 Living Donors.....	157
E1.000	Procurement and Preservation Procedures	157
	E1.100 Enucleation Procedure	158
	E1.200 In situ and Laboratory Removal of the Corneoscleral Rim	158
	E1.300 Use of Short or Intermediate Term Preservation Medium	158
	E1.400 Long Term Preservation.....	158
	E1.500 Whole Globe Preservation	158
	E1.600 Scleral Preservation	158

F1.000	Tissue Evaluation	158
	F1.100 Gross Examination.....	159
	F1.200 Slit-lamp Examination	159
	F1.300 Specular Microscopy.....	159
G1.000	Quality Assurance	159
	G1.100 Quality Control.....	160
	G1.200 Testing.....	160
	G1.210 Microbiologic Culturing.....	160
	G1.220 Serologic Testing	160
	G1.230 HIV Screening	161
	G1.240 Hepatitis B Screening.....	161
	G1.250 Hepatitis C Screening.....	161
	G1.260 HTLV-I and HTLV-II Screening	161
	G1.270 Syphilis Screening.....	161
	G1.280 Non-Required Laboratory Results	161
	G1.290 Discordant Test Results	162
H1.000	Non-Surgical Donor Tissue	162
I1.000	Storage	162
J1.000	Labeling	162
K1.000	Distribution of Tissue	163
	K1.100 Review of Donor Medical History	163
	K1.200 Receivers of Tissue.....	163
	K1.300 Fair and Equitable System.....	163
	K1.400 Returned Tissue	163
	K1.500 Tissue Recall.....	163
L1.000	Documentation to Accompany Donor Tissue	163
	L1.100 Tissue Report Form.....	163
	L1.200 Package Insert Form	164
L2.000	Packaging, Sealing and Packing for Transport	164
M1.000	Eye Bank Records	164
	M1.100 Length of Storage	164
	M1.200 Confidentiality	165
	M1.300 Donor Screening Forms.....	165
	M1.400 Minimum Information to be Retained.....	165
	M1.500 Recipient Follow-Up Information	166
N1.000	Amendments	166
Index	167

EBAA MEDICAL STANDARDS

A1.000 Introduction and Purpose

These standards have been developed to assure consistently acceptable levels of quality, proficiency, and ethics in dealing with eye tissue for transplantation and define the minimum standards of practice in the procurement, preservation, storage, and distribution of eye tissue for transplantation and research, as determined by the ophthalmological medical community.

A1.100 Scope

These standards are intended to apply to any and all aspects of eye banking, to

- Identification and screening of donors
- Procurement of eye and corneal tissue
- Laboratory processing of tissue, including preservation and biomicroscopic examination of tissue
- Storage of tissue
- Distribution of tissue for transplantation, research and teaching

These standards shall be reviewed at least annually and revised as necessary to incorporate current research findings and improved clinical practice.

B1.000 Accreditation

In order for an eye bank to become an accredited member of the Eye Bank Association of America, it must comply with the EBAA Bylaws and the following:

1. Demonstrate compliance with EBAA Medical Standards.
2. Pass the site inspection by the EBAA Accreditation Board.
3. Demonstrate proficiency in all aspects of eye banking by procuring, processing and distributing (within the geographic territory it defines as its service area) at least 25 surgical corneas for penetrating keratoplasty annually and provide documentation of their performance.
4. Certify compliance with applicable Federal and State regulations.

Eye Banks applying for EBAA membership must complete the Membership Application. Pending approval of the EBAA Board of Directors, the applicant may be accepted for provisional EBAA membership and will be subject to an on-site inspection within one year. A provisional member eye bank must complete the accreditation process within one year after obtaining provisional status in the EBAA. Any provisional member eye bank failing to complete the accreditation process after a site inspection will have until the time of the next meeting to correct deficiencies and satisfy accreditation EBAA Medical Standards-July 2003 requirements. If, at the end of this period, the provisional member eye bank fails to meet accreditation standards, it may not proceed to full membership with voting rights. Once accredited, an eye bank must be inspected and reaccredited at least every three years to maintain accreditation and voting membership in the EBAA.

B1.100 Eye Bank Inspection

The Accreditation Board of the EBAA shall be responsible for inspecting member Eye Banks as outlined in the written procedures of the Board.

Accreditation and reaccreditation site inspections shall be scheduled following written notification of the impending inspection. Unannounced inspections may be conducted should an allegation of violation of Medical Standards be made to the Accreditation Board, or should the results of inspections by official agencies indicate violation of Medical Standards. Failure to permit an inspection will result in suspension or revocation of an eye bank's accreditation.

Demonstration of proficiency in any and all aspects of eye banking may be required during the site inspection and of any or all technical personnel.

B1.200 Inspections by Official Agencies

Any written documentation of observations, findings, or results (including but not limited to FDA Form 483) received by an eye bank which are related to any inspection by an official agency shall be sent to the Chair of the Accreditation Board within ten (10) business days of receipt. The Chair of the Accreditation Board shall be copied on all future related correspondence.

C1.000 Personnel and Governance

C1.100 Director

All policies and procedures of each eye bank shall be under the supervision of a Director appointed by the eye bank's Board of Directors, Board of Regents or other governing body. The Director shall be responsible for all administrative operations including compliance with these standards.

The Director shall be the individual responsible for the day-to-day operation of the Eye Bank. It is this individual's responsibility to carry out policies of the Eye Bank's Board, to determine what tissues are to be collected, and to prescribe clinically acceptable means for their processing, quality control, storage and distribution.

The Director, if not a physician, shall consult with the Medical Director, as well as other medical and legal authorities, in carrying out prescribed responsibilities as necessary. These consultations shall be documented and made available for EBAA Medical Standards-July 2003 review during a site inspection.

The Director shall provide all staff members with adequate information to perform their duties safely and competently. Delegation of responsibility for the clinical work of the eye bank shall be as follows:

C1.200 Medical Director

The Eye Bank must have a Medical Director. When the Medical Director is not available, a back-up Medical Director shall be designated who is capable of fulfilling the responsibilities of the Medical Director on an interim basis.

The Medical Director must be an ophthalmologist who has completed a corneal fellowship or who has demonstrated expertise in external eye disease, corneal surgery, research or teaching in cornea and/or external disease. If the Medical Director has not served a corneal fellowship, then the eye bank must have and document a consulting relationship with an ophthalmologist who has.

Each Medical Director and co-directors of each member eye bank or physician of a non-member bank who provides verification of competency for tissue procurement and preservations, shall attend the Medical Directors' Symposium at the annual meeting of the EBAA at least once every three years and a Medical Advisory Board meeting once every three years. A newly appointed Medical Director shall attend a Medical Directors' Symposium and a Medical Advisory Board Meeting within one year of appointment, unless a Co-Medical Director has fulfilled the requirement. The eye bank shall provide written documentation of such attendance at the time of the eye bank site inspection.

The Medical Director shall oversee and provide advice on all medical aspects of the Eye Bank operations. These include but are not limited to:

1. Formulation, approval, and implementation of medical policies and procedures.
2. Participation in training and oversight of technical staff with regard to tissue procurement, tissue preservation and tissue evaluation.
3. Participation in establishment and operation of a quality assurance program.
4. Responsibility for verification of competency for tissue procurement and preservation by personnel applying for CEBT certification.

The Medical Director may delegate responsibility for tissue procurement, preservation, and tissue evaluation to qualified eye bank personnel; however, the Medical Director shall ensure that the eye bank operates in compliance with the EBAA Medical Standards. Ultimate responsibility for the suitability of each tissue for the transplantation in patients rests with the transplanting eye surgeon.

An eye bank has three months to replace a Medical Director who has resigned.

C1.300 Technical Staff

The Director shall appoint technical staff and ensure that staff has the appropriate qualifications and training for the performance of their job responsibilities. The Director shall ensure that there are a sufficient number of qualified eye bank technicians and supportive technical staff to promptly and proficiently perform all eye bank laboratory tests and procedures.

Each eye bank must have at least one EBAA certified technician in a supervisory role. If the medical director fulfills this role, he or she must pass an EBAA Technician Certification exam and maintain that certification. For non-certified technicians, the eye bank Executive Director or Medical Director must designate in writing those nonphysician technicians who are qualified and authorized to perform eye bank laboratory procedures.

An eye bank has six months in which to replace the EBAA certified eye bank technician in a supervisory role. The EBAA office and the Chair of the Accreditation Board shall be notified in writing of the lack of an EBAA certified technician in a supervisory position. If a six month deadline cannot be met, an extension can be granted under the following circumstances:

- a) the eye bank submits appropriate evidence of its intent to comply with this standard,
- b) a consulting relationship is established with the Technical Director (CEBT) of an accredited eye bank, and
- c) the non-CEBT technician in charge in the interim has demonstrated satisfactory proficiency to the eye bank's Medical Director.

C1.400 Change in Governance

An eye bank that undergoes a change in governance must notify the EBAA office and the Chair of the Accreditation Board (in writing) within 30 days. Changes in governance include merger of eye banks, affiliation of two or more eye banks, affiliation of an eye bank with another non-eye bank organization (E.G. tissue banks, organ procurement organizations, hospitals, blood banks, etc.), a change in the name of the eye bank, or a change in required personnel, i.e. Director, Medical Director.

C2.000 Training, Certification, and Continuing Education of Technical Personnel

An eye bank must provide an orientation program for each new technician and the employee's participation must be documented.

An eye bank must provide educational opportunities such as in-service training programs, attendance at meetings, seminars, and workshops for all technical personnel, including laboratory supervisors, at a frequency that is defined and reasonable for the size and needs of the technical staff.

For an eye bank technician to receive EBAA Certification, he or she must pass the EBAA Technician Certification examination. To sit for the examination, the eye bank technician must be employed by a transplant organization and be recommended by the Executive Director or a physician meeting the requirements of a medical director, as outlined in Section C1.200. A passing grade in the written exam will result in EBAA certification, provided that the appropriate fees have been paid. An EBAA certified technician must renew his or her certification at least once every three years by documenting the specified minimum number of continuing education units (CEU's) which have been approved by the EBAA Continuing Education Committee. To maintain certification, a technician must attend an EBAA meeting at least once every three years.

All EBAA accredited eye banks must have one Certified Eye Bank Technician (CEBT) attend an EBAA sponsored skills workshop once every three years. Each eye bank shall institute and document an in-house technician skills review and training for all technical staff on an annual basis.

C3.000 Facilities

Each eye bank must have sufficient space, equipment and supplies to perform the volume of laboratory services with optimal accuracy, efficiency, sterility, timeliness and safety. The EBAA office and the Chair of the Accreditation Board shall be notified of the relocation of an eye bank.

C3.100 Eye Bank Laboratory

The laboratory must be a separate area with limited access in which activities directly related to eye banking are carried out. The laboratory shall have a sink with a drain and running water. There must be adequate counter space for preparation of donor material. The room including walls, floor and sink must be kept clean at all times. Appropriate documentation of regular laboratory cleaning schedules must be maintained and kept on file for a minimum of three years.

Each eye bank laboratory must have an adequate stable electrical source and a sufficient number of grounded outlets for operating laboratory equipment.

C3.200 Equipment, Maintenance and Cleaning

Each eye bank laboratory shall have a refrigerator with a device, visible without opening the refrigerator, for recording temperature variations. The temperature recording device should reflect the temperature of the stored tissue under normal storage conditions. Temperature variations must be recorded daily and remain within the range of 2 to 60 Celsius. These records must be kept for a minimum of three years. The refrigerator's continuous temperature recorder must be calibrated against an NIST standard thermometer (or for Eye Banks outside the U.S.A., a standard thermometer as defined by their countries' regulatory agencies) at least once a year. The refrigerator shall be maintained for the use of tissue and tissue storage media and must contain clearly defined and labeled areas for all tissue stored, i.e., quarantined tissue, surgical tissue awaiting distribution, and research tissue. Eye banks must detail required refrigerator cleaning intervals and documentation in their Policies and Procedures manual.

A laminar airflow cabinet or hood is required for the preservation of any ocular tissue in the laboratory. The LFH must be cleaned before and after each use and at regularly scheduled intervals to prevent cross contamination.

In the event of a power failure, there must be provision for immediate notification and action to be taken, which may include an emergency power supply to maintain essential refrigeration.

Appropriate maintenance and accreditation records must be maintained on each piece of equipment. These records must show dates of inspection, performance evaluations and any maintenance procedures or repairs performed. These records must be kept at least three years.

The eye bank must include in its procedures manual, the monitoring, inspection and cleaning procedures and schedules for each piece of equipment. Documented cleaning schedules for laboratory equipment must be kept on file for a minimum of three years.

C3.300 Instruments and Reagents

Adequate instrumentation must be available to provide for sterile removal of whole eyes and corneas. Instruments must be inspected frequently enough to assure that they function properly. An eye bank that uses autoclave to sterilize its instruments shall adhere to the maintenance procedures for autoclaves as recommended in the Association for the Advancement of Medical Instrumentation (AAMI) Standard 42:1998—"Steam sterilization and sterility assurance using table-top sterilizers in office-based, ambulatory-care, medical, surgical, and dental facilities. The eye bank must outline these steps in its procedure manual. The solution used to clean the

autoclave shall be recommended by the CDC. Annual certification to validate temperature, pressure and time shall be performed and documented. Records of all of the above activities shall be documented and retained for at least three years. If instruments are sterilized outside of the eye bank, the eye bank shall provide documentation of appropriate sterilization.

All sterilized instruments, supplies and reagents, such as corneal preservation medium, must contain sterilization dates, method or appropriate expiration dates that are current at all times if applicable.

C3.400 Procedures Manual

Each eye bank shall maintain its own procedures manual that details all aspects of its specific retrieval, processing, testing, storage, distribution, and quality assurance practices. Each procedure must be initially approved, signed, and dated by the Director and Medical Director. An annual review of each eye bank's procedure with signing and dating by the Director and Medical Director is required. Each eye bank must maintain copies of each procedure it uses and the length of time the procedure was in use.

C3.500 Satellite Laboratories

Satellite laboratories that either process or distribute tissue must have a certified technician and be supervised by and have access to a qualified Medical Director or his/her delegate. Such satellite laboratories must be inspected as part of the accreditation process of the parent bank.

C3.600 Infection Control and Personnel Safety

Written safety procedures for the eye bank operation shall be established in compliance with the Occupational Safety and Health Act (OSHA Act) of 1970 and the 1991 amendments to Part 1910 of title 29 of the Code of Federal Regulations, Subpart Z and/or applicable state statutes, which may supersede. For Eye Banks where OSHA regulations do not apply, written safety procedures in compliance with the relevant regulatory agencies are an acceptable substitute. All eye bank personnel must operate under the current Universal Precautions for health care workers issued by the Centers for Disease Control (CDC) of HHS.¹ These written procedures must be included in the eye bank's procedure manual.

C3.700 Waste Disposal

Human tissue and waste items shall be disposed of in such a manner as to minimize any hazard to Eye Bank personnel and the environment and to comply 1 On December 6, 1991, the Occupational Safety and Health Administration (OSHA) of the U.S. Department of Labor (DOL) published its final rules regulating worker occupational exposure to bloodborne pathogens, including but not limited to hepatitis B virus (HBV) and human immunodeficiency virus (HIV). These regulations went into effect March 6, 1992, and make employers responsible for providing and ensuring safe working conditions in all work settings. See the December 6, 1991, Federal Register, Vol. 56, no. 235. with state and federal regulations. Dignified and proper disposal procedures shall be used to obviate recognizable human remains and must be documented.

D1.000 Donor Screening

All donors must be identified by name. All prospective donors shall undergo a thorough physical examination as close as possible prior to donation with special attention to physical signs of HIV disease, infectious hepatitis, and injecting drug use. Each eye bank shall have a consistent policy for conducting and documenting this examination. Each eye bank shall also have a consistent policy for examination and documentation of the prospective donor's available medical record and death investigation. Review of all available records on each donor shall be performed by an individual who is qualified by profession, education, or training to do so, and who is familiar with the intended use of the tissue.

Medical and social history are important aspects of donor evaluation. Adequate donor evaluation includes:

- (1) serologic testing (see Section G1.200)
- (2) physical assessment of the donor (see above paragraph)
- (3) tissue evaluation (see F1.000)
- (4) donor history evaluation: this must include the donor's name and donor information obtained from at least one of the following:
 - a) pathologist or medical examiner physical assessment of death report
 - b) police investigation report (accompanied by a and/or c)
 - c) medical examiner's investigative report
 - d) family interview
 - e) medical record or hospital chart
 - f) treating physician interview
- (5) medical director oversight to review any donor information where questions arise in the above areas (C1.200). This shall be documented.

D1.100 Screening of Donors Must be Conducted for the Following:

D1.110 Tissue from donors with the following is potentially hazardous to eye bank personnel and requires special handling:

- Active Viral Hepatitis
- Acquired Immunodeficiency Syndrome (AIDS) or HIV seropositivity
- Active viral encephalitis or encephalitis of unknown origin
- Creutzfeldt-Jacob Disease
- Rabies

D1.120 Contraindications

Tissue from donors with the following are potentially health threatening for the recipient(s) or pose a risk to the success of the surgery and shall not be offered for surgical purposes:

- A. Penetrating Keratoplasty
 1. Death of unknown cause
 2. Creutzfeldt-Jakob disease (CJD), variant Creutzfeldt-Jakob Disease (vCJD), or family member with CJD
 3. Death with neurologic disease of unestablished diagnosis
 4. Dementia, unless due to cerebrovascular disease, brain tumor, or head trauma. Donors with toxic or metabolic-induced-dementia may be acceptable pending

-
-
- documentation of consultation with the Medical Director. The approval of the Medical Director is required.
5. Subacute sclerosing panencephalitis
 6. Progressive multifocal leukoencephalopathy
 7. Congenital rubella
 8. Reyes Syndrome
 9. Active viral encephalitis or encephalitis of unknown origin or progressive encephalopathy
 10. Active septicemia (bacteremia, fungemia, viremia)
 11. Active bacterial or fungal endocarditis
 12. Active viral hepatitis
 13. Rabies
 14. Intrinsic eye disease
 - a. Retinoblastoma
 - b. Malignant tumors of the anterior ocular segment or known adenocarcinoma in the eye of primary or metastatic origin
 - c. Active ocular or intraocular inflammation: conjunctivitis, keratitis, scleritis, iritis, uveitis, vitreitis, choroiditis, retinitis
 - d. Congenital or acquired disorders of the eye that would preclude a successful outcome for the intended use, e.g., a central donor corneal scar for an intended penetrating keratoplasty, keratoconus, and keratoglobus
 - e. Pterygia or other superficial disorders of the conjunctiva or corneal surface involving the central optical area of the corneal button
 15. Prior intraocular or anterior segment surgery
 - a. Refractive corneal procedures, e.g., radial keratotomy, lamellar inserts, etc.
 - b. Laser photoablation surgery is allowed to be used in cases of tectonic grafting and posterior lamellar procedures.
 - c. Corneas from patients with anterior segment (e.g., cataract, intraocular lens, glaucoma filtration surgery) may be used if screened by specular microscopy and meet the Eye Bank's endothelial standards.
 - d. Laser surgical procedures such as argon laser trabeculoplasty, retinal and panretinal photocoagulation do not necessarily preclude use for penetrating keratoplasty but should be cleared by the medical director.
 16. Leukemias
 17. Active disseminated lymphomas
 18. Hepatitis B surface antigen positive donors (as specified in Section G1.230)
 19. Recipients of human pituitary-derived growth hormone (pit-hGH) during the years from 1963-1985
 20. HTLV-I or HTLV-II infection
 21. Recipient of non-synthetic dura mater graft
 22. Hepatitis C Seropositive donors
 23. HIV Seropositive donors (as specified in Section G1.220)
 24. HIV or high risk for HIV: Persons meeting any of the following criteria should be excluded from donation:

Behavioral/History Exclusionary Criteria: (FDA Guidance for Industry, July 1997)

- a. Men who have sex with another man in the preceding 5 years.
- b. Persons who have injected drugs for a nonmedical reason in the preceding 5 years including intravenous, intramuscular, or subcutaneous injection of drugs.
- c. Persons with hemophilia or related clotting disorders who have received human-derived clotting factor concentrates.
- d. Men and women who have engaged in sex for money or drugs in the preceding 5 years.
- e. Persons who have had sex in the preceding 12 months with any person described in items a-d above or with a person known or suspected to have HIV, hepatitis B, or hepatitis C virus infection.
- f. Persons who have been exposed in the preceding 12 months to known or suspected HIV, HBV and/or HCV-infected blood through percutaneous inoculation or through contact with an open wound, non-intact skin, or mucous membrane.
- g. Inmates of correctional systems (including jail and prisons) and individuals who have been incarcerated for more than 72 consecutive hours during the previous 12 months.
- h. Persons who have had close contact with another person having viral hepatitis within the 12 months preceding donation.
- i. Persons who have had or have been treated for syphilis or gonorrhea during the preceding 12 months.
- j. Persons within the last 12 months of donation have undergone tattooing, acupuncture, ear or body piercing in which shared instruments are known to have been used.

Specific Exclusionary Criteria for Pediatric Donors:

- k. Children meeting any of the exclusionary criteria listed above for adults should not be listed as donors.
- l. Children born to mothers with HIV infection or mothers who meet the behavioral or laboratory exclusionary criteria for adult donors (regardless of their HIV status) should not be accepted as donors unless HIV infection can be excluded in the child as follows:
Children >18 months of age who are born to mothers with or at risk for HIV infection, who have not been breast fed within the last 12 months, and whose HIV antibody tests, physical examination, and review of medical records do not indicate evidence of infection can be accepted as donors.
- m. Children ≤18 months of age who are born to mothers with or at risk for HIV infection or children of mothers with or at risk of HIV infection who have been breast fed within the past 12 months should not be accepted as donors regardless of their HIV tests results.

Laboratory and Other Medical Exclusionary Criteria:

- n. Persons who cannot be tested for HIV infection because of refusal, inadequate blood samples (e.g. hemodilution that could result in false-negative tests), or any other reason.
- o. Persons with repeatedly reactive screening assay for HIV-1 or HIV-2 antibody regardless of the results of the supplemental assays.
- p. Persons whose history, physical examination, medical records, or autopsy reports reveal evidence of:
 - HIV infection or high-risk behavior, such as a diagnosis of AIDS, unexplained weight loss, night sweats, blue or purple spots on the skin or mucous membranes typical of Kaposi's sarcoma, unexplained lymphadenopathy lasting >1 month, unexplained temperature >100.5 F

(38.6 C) for >10 days, unexplained persistent diarrhea, unexplained persistent cough or shortness of breath, or opportunistic infections.

- Hepatitis B or C infection, which could include clinical signs and symptoms of hepatitis such as unexplained yellow jaundice or hepatomegaly (record of laboratory data such as alanine aminotransferase (ALT), aspartate aminotransferase (AST), Bilirubin or prothrombin time may assist in making a donor suitability determination).

25. Smallpox Vaccine Exclusionary Criteria

a. Smallpox vaccination without complications

Potential donors who received the smallpox vaccine without complications shall be deferred until after the vaccination scab has separated and the vaccination site appears to be healed and not inflamed, or for 21 days post-vaccination, whichever is the later date.

b. Smallpox vaccination with complications that have resolved

Potential donors who received the smallpox vaccine and developed complications that have resolved shall be deferred for 14 days after all vaccine complications have completely resolved, or for 21 days post-vaccination, whichever is the later date.

c. Smallpox vaccination with complications that have not resolved

Potential donors who received the smallpox vaccine and developed complications that have not resolved shall be deferred.

d. Symptomatic contacts of recipients of smallpox vaccine

Potential donors who have had contact with someone who has received the smallpox vaccine shall be deferred in cases where the donors have had recognizable signs or symptoms attributable to the virus within 14 days prior to donation.

B. Lamellar or Patch Grafts

Criteria are the same as listed for penetrating keratoplasty except that tissue with local eye disease affecting the corneal endothelium or previous ocular surgery that does not compromise the corneal stroma, e.g., aphakia, iritis, is acceptable for use.

C. Epikeratoplasty

Criteria are the same as listed for penetrating keratoplasty except that tissue with local eye disease affecting the corneal endothelium, e.g., aphakia, iritis, is acceptable for use. Death to preservation time may be extended.

D. Scleral Tissue

Criteria are the same as listed for penetrating keratoplasty except that tissue with local eye disease affecting the corneal endothelium, e.g., aphakia, iritis, is acceptable for use. Death to preservation time may be extended.

D1.200 Documentation on Donor Information

Donor screening forms and/or copies of medical charts, medical examiner or coroner review forms and gross autopsy results must be completed and retained on all donated eye tissue as part of the donor record. See Section L1.000.

A unique donor identifying number, i.e., medical examiner or coroner case number, hospital medical record number, social security or driver's license number, shall be obtained and recorded in the donor record.

D1.300 Method of Consent

Documentation of legal consent for enucleation or in situ excision is essential for medical-legal reasons. Consent procedures and forms must conform with state law and documentation for consent must be retained. In medical examiner's/coroner's cases, the eye bank shall adhere to the consent regulations specified by the medical examiner's or coroner's legislation in its state. In each case the consent designation and restrictions, if any, must be adhered to and cannot be altered without the witnessed resigning or redesignation of the legally appropriate consentor.

D1.400 Donor Age

Since no definite relationship has been established between the quality of donor tissue and age, the upper and lower age limit is left to the discretion of the Medical Director.

D1.500 Interval Between Death, Enucleation, Excision and Preservation

Acceptable time intervals from death, enucleation or excision to preservation may vary according to the circumstances of death and interim means of storage of the body. It is generally recommended that corneal preservation occur as soon as possible after death. All time intervals for each donor, i.e., the time of death to the time of enucleation and preservation and/or the time to corneal excision, shall be recorded. If the donor has been refrigerated prior to enucleation or in situ corneal excision, this information shall be noted. The time that cooling of ocular tissues and/or refrigeration of the body was begun shall be recorded.

D1.600 Eye Maintenance Prior to Enucleation

The prospective donor's corneal integrity should be maintained. Recommended procedures for eye maintenance shall be found in the procedures manual. Each individual eye bank's procedure is left to the discretion of the Medical Director and shall be clearly documented.

D1.700 Living Donors

Eye tissue that is removed and processed for surgical use from a living donor shall have the same standards applied as for all cadaveric tissue, e.g., the same donor medical history shall be obtained, the same records, serology, etc. No extended quarantine period, outside the usual 24-48 hours for serology results, shall be required for corneal tissue used for transplantation that is stored in short or immediate term culture medium.

E1.000 Procurement and Preservation Procedures

Specific procurement procedures can be found in the EBAA Procedures Manual. EBAA Procedures Manual is used as a Guidance Document. This manual is periodically reviewed and modified as necessary by the Technician Education Committee. Revisions and modifications are approved by the Medical Advisory Board. The Medical Director and Director are responsible for assuring that eye bank personnel comply with all applicable procedures for the procurement and preservation of tissue.

E1.100 Enucleation Procedure

Ultimate responsibility for personnel to perform enucleation rests with the Director, the Medical Director and existing state law.

E1.200 In Situ and Laboratory Removal of Corneoscleral Rim

Removal of the corneoscleral rim shall be performed using sterile technique by individuals specifically trained in in situ retrieval and/or laboratory removal of the corneoscleral segment. Laboratory removal must be performed with a laminar air flow hood or cabinet which meets either Federal Standard 209(b) as a Class 100 Hood or National Sanitation Foundation (NSF) Standards as a Class II or Class III cabinet, or in an operating room. For in situ corneal removal, the eye shall be examined with the use of a penlight prior to excision.

E1.300 Use of Short or Immediate Term Preservation Medium

Eye Banks shall use an appropriate corneal storage medium that has been manufactured in accordance with FDA Good Manufacturing Practices. The medium shall be used and stored according to the manufacturer's recommendations for temperature, date and other factors. The manufactured medium purchased and shipped to the eye bank shall be inspected for damage upon arrival. The lot number of medium used for each cornea shall be recorded on the tissue report containing the unique I.D. number of the tissue to allow tracking and recall.

E1.400 Long Term Preservation

Some eye banks employ long-term preservation of corneal tissue, such as organ culturing. While these methods are not in widespread use, an eye bank that uses long-term preservation shall carefully document the procedure in their procedures manual, and adhere to rigid aseptic technique

E1.500 Whole Globe Preservation

Eye banks that preserve and store whole eyes for lamellar or refractive keratoplasty shall employ aseptic practice using one of the preservation methods such as moist chamber at 2-6 degrees Celsius, frozen at 0 degrees Celsius, or some other method approved by the eye bank's Medical Director. Details of the preservation method must be documented in the eye bank's own procedures manual.

E1.600 Scleral Preservation

There are various methods of preserving sclera, including the use of 70% or greater ethyl alcohol, sterile glycerin, and cryopreservation. Eye banks shall preserve sclera tissue aseptically, using one of these methods. Details of the preservation method must be documented in the eye bank's own procedures manual. A preservation date for scleral tissue shall be indicated.

F1.000 Tissue Evaluation

The ultimate responsibility for determining the suitability of the tissue for transplantation rests with the transplanting surgeon.

F1.100 Gross Examination

The corneal-scleral segment shall be initially examined grossly for clarity, epithelial defects, foreign objects, contamination and scleral color, e.g., jaundice.

F1.200 Slit-lamp Examination

The cornea shall be examined for epithelial and stromal pathology and in particular endothelial disease. Eucleated whole globes shall be examined in the laboratory prior to distribution and/or corneal excision. If in situ corneal excision is performed, examination of the donor eye anterior segment with a penlight or a portable slit lamp is required. After corneal excision, the cornealscleral rim shall be evaluated by slit lamp biomicroscopy, even if the eye donor has been examined with the slit lamp prior to excision of the corneal-scleral rim, to insure that damage to the corneal endothelium or surgical detachment of Descemet's membrane did not occur.

Document that a slit lamp examination has been performed with particular attention to the epithelium, stroma, and endothelium such as but not limited to scars, edema, significant arcus, striae, epithelial defects, guttata, polymegathism, pleomorphism, infiltrates, or foreign bodies.

F1.300 Endothelial Cell Density

Determination of endothelial cell density via specular microscopy (or quantitative light microscopy for organ cultured corneas) shall be a standard method of corneal tissue evaluation at all member Eye Banks of the EBAA, effective December 2001. When it is impossible to obtain an endothelial cell count, this requirement may be waived on a case-by-case basis by the Medical Director.

G1.00 Quality Assurance

Each eye bank shall have a formally established quality assurance program. This program shall include ongoing monitoring and evaluation of activities, identification of problems and development of plans for corrective actions. The quality assurance program shall include a monthly review of environmental controls and equipment maintenance. These standards shall provide the basis for development of the QA program. Each eye bank shall document all aspects of its QA program and maintain records of all QA activities for a minimum of ten years. These include corrective or remedial action taken for detected deficiencies. These records shall be available for review at the time of site inspection.

The eye bank's quality assurance program shall include a method for the receiving surgeon to report adverse reactions from the transplantation of corneal, scleral, or other ocular tissue to the distributing eye bank. The distributing eye bank must forward the adverse reaction information to the source eye bank, which procured the tissue, which in turn, must forward the adverse reaction information within 30 days to the EBAA office for review by the Medical Advisory Board.

A reportable adverse reaction is any communicable or other disease transmitted by and attributable to transplantation of donor eye tissue, including infection (as manifested by endophthalmitis, keratitis or systemic viral disease) and biologic dysfunction (such as immediate endothelial failure, donor corneal dystrophy, or evidence suggestive of prior refractive surgery). If systemic infectious disease such as HIV, hepatitis or syphilis develops in a recipient, whether

or not it is suspected to be due to donor tissue, this must be reported to the EBAA. The Medical Director shall receive and review all adverse reaction reports, documenting any corrective actions he/she determines are indicated.

G1.100 Quality Control

The Director shall prescribe tests and procedures for measuring, assaying or monitoring properties of tissues essential to the evaluation of their safety for transplantation, e.g., hepatitis B surface antigen and human immunodeficiency virus (HIV) antibody, and conform with federal requirements as well as individual state laws. Results of all such tests or procedures, together with evaluations based on these findings, shall become part of permanent record of all tissues processed.

G1.200 Testing

Infectious disease testing shall be performed by a laboratory certified under the CLIA. Eye banks outside the U.S.A. must use a laboratory that is accredited by their own countries' regulatory agencies.

G1.210 Microbiologic Culturing

Culturing of Eye Bank donor eyes may be performed despite the recognition by many that bacteriologic contamination of donor eyes does not necessarily lead to infection and that presurgical or surgical cultures may not correlate with postoperative infection if it should occur. Cultures may be performed either before and/or at the time of surgery.

a. Presurgical Cultures

Eye Banks may elect to perform corneal-scleral rim cultures at the time of corneal preservation in tissue culture medium. Positive culture reports shall be reported to the receiving surgeon or recipient eye bank.

b. Surgical Culturing

Each eye bank shall indicate on the information sheet accompanying the tissue for transplantation whether corneo-scleral cultures were performed prior to distribution. Positive results in cases of postoperative infection shall be reported to the eye bank that procured the tissue as well as to the eye bank that distributed the tissue.

G1.220 Serologic Testing

Sections G1.230-G1.270 specify the EBAA required serologic tests which must be performed on each donor from which tissue is designated for surgical use. A hard copy of serological results shall be received by the eye bank prior to release of tissue designated for surgical use.

Plasma Dilution Donor Evaluation: Each eye bank shall document on each transplant donor whether blood loss was known or suspected as determined by the Medical Director or qualified designee and whether the donor received any infusion/transfusion of crystalloids and/or colloids and blood. An algorithm meeting FDA regulations shall be used to record infusion/transfusion volumes given to each donor within 48 hours prior to obtaining the blood sample for serologic testing on every donor with blood loss, and on every donor age 12 and under receiving any amount of infusion/transfusion preceding sampling.

-
-
1. If only colloids and/or crystalloids were administered, and if their total volume exceeds the donor's plasma volume, the sample is not suitable for testing.
 2. If only blood (whole blood and/or red blood cells) or a combination of blood, colloids, and crystalloids were administered, and if the volume exceeds the donor's blood volume, the sample is not suitable for testing.
 3. When a combination of blood, colloids, and/or crystalloids have been administered, following the calculation of all transfused/infused administration against blood volume, calculate the colloids/crystalloids against donor plasma volume. Reject the sample for testing if either of these calculations exceeds the appropriate volume.

Eye Banks outside of the U.S.A. shall use a plasma dilution algorithm which meets the requirements of their own countries' regulatory agencies. If no such requirements exist, they shall use an algorithm which meets FDA requirements.

Banked Autologous blood must be contained in a plasma dilution calculations, non-banked autologous blood need not be included.

G1.230 HIV Screening

All member eye banks must have operational an HIV-1/HIV-2 screening program using an FDA approved test for all donors of surgically designated tissue. To comply with FDA requirements, a negative screening test must be documented prior to release of tissue for transplantation. Eye Banks outside the U.S.A. must use a test approved by their own countries' regulatory agencies.

G1.240 Hepatitis B Screening

All member eye banks must have an operational hepatitis B screening program using an FDA approved test for hepatitis B surface antigen for all donors of surgically designated tissue. To comply with FDA requirements, a negative screening test must be documented prior to the release of tissue for transplantation.

G1.250 Hepatitis C Screening

All member eye banks must have an operational Hepatitis C screening program using an FDA approved test for all donors of surgically designated tissue. To comply with FDA requirements, a negative screening test must be documented prior to release of tissue transplantation. Eye Banks outside the U.S.A. must use a test approved by their own countries' regulatory agencies.

G1.260 HTLV-I and HTLV-II Screening

Donor screening for HTLV-I and HTLV-II is not required.

G1.270 Syphilis Screening

Serologic screening for syphilis is not required.

G1.280 Non-Required Laboratory Results

If laboratory results of non-required or conflicting serologic tests for infectious disease are reported for tissue for transplantation to the eye bank, they must be taken into account and/or acted upon by the medical director.

³ Eye Banks outside the U.S.A. must use a test approved by their own countries' regulatory agencies.

All member eye banks must report conflicting serologic test results to the consignee (i.e. the transplanting surgeon or distributing eye bank), the eye bank medical director, and the EBAA within 60 days.

G1.290 Tissue Recall and Tissue Withdrawal

Test results received after release of tissue that indicate a risk for HIV, hepatitis B, or hepatitis C must be reported to the eye bank medical director, the consignee (i.e. the transplanting surgeon or distributing eye bank), the EBAA, and the FDA within 60 days. Notification of the consignee constitutes a recall. The medical director is responsible for determining compliance with applicable standards and regulation.

Consignee notification of positive test results for pathogens other than HIV, hepatitis B, or hepatitis C constitutes a tissue withdrawal and does not require FDA notification.

H1.000 Non-Surgical Donor Tissue

If donor tissue is provided for purposes other than surgery, e.g., research, practice surgery, etc., and if that donor tissue is not screened for HIV or Hepatitis, a label stating that screening for HIV-antibody, Hepatitis B or Hepatitis C has not been carried out or stating “potentially hazardous biologic material” or some other designation acceptable under the guidelines of the CDC must be attached to the container used for the donor tissue storage and/or transport.

I1.000 Storage

All surgical tissue shall be stored in quarantine until results of HIV, HBsAg, HCV, and any other relevant donor screening tests have been recorded as non-reactive. All tissue shall be stored aseptically at a temperature appropriate to the method of preservation used. Eye banks must precisely document their procedures for storage of corneal tissue, whether it is in the form of the whole eye or the cornea only in an appropriate medium.

J1.000 Labeling

Each corneal or scleral tissue container shall be clearly and indelibly labeled to include at least the information below.

1. Name of source eye bank.
2. Tissue identification number. There must be a unique identification number for each ocular tissue or fraction thereof that is distributed for surgical use.
3. Type of tissue.
4. Date and time of donor’s death.
5. Date and time of corneal/scleral preservation.
6. Expiration date for scleral tissue and long-term preserved tissue.
7. A statement that the tissue is intended for single patient application only and that it is not to be considered sterile.
8. A statement that the tissue was procured from a donor who was non-reactive EBAA Medical when tested for HIV antibody, hepatitis B surface antigen (HbsAg), and hepatitis C antibody (HCV).
9. Type of preservation medium.

³The EBAA recognizes the use of neutralization assay or confirmatory tests as scientifically valid.

K1.000 Distribution of Tissue

K1.100 Review of Donor Medical History

Prior to distribution of tissue for transplantation, the Medical Director or his/her designee shall review and document that the medical and laboratory information is in accordance with medical standards.

K1.200 Receivers of Tissue

Tissue shall be distributed to physicians, dentists, institutions and other eye banks.

All tissue sent from EBAA accredited eye banks to eye banks in this or other countries must comply with the standards defined by the EBAA Medical Advisory Board.

K1.300 Fair and Equitable System

Eye banks shall establish and document a system of distribution that is just, equitable and fair to all patients served by the eye bank. Documentation of distribution (time and date of requests for, offers of, and delivery of eye tissue) shall be available for inspection by the Accreditation Board. Access to tissue shall be provided without regard to recipient sex, age, religion, race, creed, color or national origin.

K1.400 Returned Tissue

For corneas returned and redistributed, tissue transportation and storage information must be documented and made available to the eye bank and transplanting surgeon.

K1.500 Tissue Recall

Eye banks must have a policy and procedure for potential recall of tissue.

L1.000 Documentation to Accompany Donor Tissue

L1.100 Tissue Report Form

For special research studies, by recommendation of the Medical Advisory Board and approved by the EBAA Board of Directors, certain specific data may be masked on the tissue report form and label. A copy of the tissue report form and/or donor screening form shall accompany the tissue.

The tissue report shall contain the following:

Name of (Source) Eye Bank

Location of Eye Bank

Telephone Number of Eye Bank

Eye Bank identification number unique to each tissue graft

Type of preservation medium

Age of donor

Cause of death

Death date and time

Preservation date and time

The time that cooling of ocular tissues and/or refrigeration of the body was begun.

Name of technician who enucleated, excised, and evaluated the tissue

Slit lamp report/date

Specular microscopy report/date

EBAA Accreditation Status of Eye Bank

For a medical examiner tissue procured under legislative consent, a statement shall be added to advise the receiving surgeon that the tissue was determined to be suitable for transplantation in the absence of a donor medical history interview. A summary of records reviewed regarding the suitability of tissue for transplant as described in the FDA Final rule 1270.33(d).

L1.200 Package Insert Form

A "Package Insert" form that meets the EBAA requirements defined below shall accompany the tissue for transplantation. This form shall include the following:

1. Recommended storage temperature for specific type of tissue (cornea; sclera; whole globe). Specific emphasis on DO NOT FREEZE for corneas.
2. That the surgeon should check for integrity of the seal and immediately report to the eye bank any evidence of possible tampering.
3. For corneas in Optisol. That color change per the manufacturer's guidelines may indicate a change in pH, in which case the tissue should not be used and a report made immediately to the eye bank.
4. Whether pre-surgical microbiologic cultures were performed by the eye bank.
5. The form shall also advise the receiving surgeon that the tissues are delivered with no warranty as to merchantability or fitness for a particular purpose, and that the receiving surgeon is ultimately responsible for judging if the tissue is suitable for use.
6. Serologic tests were performed by a CLIA certified laboratory.
7. The U.S. Food and Drug Administration (FDA) approved tests used for serology are approved for pre-mortem blood and FDA approved tests for HIV-1, HIV-2, and HBs Ag for cadaveric blood.

This information may be included on the eye bank's donor screening form as long as it is easily noticed; otherwise a separate package insert form is advised.

L2.000 Packaging, Sealing and Packing for Transport

Each tissue shall be individually packaged and sealed with a tamper-evident seal.

Each eye bank shall use a validated packaging method so as to maintain the temperature of the tissue at an acceptable level while in transit. Packing shall be done so that the package insert and tissue label do not become wet. Special instructions shall be included on a Package Insert. See Section L1.200.

M1.000 Eye Bank Records

M1.100 Length of Storage

All records shall be kept for a minimum of ten years from the date of transplantation/implantation, distribution or whichever is longer.

In addition, minimum information to allow donor tissue to be connected to the recipient, shall be retained perpetually. This information shall include:

- Donor identification
- Donor source
- Cause of Death
- Serology results
- Recipient identification

M1.200 Confidentiality

All eye bank records and communications between the eye bank and its donors and recipients shall be regarded as confidential and privileged.

M1.300 Donor Screening Forms

Donor screening forms shall contain information regarding the circumstances surrounding the death of a donor and adequate medical history so that the suitability of the tissue for transplantation may be judged.

M1.400 Minimum Information to be Retained

Forms for retaining donor and recipient information shall be established for permanent record and shall be readily accessible for inspection by the EBAA Accreditation Board. Eye Bank records shall include the following minimum information:

See Section L1.000 for information to be included on the Tissue Report Form.

Eye bank identification number unique to each tissue graft

Name of eye bank

Type of preservation medium

Preservation media lot numbers

Unique donor identification number

Name of donor (or if import tissue, name of importing eye bank and their unique ID number)

Age of donor

Cause of death

Death date and time

Enucleation or in-situ excision date and time

Preservation date and time

The time that cooling of ocular tissues and/or refrigeration of the body was begun.

Slit lamp report

Specular microscopy (if done)

Name of enucleator/evaluator/technician

Name of surgeon receiving tissue

Recipient identification readily traceable to each unique graft number (See Section M1.500)

Date, time, method of transportation

Utilization of tissue: i.e., surgical, research, training

Printed results of all EBAA required serologic screening tests

Microbiologic screening results if performed

Microbiologic reports of positive donor rim cultures from the receiving surgeon if reported

Adverse reactions if reported

Documentation that three to twelve month follow-up has been sought

M1.500 Recipient Follow-Up Information

1. Each eye bank shall retain recipient information from each using surgeon on each surgically used tissue. This information shall be obtained and retained by the distributing eye bank.
2. This information shall include the following:
 - Patient's name
 - Unique identification according to the following order of preference:
 - Social security number
 - Driver's license number
 - Hospital information number
 - Alien identification
 - Passport number
 - Age
 - Date of Birth
 - Diagnosis
 - Name of surgeon receiving transplanting tissue
 - Date of surgery
 - Location of surgery
 - Post-operative complications (tissue related)
3. Scleral tissue may be stocked at an institution only if it is for single patient use; the distributing eye bank must be notified of the recipient information when tissue is used and must be able to track the tissue.
4. Between three and twelve months postoperatively, each eye bank must seek recipient follow-up information concerning possible adverse reactions on all tissue distributed.

N1.000 Amendments

These standards may be amended as required.

The Medical Advisory Board shall be charged with proposing amendments to these standards as medical technology, techniques and information require. A comment period may be provided prior to the intended effective date.

INDEX TO EBAA MEDICAL STANDARDS

Accreditation	1,2,4-7,20-23
Adverse Reactions	16,23-24
Amendments	24
Anterior segment surgery	9
Aseptic practice	14
Bacteriologic contamination	17
Biomicroscopic examination	1
Blood volume	17
Cataract	9
CDC	6,7,19
Certified technician	4,5,7
Choroiditis	9
Clarity	15
Cleaning	5,6
CLIA	17,22
Colloids	17
Confidential	22
Congenital rubella	9
Conjunctivitis	9
Consent	12,13,21
Contraindications	9
Coroner	12,13
Creutzfeldt-Jacob	8,10
Crystalloids	17
Disseminated lymphomas	10
Distribution	1,2,6,7,15,17,20,22
Documentation	1-3,5-9,12,13,20,21,23
Donor age	13,17
Donor information	8,12
Donor screening	8,12,18,19,21,22,23
Encephalitis	8,9
Endocarditis	9
Enucleation	13,14,23
Epikeratoplasty	12
Epithelial	15
Equipment	5,6
Ethics	1
Exclusionary criteria	10,11
Executive Director	2,4,5,7,14,16
Eye bank records	22,23
Eye maintenance	13

Facilities	5,6
FDA	2,10,14,17-19,21,22
Federal requirements.....	16
Federal Standard 209(b)	14
Glaucoma filtration.....	10
Gross examination	15
HCV	10,19,20
Hepatitis	8-12,16,18-20
Hepatitis B.....	7,10,12,16,18-20
Hepatitis B surface antigen	10,16,18,20
Hepatitis C	10,18-20
Hepatitis C seropositive donors	10
High risk for HIV	10
HIV	7,8,10,11,16,18,19,20,22
HIV screening.....	18
HTLV-I.....	10,18
HTLV-II	10,18
Human pituitary-derived growth hormone.....	10
Human tissue	8
In situ.....	13-15
Infection	7,10-12,16-17
Infection control	7
Infusion	17
Inspection	1-3,6,16,20,23
Instruments and reagents	6
Intravenous	10
Intrinsic eye disease	9
Iritis	9,12
Jaundice	12,15
Karposi's Sarcoma	11
Keratoconus	9
Keratoglobus.....	9
Labe	19,21,22
Labeling	19
Laboratory	1,4-6,11-17,19-22
Lamellar	9,12,14
Laser photoablation	9
Laser surgical procedure.....	10
Laser trabeculoplasty	10
Leukemias.....	10
Living donors	13
Maintenance	5,6,13
Malignant tumors	9

Medical Advisory Board	3,14,16,20,22,24
Medical Director	2-4,7-10,13-17,19,20
Medical examine.....	8,13,21
Medical history	13,20,21,23
Medical record	8,11,12
Monitoring	6,16
National Sanitation Foundation (NSF) Standards	14
Non-Required laboratory results	8
OSHA	7
Package insert	21,22
Packing	22
Penetrating keratoplasty.....	1,9,10,12
Personnel	2-5,7,8,14
pH	20
Plasma volume	17
Preservation	12-15,18-21,23
Presurgical cultures.....	17
Procedures Manual.....	6,7,10,13-15
Procurement	1,3,4,13,14
Progressive multifocal leukoencephalopathy	9
Provisional member	1,2
Pterygia.....	9
Quality assurance.....	3,7,16
Quality control.....	2,16
Quarantined tissue	6
Rabies	8,9
Radial keratotomy.....	9
Refractive corneal procedures	9
Refrigerator.....	6
Retinitis.....	9
Retinoblastoma	9
Returned tissue	20
Reyes Syndrome	9
Safety	5,7,16
Satellite laboratories	7
Sclera.....	12,14-17,19-21,24
Scleritis	9
Sclerosing panencephalitis	9
Screening.....	11,12,18,19,21-23
Seal	21,22
Septicemia.....	9
Serologic tests (testing)	8,17,19,22
Slit lamp.....	15,16,21,23

Specific Exclusionary Criteria	11
Specular microscopy	10,15,21,23
State laws	16
Stromal pathology.....	15
Surgical culturing	17
Syphilis	11,16,18
Technical staff	3-5
Time intervals	13
Tissue Recall	19,21
Training	3-5,8,10,23
Transfusion	17
Transplantation	1,4,13,15-23
Transplanting surgeon	15,20
Transport	19,20,22,23
Universal Precautions	7
Uveitis	9
Warranty	22
Waste disposal	7-8


Commercially Available Storage Media



In rabbit corneas, when stored in CM for 7 or 11 days and then grafted, endothelial cell density still retained 91% in 12 weeks post graft. (The 9% changes are statistically insignificant).



In contrast, when stored in other leading storage media for 7 and 11 days, the endothelium exhibited significant cell losses, and only about 73% and 69%, respectively, remained in 12 weeks post graft.



REFERENCES

1. Chen et al. *Transplantation* 57: 1778, 1994.
2. Chen et al. *Transplantation* In Press, 1997.
3. Chen et al. *Cornea* 15: 35, 1996.
4. Chen et al. *EBAA Presentation*, 1996.
5. Sulewski et al. *Invert Ophthalmol Vis Sci* 37 (abst), S85, 1996.
6. Toeng et al. *Invert Ophthalmol Vis Sci* 37 (abst), S85, 1996.
7. Sulewski et al. *EBAA Presentation*, 1996.
8. Ellis et al. *Cornea* 11: 127, 1992.
9. Fajst et al. *Cornea* 3: 159, 1989.
10. Bourne WM. *Am J Ophthalmol* 102: 382, 1986.

CHEN LABORATORIES

Phoenix, MD, 21131
(410) 628-2756, Fax (410) 667-4439

CHEN MEDIUM

For Corneal Storage



DESCRIPTION

Chen Medium (CM) is a unique cornea storage medium that effectively improves epithelium and endothelium integrity, and yields thin and clear grafts promptly after surgery. Successful grafts have been observed in corneas stored in CM for up to 14 days.

CM has several unique features:

- physiologic conditions
- excellent source of nutrients
- prevention of acid and metabolic waste accumulations in cells
- built-in bicarbonate generation system for pH stability
- low salt environment

These features enable the corneas to maintain active metabolic and physiologic functions, retaining their capabilities for cell growth and repair. Thereby, CM enhances epithelial and endothelial survival and sustains donor cornea viability during storage.

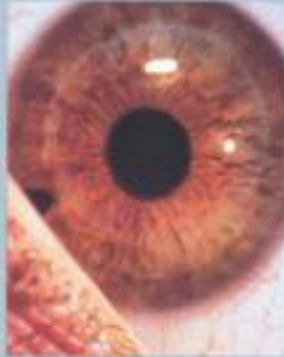The combination of improved tissue barrier integrity, sustained metabolic function, and low salt environment enables corneas to maintain normal thickness during storage. This is distinctly different from other media which artificially maintain cornea thinness through extracellular colloidal pressure generated by hypertonicity and osmotic agents.

CM also contains gentamicin and streptomycin sulfate for antibiotic coverage.

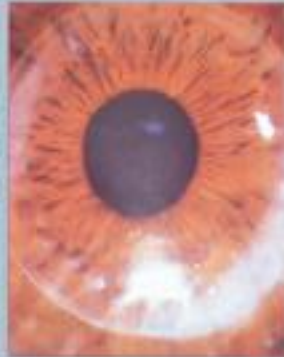CLINICAL AND EXPERIMENTAL FINDINGS

Transplantation of CM-stored donor corneas, including those with extended death-to-preservation times leads to:

- (1) Clear grafts promptly after surgery
- (2) Excellent graft quality, as illustrated in this 2-year post-op photograph of a recipient of CM-stored donor cornea.



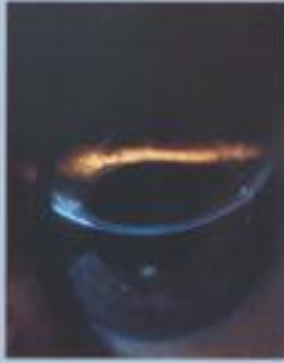A 2-year post-op photograph of another graft using the same cornea stored in the leading storage media is shown here for comparison.



- (3) A well-preserved endothelium with a dense and homogeneous cell population, as depicted in this 9-week post-op specular photograph.



- (4) Thin and clear corneas with well-preserved endothelium and epithelium, as shown in this 2-month post-op slit-lamp photograph.



CM has a remarkable effectiveness for preserving the endothelium of donor corneas. After 11 days of human donor cornea storage, the cornea stored in CM (see scanning electron micrograph A, below) exhibited 91% corneal endothelial integrity, versus only 58% in the mate cornea stored in other leading storage media (B). Under the latter conditions, endothelial cell degeneration reportedly began in only 3 days.



CHEN MEDIUM

β -Hydroxybutyrate-Enriched Iso-osmolar Medium For Corneal Storage

Description:

Chen Medium (CM) is a low salt, β -hydroxybutyrate-enriched iso-osmolar tissue culture medium with dextran to adjust the osmolality. CM is supplemented with 100 μ g/ml gentamicin and 200 μ g/ml ceftioxylin sulfate. It has phosphate and HEPES buffers, with a very stable pH in the range of 7.2 - 7.5. Phenol red is used as a pH indicator.

CM is for storage of human donor corneas suitable for transplantation for up to 14 days at 2° - 8°C, depending on tissue quality at the time of excision. It supports corneal tissue's metabolic and physiologic functions *in vitro*.¹ It has potential to enable the cornea to generate a high level of ATP, and adequate HCO₃⁻ for performing physiologic function during storage without added bicarbonate, resembling a built-in HCO₃⁻ generating system.^{1,2}

The iso-osmolality as a safety feature in the corneal storage media design. Namely, degeneration of corneal cells is an inevitable event following extended storage under serum-free conditions,³ with onset varying with donor tissues and storage media. When endothelial dysfunction occurs, the iso-osmolality of the media allows the cornea to swell, permitting the surgeon a firm check of corneal viability prior to transplantation.

Indications:

CM is used to store donor corneas at 4°C (range: 2° - 8°C) to help sustain tissue viability while tests of donor blood samples and evaluation of corneal quality are performed. Once serologic assessment and corneal quality are assured, donor corneas are shipped to hospitals for grafting.

Precautions:

The donor eye should be disinfected prior to excision of the cornea. Sterile techniques should be applied in the corneal procurement process, and the penetrating keratoplasty procedure. Prior to use, the vial should be inspected visually. The solution should be an orange-red color. A change of color from orange-red to yellow would indicate a possible microbial contamination. The pH of the solution may rise to alkaline (red color at pH 8.4) if tampering has occurred. If the solution appears cloudy and/or changes color, do not use, and return the affected vial to the manufacturer for evaluation and replacement. Condensation may occur on the inside wall. If this occurs, the media should be mixed well before use.

Storage:

CM should be kept in a refrigerator at 2° - 8°C until uses. Do not store at 0°C or below, since salts in the media may crystallize at these temperatures.

Instruction for Use

For in vitro process of corneal storage:

1. Break the seal and place the corneal description label on the vial
2. In a sterile biological safety hood with laminar air flow, loosen and tilt the cap, and place it to the side with the inner liner facing up.

3. Aseptically transfer the cornea to the vial. Make sure the cornea is submerged in the medium with the epithelium facing down. Avoid spilling the fluid into the container duct.
4. Replace and tighten the cap. Place the protective shrink seal around cap interface.
5. Store at 2° - 8°C.

For in situ process of corneal storage:

1. Refer to E1 200 of the EBAA manual for standardized method of aseptic *in situ* cornea excision.
2. Loosen the cap to the top thread of the vial.
3. Disinfect the donor eye and excise the cornea.
4. Aseptically remove the tissue.
5. Lift the cap slightly up above the vial.
6. Follow steps # 3, 4, and 5 of the *in vitro* process to aseptically transfer and store the cornea.

For retrieval of donor cornea:

1. Inspect the seal of the vial and quality of the donor cornea.
2. Record information regarding the donor cornea in the patient's chart.
3. Bring the vial containing the donor cornea to the operating room.
4. Immediately prior to transplantation, break the seal, and loosen and lift the cap.
5. Carefully and gently pour the donor cornea along with the storage medium into a sterile container.
6. Retrieve the cornea with a pair of forceps by holding on the edge of scleral rim. Transfer the tissue to a teflon cutting block with the epithelium facing down.

Caution:

The device is for single use only. Federal Law (USA) restricts this device to sale by or the order of a licensed physician.

How supplied:

Chen Medium is available in 15 ml. and 20 ml. glass vials packaged in boxes of 12.

Patents:

US 5654266; Australia 653586; Taiwan 081808; Europe patent granted; Japan patent granted.

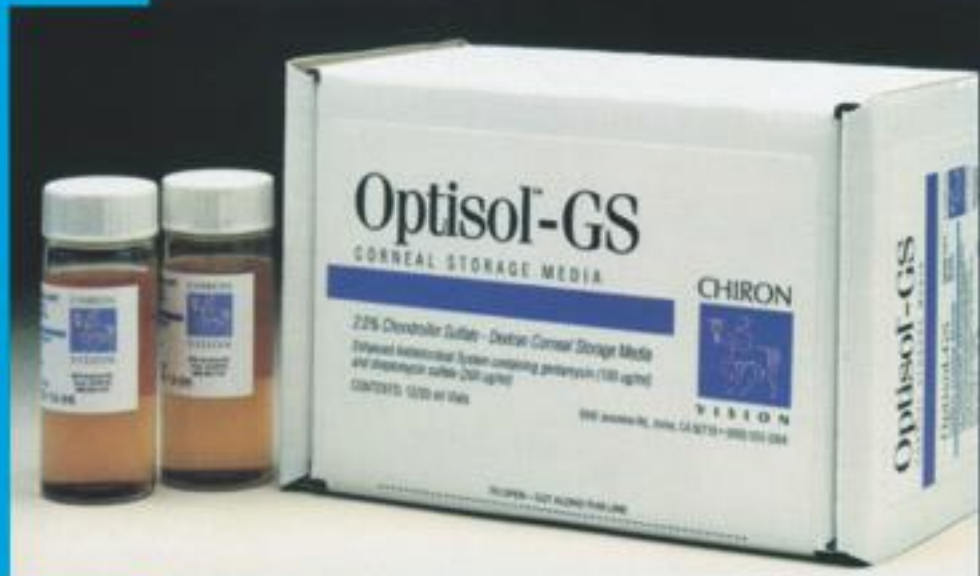References:

1. Chen et al. *Transplantation* **57**, 1778 (1994).
2. Chen et al. *Transplantation* **63**, 656 (1997).
3. Chen et al. *Transplantation* **67**, 800 (1999).
4. Chen et al. *Cornea* **15** (1996).

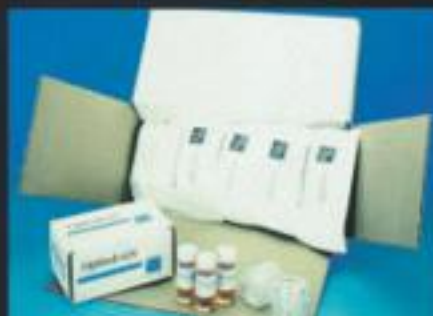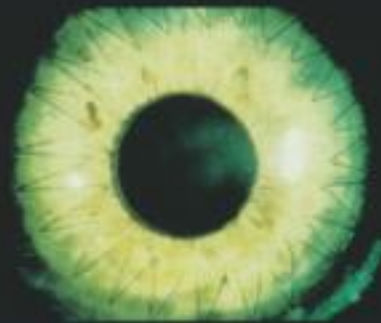Chen Laboratories, 13704 Kallarmey Court, Phoenix, Maryland 21131, USA
(410) 628-2726; Fax (410) 667-4439.

Optisol-GS

The Proven Corneal Storage Media



- *Gentamicin and Streptomycin reduce risk of endophthalmitis*
- *Less stromal edema, fewer Descemet's folds*
- *Enhanced endothelial cell preservation*
- *Reduced epithelial cell edema*
- *Reduced corneal autolysis during storage*
- *Minimal rebound swelling*



Optisol-GS

Chondroitin Sulfate/Dextran Enhanced Antimicrobial System Corneal Storage Media

Description

Optisol-GS is a sterile, buffered tissue culture media.

Component	Effect
Base Medium: Hybrid medium: MEM & TC199 & Earle's balanced salt solution	Provides basic nutrients for cell maintenance
Buffer: HEPES; bicarbonate	Maintains pH
Antibiotic: Gentamicin & Streptomycin	Prevent infection by gram +/- bacteria
Glycosaminoglycan: Chondroitin sulfate	Maintains endothelial cell integrity and acts as osmotic agent
Deturgescent: Dextran	Prevents swelling providing suitable corneal thickness for suturing
ATP precursors	Provide energy for pumping function
Antioxidants	Neutralize metabolic waste; maintain DNA synthesis
Vitamins	Provide additional nutritional cell supplements
Color: Phenol red	Visual aid for pH indication

Note: Medium is serum free and does not contain any bovine originating components

Indications

Optisol-GS is a 4°C corneal preservation medium. It permits up to 14 days preservation.

Packaging

Optisol-GS is available in boxes of 12 glass vials of 20mL each.

Storage

Optisol-GS should be stored at 2-8°C (not below 0°C) until ready for use. Shelf-life at 4°C is 2 years.

Specifications

Regarding osmolality and pH value, Optisol-GS corresponds to the conditions of the human cornea in situ:

Specification	Range
pH	7.0-7.5
Osmolality	295-355 mOsm/kg

pH color indicator shows the permissible range of pH value:

pH Color Reference Chart



NOTE: Above colors are not exact, samples only.

Expanding Capabilities of Optisol-GS

Optisol-GS combines all the advantages of Optisol with the antibiotic combination, Gentamicin plus Streptomycin. This Optisol-GS formulation was created to further reduce the risk for endophthalmitis caused by the most common streptococci or staphylococci contaminants. Optisol-GS showed superior spectrum activity against susceptible gram positive and gram negative organisms.

Optisol-GS has demonstrated the capacity to maintain a 97% activity level against 10 different organisms even after 12 months storage time. The combination gentamicin/streptomycin demonstrated greater inhibitory activity than other antibiotic combinations, including vancomycin/gentamicin, gentamicin/penicillin, and penicillin/streptomycin, in preclinical studies, see Fig. 1.

In a comprehensive toxicity trial, SEM and TEM studies of paired human corneas following 5 days of storage in Optisol-GS showed no toxicity. 3H-thymidine incorporation studies demonstrated that the addition of Streptomycin in the effective antibiotic range of 200-1000g/mL does not reduce the ability of the endothelial cells to synthesize DNA.

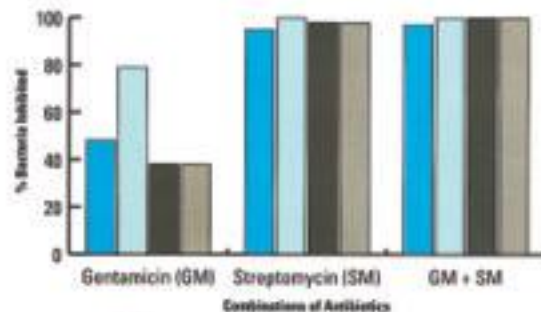


Figure 1: Gentamicin Resistance Study Inhibitory Activity with Combination of Antibiotics

Antibiotic Stability Study	
Storage time at 4°C	Activity remaining
2 weeks	98%
6 months	97%
12 months	97%

Bausch & Lomb Surgical's Proven Antibiotic Combination Corneal Storage Media

Clinical Trial

Double-masked randomized multicenter clinical trials were conducted by Drs. A. Sugar, R.F. Meyer, and K. Soong of the University of Michigan, by Dr. J. Gordon, Chiron Vision, by Drs. J.H. Lass and W.J. Rainhart of Case Western Reserve University, by Drs. W. Bourne and L. Maguire of the Mayo Clinic, and Dr. R.A. Norden of the Lions Eye Bank of New Jersey, to compare Optisol® and Dexsol® and to study Optisol-GS. In this study, 31 paired corneas were transplanted into 62 patients matched by diagnosis and indication for penetrating keratoplasty intraoperatively. Optisol-stored corneas were significantly thinner than Dexsol-stored corneas after both cardinal suture placement (CSP: 0.64mm vs. 0.76mm; $p=0.001$) and at the end of surgery (ES: 0.69mm vs. 0.78mm; $p=0.002$); see Fig. 2. In addition, Optisol provided excellent endothelial cell preservation post-operatively at one year. Optisol more effectively reduced corneal autolysis during 4°C storage.

Optisol has been demonstrated to markedly reduce storage-induced corneal swelling. Sustained corneal deturgescence during and after preservation are of great clinical importance, providing tissue that can be more readily evaluated by slit lamp and specular microscopy, and more easily handled intraoperatively by the surgeon.

Mean Percent Endothelial Cell Loss				
Postop	N	Optisol	Dexsol	p Value
3 months	22	3.6 ± 15.7	4.2 ± 12.5	0.87
6 months	20	12.4 ± 19.6	10.4 ± 15.1	0.64
12 months	26	15.3 ± 24.9	21.3 ± 23.0	0.22

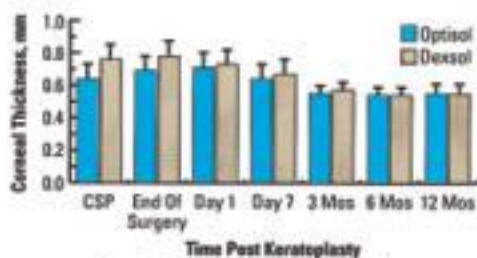


Figure 2: Corneal Thickness Evaluation

Optisol	
Time	mm (SD)
CSP	0.64 ± 0.09
ES	0.69 ± 0.09
1 day	0.71 ± 0.09
7 days	0.64 ± 0.09
3 months	0.55 ± 0.05
6 months	0.54 ± 0.05
12 months	0.55 ± 0.06

Performance Summary

- Less stromal edema, and fewer Descemet's folds allowing quicker evaluation and reducing endothelial cell lysis on Descemet's folds.
- Better tissue quality during storage, with potential for improved tissue ratings.
- Enhanced endothelial cell preservation.
- Reduced epithelial cell edema, suggesting better cell adhesion and viability.
- Reduced corneal autolysis during storage.
- Easier handling of tissue during surgery.
- Minimal rebound swelling.

The antibiotic combination, Gentamicin plus Streptomycin, is formulated to greatly reduce the occurrence of endophthalmitis, which is caused by the most common Streptococci or Staphylococci contaminants.

In an antimicrobial efficacy study, multiple 20mL samples of Optisol-GS were inoculated with 0.1mL of eight different strains of microbial suspensions and incubated at room temperature. The results of challenge on day 0 and re-challenge on day 7 are shown in Fig. 3.

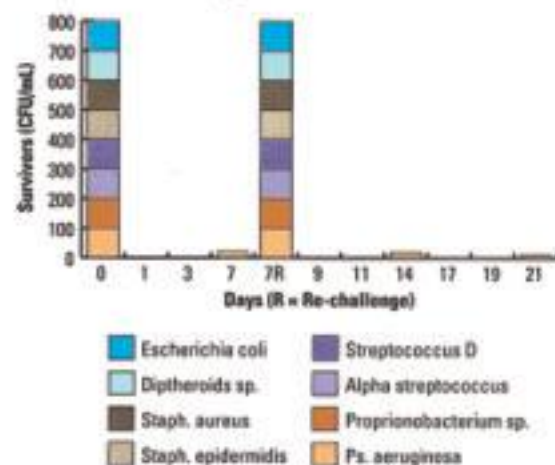


Figure 3: USP Antimicrobial Study

References

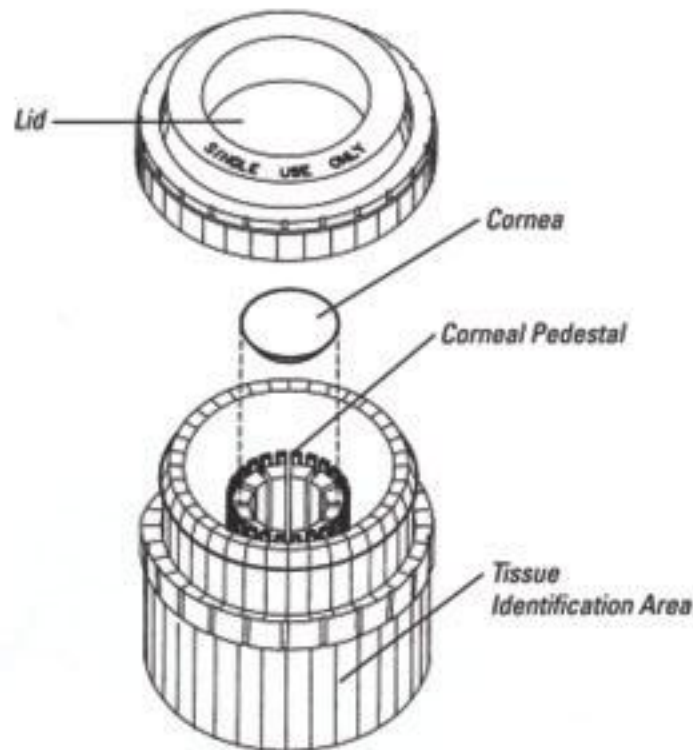
Optisol Corneal Storage Medium, Leithorn, R.L., Kaufman, H.E., Steinhilber, D.L., Luong, R.A., Lanz, J.H., Musch, D.C., Trousdale, M.D., Reinhart, W.J., Soong, T.E., Sugar, A., Davis, S.M., Hrochova, K., Smith, T.M., and Gordon, J.F. *American Journal of Ophthalmology* 114(2):348-356, September 1992

Combination Antibiotic Supplementation of Corneal Storage Media, Huang, S.G., Nakamura, T., Trousdale, M.D., and Smith, T.M. *American Journal of Ophthalmology* 115:299-308, March 1993

Efficacy and Safety of Gentamicin and Streptomycin in Optisol-GS, a Preservation Medium for Donor Corneas, Smith, T.M., Poppelwell, J., Nakamura, T., and Trousdale, M.D. *Cornea* 16(1):49-55, 1995

Note: Smith, T.M. is an employee of Bausch & Lomb Surgical, who owns above referenced studies.

Corneal Viewing Chamber



The Corneal Viewing Chamber is a sterilized single-use storage device designed especially to reduce the possibility of tissue damage and contamination, and facilitate slit lamp and specular microscopic examination of the epithelium and endothelium.

The clear viewing chamber permits easy anterior and posterior visualization of the whole cornea, and the large anterior viewing window design permits wider slit lamp swing.

The single transfer/single use design of the chamber eliminates the potential for ETO contamination of resterilized alternative viewing chambers, and reduces the possibility of tissue damage and processing contamination.

Designed and engineered in conjunction with the Eye Bank Association of America (EBAA) and Tissue Banks International (TBI), the Corneal Viewing Chamber is manufactured of durable, 100% biocompatible PMMA, to minimize potential breakage. It's stable, stackable, low profile design reduces tipping and increases storage convenience.

Packaging: The product is available in boxes of 12 viewing chambers each. Shelf-life is 1 year.

*Trademark of Bausch & Lomb Incorporated.
© Copyright 1998 Bausch & Lomb Incorporated. All rights reserved. 57098

**BAUSCH
& LOMB**
Surgical

Bausch & Lomb Surgical
Claremont, California 91711 USA
Telephone: 909-624-2020
Customer Service: 800-843-1137
FAX: 909-399-1425

Optisol™ -GS

Chondroitin Sulfate/Dextran Corneal Storage Media Enhanced Antimicrobial
Catalog No. 50006-OPT

Description

OPTISOL-GS is a sterile, buffered tissue culture media which is enhanced with polypeptides, an osmotic agent (dextran), chondroitin sulfate, gentamicin sulfate, streptomycin, and phenol red indicator.

Indications

OPTISOL-GS is a biocompatible, enhanced tissue culture media for storage of human corneas suitable for keratoplasty for up to 14 days under refrigeration (2-8°C).

Precautions

Sterile technique should be used throughout the keratoplasty procedure.

Each vial of media should be visually inspected for color prior to use. The medium should be a light rosy-orange color. A change of color from rosy-orange to yellow indicates a pH shift, possibly due to bacterial contamination. A color change from rosy-orange to red indicates an unacceptable pH shift. Do not use media that appears cloudy. In the event of such change, return the unopened vial to Bausch & Lomb Surgical for evaluation and replacement.

Storage

OPTISOL-GS should be stored between 2-8°C until ready for use. DO NOT FREEZE.

Caution

Federal (USA) law restricts this device to sale by, or on the order of, a physician.

Instructions For Use

Label the vial with a description of the cornea. Break the seal of the cap. Proceed as follows.

Aseptic conditions:

1. Loosen cap of the vial.
2. Lift off the cap and place adjacent to sterile field with inner liner face up.
3. Aseptically transfer cornea. Make sure cornea is submerged in liquid.
4. Replace and tighten container cap. Do not overtighten. To assure seal integrity, avoid spilling the media into the thread area of the container cap.
5. Place appropriate labeling on vial and place heat seal around cap interface.
6. Store cornea at 2-8°C.

In situ:

1. Loosen vial cap to top thread. Do not remove cap until immediately before transfer of the cornea to the storage media.
2. Aseptically remove cap. Transfer the cornea to storage media as in steps #3, 4, and 5 above.
3. Refer to E.200 for standardized method of aseptic in situ removal according to the EBAA manual.

How Supplied

OPTISOL-GS is available in 20 mL glass vials packaged in boxes of 12.

BAUSCH & LOMB Surgical
Bausch & Lomb Surgical, Inc.
Irvine, CA 92618-1903 USA
(800) 338-2020
(809) 824-2020

U.S. patent no. 5,104,787 Foreign patents pending. ™ Trademark of Bausch & Lomb Surgical, Inc.
© Copyright 1999 Bausch & Lomb Surgical, Inc. All rights reserved.

INDEX

- Adhesions61
Aebli52, 60
Alligator.....34
Anterior capsule135
Anterior chamber angle135
Anterior chamber.....14, 135
Aqueous humor135
Arcuate keratotomy74
Arcus senilis74, 135
Arcus135
Astigmatism.....135
Bilirubin.....137
Biomicroscopy44
Blunt tip scissors19
Bowman's.....135
Bowman's layer45
Bruch's membrane135
Cage39
Canthus135
Canthus135
Caruncle.....135
Castroviejo.....52, 60
Cataract wound74
Cataract135
Cell densities85
choroid.....49, 54, 61, 135
Cilia135
Ciliary body.....49, 135, 139
Ciliary sulcus.....137
Clamps20
Clean22
Confluent77
Conjunctiva72, 135
Contact lens wear111
Contaminated.....22
Cornea136
Corneal caps43
Corneal endothelium45
Corneal Excision47
Corneal Folds Grading Atlas97
Corneal section scissors19
Corneal storage and viewing chambers
(CSVC's)22
Corneo-scleral rim excision49
Corneo-scleral rim.....21
Cortex138
Cortical spokes135
Cross Sectional Anatomy of the Globe13
CSVC.....135
Dependent edema27
Descemet's detachment77
Descemet's membrane77, 136
Descemet's.....2, 45, 71
Descemet's fold136
Direct illumination67
Donor Maintenance25
Donor Preparation130
Donor Rim with Iris121
Donor with Lens Implant and Iris122
Dry ice27
Edema72
Endothelial cells77, 90
Endothelial striae136
Endothelium71, 77, 136
Enucleation scissors19, 33, 34, 41
Enucleation spoon21, 136
Enucleation19, 28, 33, 43, 136
Epithelial Defect and Exposure.....116
Epithelial Defect114, 136
Epithelial defects72
Epithelial Sloughing126
epithelium71, 136
Equator135
Evisceration spoon19
Evisceration136
Excision19, 136
Excrescences90
Exposure Keratopathy115
Exposure72
External Ocular Anatomy13
External22
Eye Bank Specular Microscopes.....91
Eye jars39
Fascia34
Fixed frame analysis92
Folds73
Forceps.....19, 136
Foreign material.....72
Fornix.....136
Fuchs' endothelial dystrophy.....77
Gross Anatomy of the Eye and Orbit12
Gunpowder127
Guttae45, 77, 90, 109, 137
Haptics137
Hemorrhage72
Hemostats20
Hyperopia137
Icterus/jaundice72, 137
Ide beam69
Infant Cornea.....120
Inferior rectus38
Infiltrate.....72, 73, 137
In-situ.....49, 137
Internal.....22
IOL (intraocular lens implant).....137
Iridectomies72
Iris radial muscles137
Iris sphincter137
Iris137
Isolated77
Jaundice137
Joystick67
Keratic precipitate (KP)77, 137
Keratocyte137
Keratomileusis (LASIK, ALK)74
Keratoplasty.....74, 137

KP	79	Rectus muscle	38, 140
Laboratory Corneal Excision	52	Rectus	22
Lamellar keratectomy	138	Retina.....	140
Lamellar keratomileusis	137	Retroillumination.....	67
Laminar-flow hood	138	Ring scissors	140
Lateral canthus	138	Ring-end handles	19
Lateral rectus	33	Rosette	94, 140
Lens	138	Scalpel blades	19
Lid Speculum	63	Scar	74, 140
Lid	138	Scissors	19
Limbus.....	33, 49, 61, 138	Sclerotic scatter	67
Lysed cells	109	Semilunar fold	140
Media.....	79	Serrated forceps.....	19
Medial canthus	138	Severe folds	74
Meibomian gland orifices	138	Slit lamp	67
Microbicidal	60	Sloughing.....	72
Microscopic Anatomy	15	Smooth forceps	19
Mild folds	74	Snail Tracks.....	77, 117, 119, 140
Moderate folds.....	74	Specular microscope	22, 85
Mosaic	91	Specular Microscopy.....	83, 91
Mucocutaneous junction	138	Specular reflection	67, 77, 85, 140
Muscle hook	20, 138	Specular	45
Myopia.....	138	Speculum.....	19, 140
Neo-scleral rim	23	Spring handle scissors	19, 140
Normal Cell Morphology	93	Stress line (endothelial striae)	77, 109, 140
Normal endothelium.....	107	Stress Striae	118
Nuclear sclerosis	135	Striae	45, 73, 74, 77, 140
Nucleus	138	Stroma	71, 73, 136, 140
Oblique muscles	34, 138	Subcapsular cataract	135
Optic nerve	39	Suprachoroidal space.....	61
Optic	137	Surgical Incisions	72
Optical section	67	Sutures	74
Orbital Anatomy	14	Suturing Technique	130
Parallelepiped	67	Tangential	67
Parfocal	67	Tarsus.....	140
Pars plana	135, 139	Tenon's fascia.....	140
Penetrating Keratoplasty	127, 139	Tenon's.....	19, 33
Perforation of the choroid	54	Tenotomy scissors	54
Peritomy.....	54, 61	Tenotomy	60
Perpendicular	67	Toothed forceps	19
Photorefractive keratectomy	139	Townley Paton	2
Phototherapeutic keratectomy	139	Trabecular meshwork	135, 140
Pinguecula	72, 139	Trace folds.....	74
Planimetry	93	Trauma.....	72, 74
Pleomorphism	45, 89, 94, 107, 111, 139	Trephine.....	20, 140
Polymegathism	45, 89, 94, 107, 109, 111, 139	Trocar buttons	39
Posterior capsule	139	Trochlea	138
Posterior chamber	139	Uvea (ciliary body-choroid)	62, 140
Povidine-iodine	60	Variable frame analysis	92, 93
Pre-corneal tear film	139	Vitreous leakage	54
PRK (photorefractive keratectomy).....	74	Wet ice	27
Pseudoguttae.....	2,77, 139	Whole Globe Exam	41
Pterygia	74	Xonules	140
Pterygium	72, 119, 124, 139		
Pterygiums.....	72		
Puncta	139		
Puncture Wound.....	125		
Pupil.....	139		
Radial keratotomy	74, 123, 139		
Recipient Preparation	130		

Printed by

PRO*forma*[®]
Print and Promotional Product
Solutions for Eye and Tissue Banks

(608) 644-8811

Designed by


WATERFRONT
Graphic Design, LLC
(608) 592-6501